

# Lost and found anatomical terms: crista choanalis vomeris

---

Marušić, Ana; Vinter, Ivan; Krmpotić-Nemanić, Jelena

Source / Izvornik: **Annals of anatomy = Anatomischer Anzeiger, 2006, 188, 281 - 283**

Journal article, Accepted version

Rad u časopisu, Završna verzija rukopisa prihvaćena za objavljivanje (postprint)

<https://doi.org/10.1016/j.aanat.2006.01.010>

Permanent link / Trajna poveznica: <https://um.nsk.hr/um:nbn:hr:105:090461>

Rights / Prava: [In copyright](#) / [Zaštićeno autorskim pravom.](#)

Download date / Datum preuzimanja: **2024-07-04**



Repository / Repozitorij:

[Dr Med - University of Zagreb School of Medicine  
Digital Repository](#)





### **Središnja medicinska knjižnica**

Marušić, A., Vinter, I., Krmpotić-Nemanić, J. (2006) *Lost and found anatomical terms: crista choanalis vomeris*. *Annals of anatomy = Anatomischer Anzeiger*, 188 (3). pp. 281-283.

<http://www.sciencedirect.com/science/journal/09409602>

<http://medlib.mef.hr/124/>

University of Zagreb Medical School Repository

<http://medlib.mef.hr/>

## Lost and found anatomical terms: *crista choanalis vomeris*

Ana Marušić, Ivan Vinter, Jelena Krmpotić-Nemanić

Department of Anatomy, Zagreb University School of Medicine, Šalata 11, HR-10000  
Zagreb, Croatia

### Summary:

*Pars cuneiformis vomeris* and *crista choanalis* are morphological structures on the vomer listed in the current official anatomical nomenclature, *Terminologia anatomica*, but are either not mentioned or incorrectly described in different anatomical books. The term *crista choanalis vomeris* was originally proposed by Drago Perović in 1958 to describe the vertical crest beginning at the angle of the alae vomeris, running downwards to the posterior free margin of the vomer. Perović also described the part of the vomer behind this crest was shaped as a cone, and termed it *pars cuneiformis vomeris*. Because of their important contributions to the function of the respiratory pathway, *crista choanalis vomeris* and *pars cuneiformis vomeris* deserve proper definitions in the anatomical terminology.

Building up anatomical terminology is a continuous process. After the editions of the *Nomina anatomica* from Basel in 1895, Jena in 1935 and Paris in 1955, the newest *Terminologia anatomica* (Federative Committee on Anatomical Terminology, 1998) superseded all previous terminology listings. *Terminologia anatomica* was created jointly by the Federative Committee on Anatomical Terminology (FCAT) and Member Associations of the International Federation of Associations of Anatomists (IFAA), with the aim to adapt the listing of anatomical terms to the variations of terminology usage in different medical communities around the world.

We have previously pointed out several mistakes and omissions in the *Terminologia* (Krmpotić-Nemanić and Vinter, 2003a; 2003b). We now report on the mistakes in the anatomical description of the vomer. The *Terminologia* describes four morphological

structures on the vomer: *ala vomeris*, *sulcus vomeris*, *pars cuneiformis vomeris* and *crista choanalis vomeris*. While the reference of the first two terms to the structures is clear, *crista choanalis vomeris* and *pars cuneiformis vomeris* are differently described in anatomical books. Gray's anatomy (Williams, 1999) does not mention these terms, but describes surfaces of the vomer, and superior, inferior, and anterior and posterior borders. The photographic atlas of Rothen, Yokochi and Lütjen-Drecoll (2002) describes only the *ala vomeris* and the posterior border of the vomer. Feneis and Dauber's Pocket Atlas of Human Anatomy (2000), describes the *crista choanalis vomeris* as the choanal crest of the vomer – „posterior edge of vomer separating the two choanae“. Feneis and Dauber also describe the cuneiform part of the vomer (*pars cuneiformis vomeris*) as the “wedge-shaped part of the vomer”. The newest edition of the Sobotta atlas (Putz and Pabst, 2006) does not present the morphology of the vomer as a separate bone, but indicates vomer and only *ala vomeris* on figures of the nasal cavity. However, the previous edition of the atlas (Putz and Pabst, 2000) presented two figures of the vomer, with *crista choanalis vomeris* defined as the posterior border of the vomer.

The definitions of both the *crista choanalis vomeris* and *pars cuneiformis vomeris* in current editions of anatomical atlases are incorrect because they do not relate to the original description of the structures. The term *crista choanalis vomeris* was originally proposed by Drago Perović (1958), as the vertical crest beginning at the angle of the *ala vomeris*, running downwards to the posterior free margin of the vomer (**Figure 1**). The part of the vomer behind this crest was shaped as a cone, and was termed *pars cuneiformis vomeris* (**Figure 1**). Perović (1958) showed that *crista choanalis vomeris* developed very early and was fully shaped by the end of the first year of life. *Crista choanalis vomeris* and *pars cuneiformis vomeris* are functionally very important anatomical formations because they limit the medial choanal border and direct the flow of the air through the choanae. Because of the cone-shaped medial borders of the choanae, the air stream does not produce turbulations but silently glides into the nasopharynx. Perović called these structures the „formations of the aerodynamic adaptation“. Both terms can be found in the 3<sup>rd</sup> edition of the *Nomina anatomica* (Subcommittee of the International Anatomical Nomenclature Committee, 1966), but were obviously not correctly interpreted in anatomical texts.

Because of their important contributions to the function of the respiratory pathway, *crista choanalis vomeris* and *pars cuneiformis vomeris* deserve proper definitions in the anatomical terminology. Also, modern *in vivo* functional imaging of the body structures should investigate the contribution of these structures to the flow of the air through the nasal cavity into the nasopharynx.

## **Literature**

Federative Committee on Anatomical Terminology. Terminologia Anatomica.

International Anatomical Terminology. Thieme, Stuttgart-New York, 1998.

Feines, H., Dauber, W., 2000. Pocket atlas of human anatomy, 4<sup>th</sup> edition. Thieme, Stuttgart-New York, pp.20-21.

Krmpotić-Nemanić J, Vinter I. Incorrect medical terms in terminologia anatomica. Ann. Anat. 2003;185:195-196.

Krmpotić-Nemanić, J., Vinter, I., 2003. Missing and incorrect terms in terminologia anatomica (1998). Ann. Anat. 185, 387-388.

Perović, D., 1958. Über eine eigenartige normale Bildung am menschlichen Vomer sowie über die wahre Umrandung der Choanen, Bd 316. Radovi JAZU, Zagreb. pp5-58.

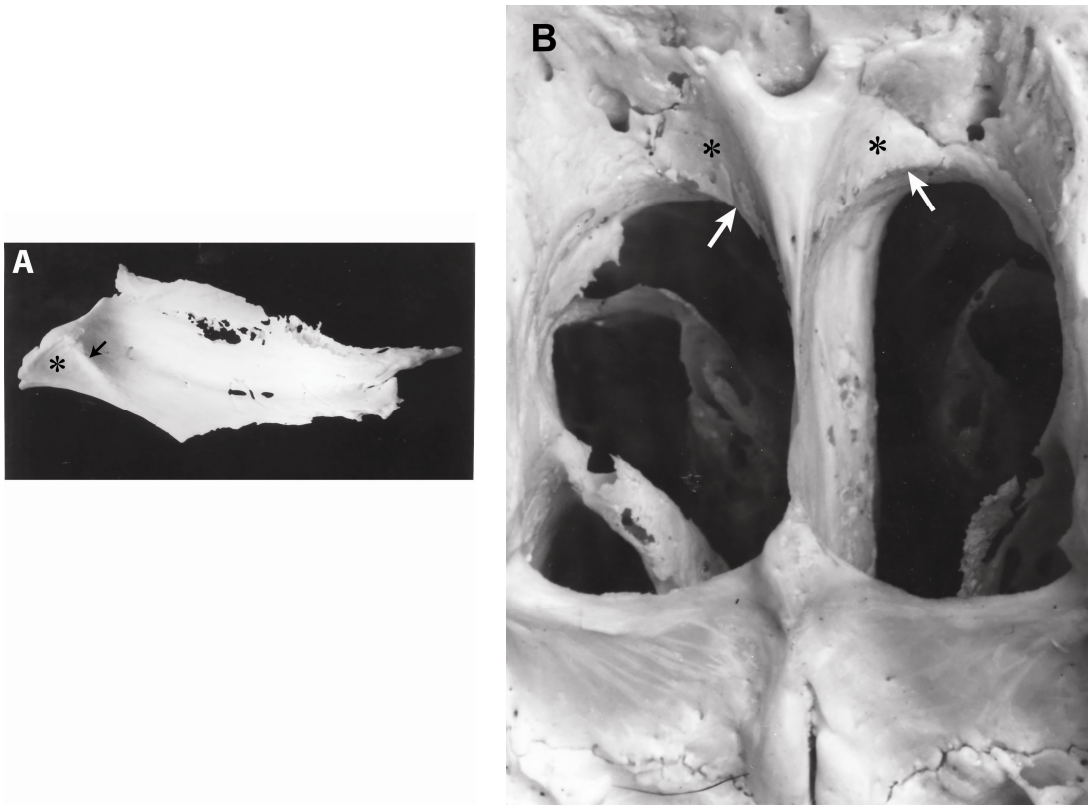
Rohen, J. W., Yokochi, C., Lütjen-Drecoll, E., 2002. Anatomie des Menschen. Fotografischer Atlas der systematischen und topografischen Anatomie. Schattauer, Stuttgart-New York, p. 48.

Putz, R., Pabst, R., 2006. Sobotta Atlas der Anatomie des Menschen, 22<sup>th</sup> ed. Bd. 1. Kopf, Hals, obere Extremität. Elsevier Urban&Fischer, München-Jena.

Putz, R., Pabst, R., 2000. Sobotta Atlas der Anatomie des Menschen, 21<sup>st</sup> ed. Bd. 1. Kopf, Hals, obere Extremität. Urban&Fischer, München-Jena, p. 54.

Subcommittee of the International Anatomical Nomenclature Committee, 1966. Nomina anatomica, 3<sup>rd</sup> edition. Churchill Livingstone, Edinburgh-New York.

Williams, P. L., ed. 1999. Grey's Anatomy. 38<sup>th</sup> ed. Churchill Livingstone, Edinburgh, p 606.



**Figure.** Anatomical features of the posterior end of the vomer. Arrow indicates the *crista choanalis vomeris*, and asterisk the *pars cuneiformis vomeris* on the isolated vomer (A) and the posterior view of the choanae (B).