

Spontaneous perforation of the small intestine, a novel manifestation of classical homocystinuria in an adult with new cystathionine beta-synthetase gene mutations

Muačević-Katanec, Diana; Kekez, Tihomir; Fumić, Ksenija; Barić, Ivo; Merkler, Marijan; Jakić-Razumović, Jasminka; Krznarić, Željko; Zadro, Renata; Katanec, Davor; Reiner, Željko

Source / Izvornik: **Collegium Antropologicum, 2011, 35, 181 - 185**

Journal article, Published version

Rad u časopisu, Objavljena verzija rada (izdavačev PDF)

Permanent link / Trajna poveznica: <https://um.nsk.hr/um:nbn:hr:105:563470>

Rights / Prava: [In copyright](#)/[Zaštićeno autorskim pravom.](#)

Download date / Datum preuzimanja: **2025-01-19**



Repository / Repozitorij:

[Dr Med - University of Zagreb School of Medicine Digital Repository](#)



Spontaneous Perforation of the Small Intestine, a Novel Manifestation of Classical Homocystinuria in an Adult with New Cystathionine β -synthetase Gene Mutations

Diana Muačević-Katanec¹, Tihomir Kekez², Ksenija Fumić³, Ivo Barić⁴, Marijan Merkler¹, Jasminka Jakić-Razumović⁵, Željko Krznarić⁶, Renata Zadro³, Davor Katanec⁷ and Željko Reiner¹

¹ University of Zagreb, Zagreb University Hospital Center, Department of Internal Medicine, Division for Metabolic Diseases, Zagreb, Croatia

² University of Zagreb, Zagreb University Hospital Center, Division for Abdominal and Endocrine Surgery, Zagreb, Croatia

³ University of Zagreb, Zagreb University Hospital Center, Department of Laboratory Diagnostics, Zagreb, Croatia

⁴ University of Zagreb, Zagreb University Hospital Center, Department of Pediatrics, Division for Genetics and Metabolism, Zagreb, Croatia

⁵ University of Zagreb, Zagreb University Hospital Center, Department of Pathology, Zagreb, Croatia

⁶ University of Zagreb, Zagreb University Hospital Center, Department of Internal Medicine, Division for Gastroenterology, Zagreb, Croatia

⁷ University of Zagreb, School of Dental Medicine, Zagreb, Croatia

ABSTRACT

The clinical picture of classical homocystinuria is diverse. This is the first report of an adult homocystinuric patient with non-traumatic spontaneous small bowel perforation. A 47-year old man presented with abdominal rebound tenderness, hypotension and tachycardia, anemia, and elevated markers of inflammation. Other routine laboratory tests were normal. Abdominal x-ray showed no free air. An emergency laparotomy revealed jejunal perforation in the left upper quadrant. Histologic specimen showed full-thickness nonspecific inflammation of the intestinal wall with granulocytic infiltration, hemorrhage and necrosis. Tuberculosis, actinomycosis and typhus were histologically and clinically excluded. After excluding all known possible causes of perforation, we presumed a causative relationship between homocystinuria and small bowel perforation. It could be hypothesized that connective tissue weakness in homocystinuria is a result of homocysteine interference with recombinant human fibrillin-1 fragments or cross-linking of collagen through permanent degradation of disulfide bridges and lysine amino acid residues in proteins. DNA analysis showed three detectable mutations in the cystathionine beta-synthetase gene, 1278T:c.833T>C, and two new mutations, V372G:c.1133T>G, and D520G:c.1558A>G in the alternatively spliced exon 15.

Key words: cystathionine beta-synthetase deficiency, spontaneous small bowel perforation

Introduction

Classical homocystinuria is aminoacidopathy first described in humans in 1962. It results from the inability of degradation and a consequent accumulation of homocysteine amino acid in the circulation. Increased plasma/serum and urine concentration of homocysteine can be caused by different hereditary metabolic disorders at the

enzyme and methionine cycle involved co-factor (remethylation or transsulphuration) levels¹. The most frequent among hereditary metabolic disorders leading to classical homocystinuria, an autosomal recessive condition (McKusick 236200), is cystathionine beta-synthetase (CBS; EC 4.2.1.22) enzyme deficiency². Its average prevalence in

the population is estimated at about 1:344 000 of live-born infants, with evidence of wide regional variation^{3,4}.

The clinical picture of classical homocystinuria is diverse. Subluxation of lens and high myopia can usually be found already by the age of ten. Apart from that, various neurologic and mental problems can also be noted, and the majority of homocystinuric patients (80%) develop osteoporosis before the age of 30⁵. Among other clinical symptoms described, the most frequent are deep venous thrombosis, cardiovascular disease, psychomotor retardation, glaucoma, cataract, scoliosis, genua valga, epilepsy, dystonia and macrocytic anemia^{6–10}. Because of high susceptibility to premature arterial and venous thrombosis half of all untreated patients have a vascular event by the age of 30. Thin hair, inguinal hernia, myopathy, hyperinsulinemia, spontaneous pneumothorax, pancreatitis and pseudocysts have also been described sporadically¹¹. The musculoskeletal features and ocular abnormalities often resemble those of Marfan syndrome (McKusick 154700). Plasma homocysteine values in classical homocystinuria most frequently exceed 50 $\mu\text{mol/L}$ (reference range in adults <15 $\mu\text{mol/L}$). In addition, hypermethioninemia, decreased values of cystine and cystathionine, as well as a significant increase in S-adenosylhomocysteine (AdoHcy) are also expected in the plasma. Diagnosis can be confirmed by measuring the catalytic activity of CBS enzyme in the skin fibroblast or stimulated lymphocyte cultures, or by gene analysis. Until now more than 100 different CBS gene mutations have been described¹².

Case Report

A 47-year old patient with a family history of colon cancer (mother), coronary disease and pulmonary embolism (father), was admitted to the Gastroenterology Division for abdominal pain and deep venous thrombosis of the right leg confirmed by Doppler. The patient's clinical status on admission revealed diffuse abdominal pain, swelling and redness of the right upper and lower leg, and a 3×2 cm swelling of the right inguinal lymph node. The results of esophagogastroduodenoscopy, gastroduodenal radiography and upper abdominal ultrasonography were unremarkable. MSCT finding pointed to an infiltrative process of the small intestine mesentery, most probably of inflammatory etiology. Enteroscopy of jejunal mucosa did not reveal any macroscopic changes (villi normal, smooth, shiny and transparent mucous membrane). Biopsy material was taken from the proximal jejunum, revealing a normal mucous membrane. Whole-body and abdominal scintigraphy with antigranulocyte monoclonal antibodies performed 4 and 24 hours after injection of radiopharmaceuticals revealed a ribbon-like pathologic accumulation of activity in the left hemiabdomen at the height of L4 and L5. Such a finding was considered as a possibly active inflammatory process, most probably in the projection of terminal ileum. Because of a persisting dilemma about whether this was a case of a small bowel malignancy or an inflammatory process consistent with the Crohn's disease of the jeju-

num, explorative laparotomy was recommended to which the patient did not consent at that time.

Two weeks later he returned with a severe diffuse abdominal pain. He was not febrile but became hypotensive (80/60 mmHg) and tachycardic. Abdominal examination revealed tenderness with rebound. Besides elevated WBC (17×10^9) and C reactive protein (157mg/L), the routine laboratory tests were normal. Abdominal X-ray showed no free air. CT scan revealed an abscess in the left abdomen. An emergency laparotomy revealed jejunal perforation in the left upper quadrant that was confined with the adjacent colon and omentum. Unlike perforation caused by an ingested foreign body which is small, this perforation affected two thirds of the bowel circumference without any macroscopic signs of Crohn's disease. Resection was performed with primary anastomosis. Histologic specimen showed acute inflammation through the intestinal wall with granulocytes, hemorrhage and necrosis. Inflammatory cells were also found at the surface of the intestinal wall, as well as within the surrounding adipose tissue. Specific tuberculous, actinomycotic and typhoid inflammations were clinically and histologically excluded. There was no evidence of an old or recent injury of the small intestine (Figures 1 and 2). Moreover, perforation was found to occur 60 cm from the Treitz ligament, i.e. proximally to the site identified by the scintigraphy performed using antigranulocyte monoclonal antibodies during his previous hospitalization. Routine laboratory tests for deep venous thrombosis revealed a markedly increased homocysteine level (315 $\mu\text{mol/L}$ – reference value <15). Since all possible known causes of small bowel perforation in this patient had been excluded^{13,14}, a possible association with the increased plasma homocysteine concentration was considered. Subsequent anamnestic data obtained from the patient's father revealed that clinical suspicion of homocystinuria was raised at the age of 6 at the basis of lens subluxation and marfanoid constitution. Clinical findings indicated possible homocystinuria, which was confirmed by increased serum homocysteine level. His parents were not related. In spite of the physician's warnings and recommendations, the patient neither had control check-ups nor received any therapy afterwards.

After the patient recovered from the surgery, further biochemical tests (Table 1) confirmed the diagnosis. CBS gene analysis was performed at the KRAUSLAB, UCD at Fitzsimons, Molecular Genetics Laboratory, University of Colorado Denver. A total of 3 mutations were identified: the B₆ responsive I278T:c.833T>C mutation, which may account for approximately 21% of all CBS-inactivating alleles worldwide, and two new mutations: V372G:c.1133T>G and D520G:c.1558A>G in the alternatively spliced exon 15, whose clinical significance has not yet been clarified. Because of the deep venous thrombosis, a genetic analysis of frequent hereditary factors of thrombophilia was performed. Factor V Leiden R506Q, FII20210A prothrombin gene mutation and PAI-1 4G/5G polymorphism were excluded. Plasminogen-activating inhibitor-I (PAI-I) was 4.1 kU/L, which is considered to be only a slight increase

TABLE 1
LABORATORY FINDINGS FROM THE PATIENT WITH CBS DEFICIENCY, PRIOR TO AND AFTER THE INTRODUCTION OF THERAPY

Metabolites	Reference range	Before therapy	8 weeks after treatment with folic acid + B12 + B6	4 weeks after treatment with folic acid + B12 + B6 + betaine
Total homocysteine ($\mu\text{mol/L}$)	<15	315	164	69
Methionine ($\mu\text{mol/L}$)	15–37	360	68	54
Homocystine ($\mu\text{mol/L}$)	0	75	14	0
AdoMet (nmol/L)	1600–2800	3548	2852	3620
AdoHcy (nmol/L)	70–190	493	520	187
AdoMet/AdoHcy	15–60	7	5	19
Serine ($\mu\text{mol/L}$)	70–165	96	79	102
Cystine ($\mu\text{mol/L}$)	24–54	14	46	53
B12 (pmol/L)	145–637	77	197	377
Folic acid (nmol/L)	7–39	11.4	>45.4	>45.4

AdoMet: S-adenosylmethionine, AdoHcy: S-adenosyl-L-homocysteine

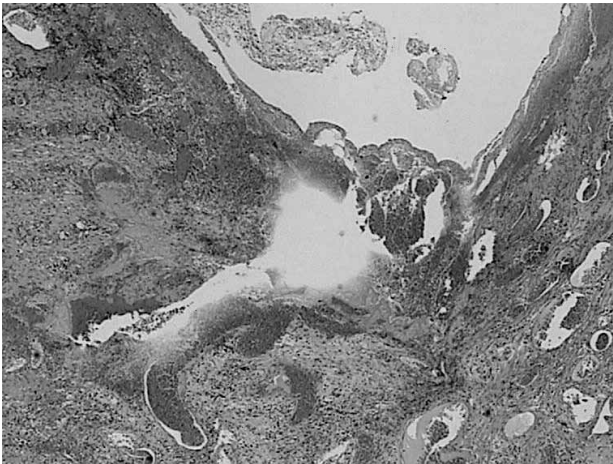

Fig. 1. Necrosis of the intestinal wall with some hemorrhage and inflammation. Hematoxylin-eosin, x200.

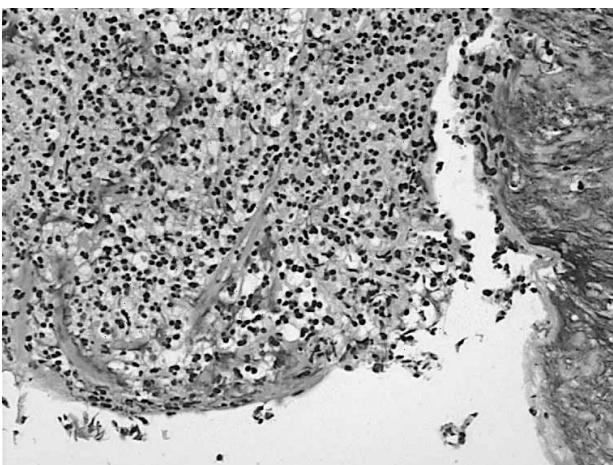


Fig. 2. Detail of necrotic tissue inside the intestinal lumen. Hematoxylin-eosin, x400.

(ref. range 0.3–3.5) and cannot be associated with the development of deep venous thrombosis with certainty.

The repeated abdominal MSCT scan using orally administered contrast four months after the surgery did not show intraabdominal free liquid, localized intraperitoneal collection or enlarged retroperitoneal lymph nodes. The repeated abdominal scintigraphy using autologous Tc-99m HMPAO labeled leukocytes did not detect pathological activity accumulation either on summed images of the dynamic study or on static scintigrams performed up to 20 hours after reinjecting autologous leukocytes. On two occasions at a 3-week interval the patient achieved maximal load in the tenth minute of the treadmill test. Post-load (258 W) finding was normal with no suspicion of coronary pathology. The findings from Doppler ultrasound of the carotid and femoral arteries revealed no changes. These examinations excluded clinically significant atherosclerotic changes of the large arteries. The ophthalmological examination showed bilaterally subluxated lenses. Neurologic status was found to be normal. Mild mental retardation was present. Spine densitometry (L1-L4) suggested osteoporosis (T-value -2.5), while bone mineral density of the femoral neck was normal (T-value was -0.6). Total hip T-score was 0.9.

After having recovered, the patient started to take anticoagulant therapy (warfarin) after initial treatment with low-molecular heparin, 500 mg folic acid in tablet twice a day, two tablets of 50 mg vitamin B₆ three times a day and 1000 μg of B₁₂ per month. As the patient only partially responded to therapy, betaine at a 2 \times 3 g dose was introduced, to which the patient responded very well already after one month even without strict adherence to a low-protein diet. Although patients with classical homocystinuria have frequently been found to have significantly decreased concentrations of plasma serine, which is necessary for conversion of homocysteine to cystathionine, requiring serine therapy, in our patient the serine level was normal (Table 1)¹⁵.

Discussion and Conclusion

Many of the patients with homocystinuria are diagnosed due to vascular events. We are presenting a case of a patient with deep venous thrombosis and spontaneous small bowel perforation. Since all possible known causes of small bowel perforation in this patient were excluded^{13,14}, a possible association with classical homocystinuria was considered. To the best of our knowledge, spontaneous small bowel perforation as a complication of homocystinuria in an adult non-treated patient has not been previously reported. Bass et al. were the first to report a case of spontaneous pneumothorax as a complication of pyridoxine-responsive homocystinuria. The occurrence of spontaneous pneumothorax in patients with Marfan syndrome is common and attributable to pulmonary tissue fragility related to defective fibrillin. Many abnormalities in the connective tissue of patients with homocystinuria resemble those seen in Marfan syndrome caused by mutations in fibrillin-1, a major component of the microfibrils that form a sheath surrounding the amorphous elastin and provide structural support in elastic and nonelastic connective tissue throughout the body¹¹.

Hubmacher et al. have demonstrated that homocysteine in the concentrations found in patients with homocystinuria lead to structural modifications of recombinant human fibrillin-1 fragments and loss of calcium binding¹⁶. They have suggested that degradation of fibrillin-1 in the connective tissues of patients with homocystinuria plays a major role in the pathogenesis of different disorders. However, there is also strong evidence that homocysteine interferes with the cross-linking of collagen. Homocysteine permanently degrades cysteine (disulfide bridges) and lysine amino acid residues in proteins, gradually affecting their function and structure, thus acting as a 'corrosive' of long-living (collagen, elastin) or life-long proteins (fibrillin)^{17–20}. Such a mechanism might be the cause of the connective tissue weak-

ness possibly resulting in spontaneous pneumothorax or small bowel wall perforation, as seen in our patient.

Magner et al.²¹ have observed patients with a milder form of homocystinuria that manifested at adult age, and was diagnosed solely due to vascular events. They have reported mutation c.833T>C (p.I278T), also found in our patient, to be frequent in patients with vascular (6/10 alleles) and connective tissue presentation (8/14 alleles), but non-existent in those with neurological involvement (0/16 alleles). Deep venous thrombosis, previously described connective tissue manifestations (subluxation of lens, myopia, marfanoid features) and lack of neurological symptoms in our patient could also be explained by the same mutation. However, Gaustandess et al. described three CBS deficient sisters aged 58, 56 and 55, with the c.833T>C (p.I278T) mutation, who had repeated vascular events since the third decade of life, but no other clinical features of homocystinuria, including symptoms related to connective tissue weakness, such as subluxation of the ocular lens, genu valgum, pes cavus and long extremities²². In our patient, beside the c.833T>C (p.I278T) mutation, two new mutations, V372G:c.1133T>G, and D520G:c.1558A>G were found in the alternatively spliced exon 15. Although clinical significance of the newly discovered mutations in the CBS gene has not been investigated yet, the expressions studies planned might elucidate their possible influence on different presentations of classical homocystinuria and the response to standard therapy. The observation of spontaneous small bowel perforation in patients with CBS deficiency is very important for two reasons: it adds to the clinical knowledge of complications that can be expected in homocystinuria and may, on the other hand, raise suspicion of classical homocystinuria in patients with spontaneous perforations.

To avoid the development of severe phenotype, probably more related to late diagnosis than the inherited genotype, the importance of early diagnosis based on neonatal screening and early treatment should be underlined.

REFERENCES

- MUDD SH, LEVY HL, SKOVBY F, Disorders of transsulfuration. In: SCRIVER CR, BEAUDET AL, SLY WS, VALLE D (Eds) The metabolic and molecular bases of inherited disease. 7th ed. (McGraw-Hill, New York, 1995). — 2. MCKUSICK VA, Heritable disorders of connective tissue. 4th ed. (CV Mosby, St Louis, 1972). — 3. ORENDAC M, ZEMAN J, STABLER SP, ALLEN RH, KRAUS JP, BODAMER O, STÖCKLER-IPSIROGLU S, KVASNICKA J, KOZICH V, J Inherit Metab Dis, 26 (2003) 761. 4. GAN-SCHREIER H, KEBBEWAR M, FANG-HOFFMAN J, WILRICH J, ABDOH G, BEN-OMRAN T, SHAHBEK N, BENER A, AL RIFAI H, AL KHAL AL, LINDNER M, ZSCHOCKE J, HOFFMANN GF, J Pediatr, 156 (2010) 427. — 5. MUDD SH, SKOVBY F, LEVY HL, PETTIGREW KD, WILCKEN B, PYERITZ RE, ANDRIA G, BOERS GHJ, BROMBERG IL, CERONE R, FOWLER B, GRÖBE H, SCHMIDT H, SCHWEITZER L, Am J Hum Genet, 37 (1985) 1. — 6. MUDD SH, LEVY HL, KRAUS JP, Disorders of transsulfuration. In: SCRIVER CR, BEAUDET AL, SLY WS, VALLE D (Eds) The metabolic and molecular bases of inherited disease. 8th ed. (McGraw-Hill, New York, 2001). — 7. WEISS N, Curr Drug Metab, 6 (2005) 27. — 8. UNDA S, BROZEK J, JANKOWSKI M, SIUDAK Z, SZCZEKLIK A, JAKUBOWSKI H, Arterioscler Thromb Vasc Biol, 26 (2006) 1397. — 9. LOVČIĆ V, KES P, REINER Ž, Acta Med Croatica (In Croat), 60 (2006) 21. — 10. PERLA-KAJAN J, TWARDOWSKI T, JAKUBOWSKI H, Amino Acids, 32 (2007) 561. — 11. BASS HN, GRAVE DL, MARDACH R, CEDERBAUM SD, FUSTER CD, CHETTY MJ, Inher Metab Dis, 20 (1997) 831. — 12. CBS MUTATION DATABASE, Denver: University of Colorado School of Medicine, 2010, accessed 7.9.2010. Available from: URL: <http://cbs.fl.cuni.cz/index.php>. — 13. HUTTUNEN R, KAIRALUOMA MI, MOKKA RE, Surgery, 81 (1977) 184. — 14. ORRINGER RD, COLLIER JA, VEIDENHEIMER MC, Dis Colon Rectum, 26 (1983) 323. — 15. DUDMAN NP, TYRRELL PA, WILCKEN DE, Metabolism, 36 (1987) 198. — 16. HUBMACHER D, BARTELS R, TIEDEMANN K, BRINCKMANN J, VOLLBRANDT T, BÄTGE B, NOTBOHM H, REINHARDT DP, J Biol Chem, 280 (2005) 34946. — 17. LUBEC B, FANG-KIRCHER S, LUBEC T, BLOM HJ, BOERS GH, Biochim Biophys Acta, 1315 (1996) 159. — 18. LONN E, YUSUF S, ARNOLD MJ, SHERIDAN P, POGUE J, MICKS M, MCQUEEN MJ, PROBSTFIELD J, FODOR G, HELD C, GENEST J JR, HEART OUTCOMES PREVENTION EVALUATION (HOPE) 2 INVESTIGATORS, N Engl J Med, 354 (2006) 1567. — 19. ZOUNGAS S, MCGRATH BP, BRANLEY P, KERR PG, MUSKE C, WOLFE R, ATKINS RC, NICHOLLS K, FRAENKEL M, HUTCHISON BG, WALKER R, MCNEIL JJ, J Am Coll Cardiol, 46 (2006) 1108. — 20. BONAA KH, NJOLSTAD I, UELAND PM, SCHIRMER H, TVERDAL A, STEINGEN T, WANG H, NORDREHAUG JE, ARNESEN E, RASMUSSEN K,

NORVIT TRIAL INVESTIGATORS, N Engl J Med, 354 (2006) 1578. —
21. MAGNER M, KRUPKOVA L, HONZIK T, ZEMAN J, HYÁNEK J,
KOŽICH V, J Inherit Metab Dis, 2010 Jun 22. [Epub ahead of print]. —

22. GAUSTADNES M, RÜDIGER N, RASMUSSEN K, INGERSLEV J,
Arterioscler Thromb Vasc Biol, 20 (2000) 1392.

D. Muačević-Katanec

University of Zagreb, Zagreb University Hospital Center, Department of Internal Medicine, Division for Metabolic Diseases, Kišpatičeva 12, 10000 Zagreb, Croatia
e-mail: dmuacevi@mef.hr

SPONTANA PERFORACIJA TANKOG CRIJEVA KOD ODRASLOG BOLESNIKA S KLASIČNOM HOMOCISTINURIJOM I NOVIM MUTACIJAMA GENA ZA CISTATIONIN- β -SINTAZU

S A Ž E T A K

Klasična homocistinurija je bolest u kojoj nalazimo povišene vrijednosti homocisteina u plazmi i urinu, a najčešće nastaje kao posljedica nedostatka cistationin- β -sintaze. Prema podacima dostupnim u literaturi ovo je prvi opisani slučaj odraslog bolesnika s dubokom venskom trombozom i spontanom netraumatskom perforacijom tankog crijeva. Bolesnik se javio u hitnu kiruršku ambulantu zbog jakih, grčevitih i muklih bolova u trbuhu, sa znakovima peritonealnog nadražaja, koji su počeli dan ranije. Bolesnik je bio lošeg općeg stanja, hipotenzivan i tahikardan. U laboratorijskim nalazima dominirali su anemija i povišene vrijednosti upalnih markera. Nakon radiološke i laboratorijske obrade pristupilo se hitnoj laparotomiji, te je nađena perforacija tankog crijeva u gornjem lijevom hemiabdomenu. Patohistološki se radilo o nespecifičnom akutnom jejunitisu s granulocitnom infiltracijom, hemoragijom i nekrozom. Tuberkuloza, aktinomikoza i tifus su klinički i histološki isključeni. Kako su anamnestički, klinički i patohistološki isključeni mogući poznati uzroci perforacije, zaključili smo da se radi o netraumatskoj, spontanoj perforaciji tankog crijeva. Jedno od osnovnih obilježja homocistinurije je slabost vezivnog tkiva, koja se može protumačiti djelovanjem homocisteina na pojedine fragmente rekombinatnog humanog fibrilina-1 i kolagena putem degradacije disulfidnih veza i esencijalne aminokiseline lizina, nužnog građivnog elementa svih proteina ljudskog tijela. Spoznaja o mogućoj spontanoj perforaciji tankog crijeva u bolesnika s homocistinurijom važna je kao doprinos kliničkom znanju o mogućim kroničnim komplikacijama koje se mogu očekivati u osoba s ovakvim metaboličkim premećajem i kao činjenica da kod bolesnika sa spontanom perforacijom tankog crijeva treba u sklopu rutinske obrade odrediti i razinu homocisteina u plazmi. DNA analiza je kod ovog bolesnika pokazala ukupno tri mutacije na genu za cistationin- β -sintazu, poznatu mutaciju 1278T:c.833T>C, te dvije do sada nepoznate mutacije, V372G:c.1133T>G i D520G:c.1558A>G na eksonu 15. Kliničko značenje ovih mutacija još nije poznato.