

# Anatomical study of the facial nerve canal in comparison to the site of the lesion in Bell's palsy

---

**Dawidowsky, Krsto; Branica, Srećko; Batelja, Lovorka; Dawidowsky, Barbara; Kovač-Bilić, Lana; Šimunić-Veselić, Anamarija**

*Source / Izvornik:* **Collegium Antropologicum, 2011, 35, 61 - 65**

**Journal article, Published version**

**Rad u časopisu, Objavljena verzija rada (izdavačev PDF)**

*Permanent link / Trajna poveznica:* <https://um.nsk.hr/um:nbn:hr:105:299546>

*Rights / Prava:* [In copyright](#)/[Zaštićeno autorskim pravom.](#)

*Download date / Datum preuzimanja:* **2024-11-25**



*Repository / Repozitorij:*

[Dr Med - University of Zagreb School of Medicine  
Digital Repository](#)



# Anatomical Study of the Facial Nerve Canal in Comparison to the Site of the Lesion in Bell's Palsy

Krsto Dawidowsky<sup>1</sup>, Srećko Branica<sup>1</sup>, Lovorka Batelja<sup>2</sup>, Barbara Dawidowsky<sup>3</sup>, Lana Kovač-Bilić<sup>1</sup> and Anamarija Šimunić-Veselić<sup>1</sup>

<sup>1</sup> University of Zagreb, Zagreb University Hospital Center, ENT Department, Zagreb, Croatia

<sup>2</sup> University of Zagreb, School of Medicine, Pathology Department, Zagreb, Croatia

<sup>3</sup> Ophthalmology Department, Children's Hospital, Zagreb, Croatia

## ABSTRACT

*The term Bell's palsy is used for the peripheral paresis of the facial nerve and is of unknown origin. Many studies have been performed to find the cause of the disease, but none has given certain evidence of the etiology. However, the majority of investigators agree that the pathophysiology of the palsy starts with the edema of the facial nerve and consequent entrapment of the nerve in the narrow facial canal in the temporal bone. In this study the authors wanted to find why the majority of the paresis are suprapedial, i.e. why the entrapment of the nerve mainly occurs in the proximal part of the canal. For this reason they carried out anatomical measurements of the facial canal diameter in 12 temporal bones. By use of a computer program which measures the cross-sectional area from the diameter, they proved that the width of the canal is smaller at its proximal part. Since the nerve is thicker at that point because it contains more nerve fibers, the authors conclude that the discrepancy between the nerve diameter and the surrounding bony walls in the suprapedial part of the of the canal would, in cases of a swollen nerve after inflammation, cause the facial palsy.*

**Key words:** Bell's palsy, facial nerve canal, site of the lesion

## Introduction

Idiopathic peripheral paresis of the facial nerve, also known as Bell's palsy, is a disorder on which expert opinions still differ. However, it does have certain characteristics. It is usually acute in onset, unilateral, with a sense of fullness or pain in the ear, face, neck or tongue in about half of the patients. The minority of them has recurrent facial palsy, positive family history is present in about 15% of the cases, and the stapedial reflex is decreased or absent in almost 90% of the patients. Usually, the paresis will resolve spontaneously in several weeks.

The term Bell's palsy has been used to describe a facial paresis of acute onset and limited duration, the etiology of which was idiopathic. It was named after the English physician Sir Charles Bell, who in 1821 found that the facial nerve was a motor nerve not connected with the sensory innervation of the face. By that time, he named this nerve »respiration nerve«, since patients with the palsy had breathing difficulties resulting from

the collapse of the nostril on the affected side. 60 years later, in 1885, also in England, Sir William Gowers found that in the majority of the patients palsy did not improve after elimination of possible causes such as ear inflammation, fracture, tumor, herpes, or surgical damage of the facial nerve. He established a new clinical identity, the facial paresis of the unknown cause, and named it after his teacher, Sir Charles Bell<sup>1,2</sup>.

Today's knowledge of etiopathogenesis of Bell's palsy is not superior compared to the late 19<sup>th</sup> century. In spite of improved diagnostic methods, the percentage of facial paresis of unknown origin remains almost the same. The treatment is, however, enhanced, especially after the introduction of steroid and antiviral drug therapy, as well as advanced surgical and rehabilitation methods, which have contributed to often complete recovery and shortened the duration of the disorder.

Nevertheless, the etiology of Bell's palsy remains unknown even today, and diagnosis, which is still made by exclusion, is accurate only if no other cause of the paresis can be found. A large number of etiopathological and anatomical studies on Bell's palsy was performed over the period of the last 40 years, but none has given firm evidence that would explain the etiopathogenesis. The reported findings are not uniform, reflecting the different periods from the onset of paralysis to the nerve examination, methods of preparation, portion of the nerve studied, and possibly etiology of the facial paralysis. Most recent reports, however, demonstrate inflammatory infiltrates throughout the course of the facial nerve. Vascular thrombosis is generally not observed, although intraneural hemorrhage is seen occasionally<sup>3–8</sup>. It has long been assumed that the herpes simplex virus (HSV) is the infecting agent in Bell's palsy, and some recent investigations provide increasing evidence to support this hypothesis. The development of polymerase chain reaction techniques has allowed identification of HSV in the geniculate ganglion and facial nerve. Additional support is given by replication of the clinical syndrome in an animal model, where a histopathological study revealed significant edema and inflammation around the facial nerve<sup>9–11</sup>. A hypothesis that immunologic disorder can play an important role in the etiopathogenesis of Bell's palsy is also present. Some of the authors found the correlation between palsy and some HLA haplotypes as well as dysfunction in CD4 / CD8 ratio<sup>12–15</sup>.

Although those investigations did not strictly confirm any theory regarding the etiology of Bell's palsy, the pathophysiologic mechanism is more certain and there are no major discrepancies. The muscle paralysis is caused by (viral?) inflammation and (possible autoimmune) demyelination of the facial nerve, which leads to the edema of the nerve in the narrow temporal bone canal. Consequent entrapment of the nerve results in the paresis of the facial muscles, although the precise site of the disorder is still not clear. 50 years ago, some authors believed that strangulation occurred in the area of stylomastoid foramen, while later papers suggested that this happened in the tympanic or mastoid part of the facial canal<sup>16–18</sup>, as well as in the area of the geniculate ganglion, at the meatal foramen where the facial nerve enters the facial canal, and at the labyrinth portion where the nerve enters the temporal bone<sup>19,20</sup>.

The facial nerve develops from two separate embryologic structures, the primordial otic capsule and Reichert's cartilage from the second branchial arch. In the 10-week-old fetus, the facial canal is a deep sulcus, and just about that time the ossification of the canal begins<sup>21</sup>. A number of anatomical studies of the facial nerve diameter<sup>22–26</sup> have shown that thickness of the nerve in the bony canal decreases as it approaches the stylomastoid foramen. This happens because several branches leave the nerve in the canal, and there are fewer nerve fibers at the distal end. According to embryonic ossification<sup>21</sup>, the diameter of the bony canal should also reduce. Unfortunately, the aforementioned studies did not confirm that,

and their results suggested that the canal is more or less equal in diameter. As mentioned earlier, the exact site of nerve lesion in the canal is not clear. Facial paralysis (regarding the etiology) is characterized by the dysfunction of the nerve fibers. If the lesion occurs proximally to the branch that innervates the stapedial muscle (stapedial nerve), stimulation of this nerve will not produce contraction of the stapedial muscle, and the stapedial reflex will be »negative« (this reflex occurs when sensory cells in the cochlea are stimulated with high intensity sound and is easily measured during tympanometry). Just opposite, with »positive« stapedial reflex at facial palsy, we conclude that lesion of the nerve takes place distally from the detachment of the stapedius nerve from the main stem of the facial nerve. Since the majority of facial paresis are suprastapedial (almost 90%), the probable entrapment is situated proximally in the facial canal, where the diameter of the nerve is larger and in greater collision with the surrounding bony walls.

In our study we decided to investigate the diameter of the facial canal, with special interest in its entrance. We expected that the canal would be more or less the same in diameter, which would explain why lesion of the nerve happens near the entrance, where the facial nerve is thicker.

## Materials and Methods

For the period of the last 20 years, 628 patients suffering from Bell's palsy were treated in our department. The stapedial reflex was measured in all of them, and in 533 cases (or 85%) it was found negative, suggesting the suprastapedial lesion of the facial nerve.

At the pathology department, 12 adult temporal bones were explanted from 12 different donors. For the reason of disinfection, bones were held in 30% formaldehyde for the period of one month, and during the next 3 weeks in 96% alcohol. After the complete removal of soft tissue, the bones were demineralized in 7.5% trichloroacetic acid for 40 days. After the bone tissue had become soft, we removed unnecessary bone and shaped bone cubes with the facial canal in the middle. These artifacts were cut with the blade vertical to the facial canal route at two sites. First, at the spot where the nerve leaves the internal meatus, just at the entrance of the facial canal, and before the fibers for stapedius nerve leave the main trunk of the nerve. Second, at the end of the canal, near the stylomastoid foramen. At this point, we had two bone cubes (each size about one ccm with the facial canal in the middle) for each temporal bone. After the neutralization with lithium carbonate, we washed the artifacts with water, purified the artifacts for five days with alcohol in ascending concentrations (50%, 70%, 80%, 96%, and 100%), and then left them for a month in the container with cedar oil. When artifacts became completely translucent, they were put in the paraffin. With the microtome blade, four vertical cuts (with 0.5 mm distance) were performed at the entrance and exit of each facial canal. Finally, we got eight histological artifacts

from each bone that were fixed on the glass and stained with hemalaun eosin. All the procedures were performed by consent and according to regulations of the ethical committee of the School of Medicine of Zagreb.

Using the Leica microscope connected to the computer, under the 20 x zoom, we measured two diameters – vertical and horizontal, since the cross-section of the canal was not a perfect circle. Using the morphometric software for analysis of the histopathologic images ISSA 3.1 (Vamstek), from the diameters we calculated the cross – sectional areas of the canal in square millimeters.

We calculated the arithmetic mean between four cross-sectional areas of each entrance and exit of the canal and determined the mean value of cross-sectional area in square millimeters at the proximal and the distal end of each facial canal. All together, we had 24 mean values, 12 from the entrance and 12 from the end, which we used for statistical analysis.

**Results**

The mean values in square millimeters of the cross-sectional areas of the entrance and exit of the facial canal for all 12 bones are given in Table 1. At first sight, the results suggested that the sectional areas of the facial canal were larger at their proximal ends. This was the case in 10 bones, while two bones had larger exits (Figure 1). The numeric values varied among the bones, which was not surprising due to different age, sex and size of the cadavers whose temporal bones were explanted.

In order to compare the data statistically, we decided to test the results for distribution. The mean value of the cross-sectional area of the entrance was 3.05 mm<sup>2</sup> with standard deviation of 0.84, while mean value of the cross-sectional area of the exit was 3.33 mm<sup>2</sup> with standard deviation of 0.94. Using Kolmogorov-Smirnov test, we tested our results and found that there was no statis-

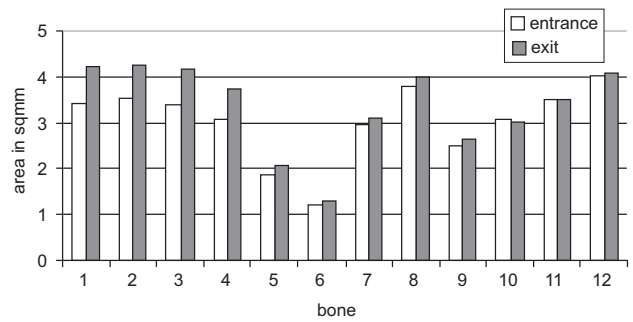


Fig. 1. Relations between cross-sectional areas of the facial canal (entrance and exit).

tically significant difference in our distribution compared to the normal distribution (p=0.712 for the cross-sectional area of the entrance and p=0.875 for the cross-sectional area of the exit from the facial canal) Table 2.

The results suggested a normal distribution. However, since the number of samples was relatively small, we decided to use non-parametric methods for calculation in order to avoid mistakes in statistics. Our hypothesis was that the width of the facial canal was alike on its entrance and exit. This would have explained the reason of high percentage of suprapedial lesions in Bell's palsy, since entrapment of the nerve would have occurred more often at the proximal end, where the disproportion between the thickness of the nerve and the width of the surrounding bony canal existed. We were, therefore, interested whether there was a significant statistical difference between cross-sectional areas of the entrance and the exit of the facial canal.

We used the Wilcoxon test of equivalent pairs to compare the difference between the canal ends and ranged the results. Two ranks were negative (entrance of the canal was wider in two bones) with mean of 1.50, while 10 ranks were positive with mean 7.50 table 3 and 4. None of the bones had equal cross-sectional areas of the entrance and the exit. As seen from table 5, z value was –

**TABLE 1**  
MEAN VALUES IN SQUARE MILLIMETERS OF THE CROSS-SECTIONAL AREAS OF THE ENTRANCE AND EXIT OF THE FACIAL CANAL

Bone	Cross sectional area – entrance	Cross sectional area – exit
1	3.40	4.20
2	3.51	4.23
3	3.38	4.17
4	3.04	3.75
5	1.88	2.05
6	1.20	1.31
7	2.95	3.09
8	3.79	3.98
9	2.48	2.64
10	3.06	3.03
11	3.49	3.48
12	4.02	4.07

**TABLE 2**  
COMPARISON TO NORMAL (NO STATISTICALLY SIGNIFICANT DIFFERENCE COMPARED TO NORMAL DISTRIBUTION, P=0.712/ENTRANCE AND P=0.875 EXIT), ONE-SAMPLE KOLMOGOROV-SMIRNOV TEST

	entrance	exit
N	12	12
Normal parameters	$\bar{X}$	
	3.0508	3.3333
	Standard deviation	0.8358 0.9431
Largest deviations	Absolute	0.202 0.171
	Positive	0.123 0.171
	Negative	-0.202 -0.171
Z	0.700	0.592
p	0.712	0.875

Test for distribution is normal

**TABLE 3**  
RANKS

		N	Mean Rank	Sum of Ranks
Exit Area	Negative ranks	2 <sup>a</sup>	1.50	3.00
Entrance Area	Positive ranks	10 <sup>b</sup>	7.50	75.00
	Equal ranks	0 <sup>c</sup>		
	Total	12		

A Exit Area < Entrance Area  
 B Exit Area > Entrance Area  
 C Entrance Area = Exit Area

**TABLE 4**  
WILCOXONOV TEST OF EQUIVALENT PAIRS

	Exit Area — Entrance Area
Z	-2.824 <sup>a</sup>
Asymp. Sig. (2-Tailed)	p=0.005

<sup>a</sup> based on negative ranks

2.824 (based on negative ranks) with p=0.005. The results show a statistically significant difference between the values of the cross-sectional areas of the entrance and the exit of the facial canal.

**Discussion and Conclusion**

The facial nerve runs through the temporal bone in the narrow bony canal, where three branches (greater petrosal nerve, stapedius nerve and chorda tympani) leave the main trunk. Consequently, the number of nerve fibers reduces as the nerve approaches the canal exit, and the width of the facial nerve on the distal end is significantly smaller. When a lesion of the facial nerve (regardless of the still unidentified etiology) occurs in the canal, the following edema causes the entrapment of the main trunk with clinical expression of Bell's palsy. Since almost 90% of the peripheral facial pareses are supra-stapedial (i.e. the lesion happens before the stapedius nerve leaves the main facial stem), it is presumed that the breadth of the proximal part of the canal is in discrepancy with the thickness of the facial nerve.

We assumed that the canal is of equal width during its route in the temporal bone, and the edema which occurs during the nerve inflammation causes the entrapment proximally because of the thickness of the proximal portion of the facial nerve. To confirm our hypothesis, we decided to measure the cross-sections of both ends of the canal and compare their areas. Through the aforementioned procedure we prepared 48 histological artifacts of the facial canal from explanted temporal bones. Since cross-sectional areas were not perfect in shape, we used the morphometric computer software to calculate the numeric values of the cross-sectional areas in square milli-

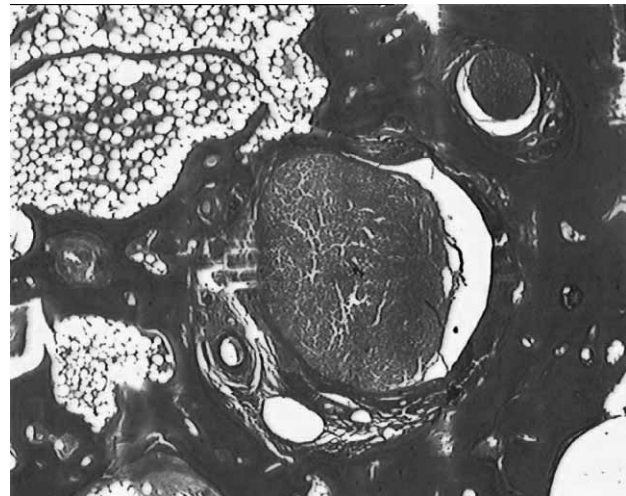


Fig. 2. Entrance of the facial canal.

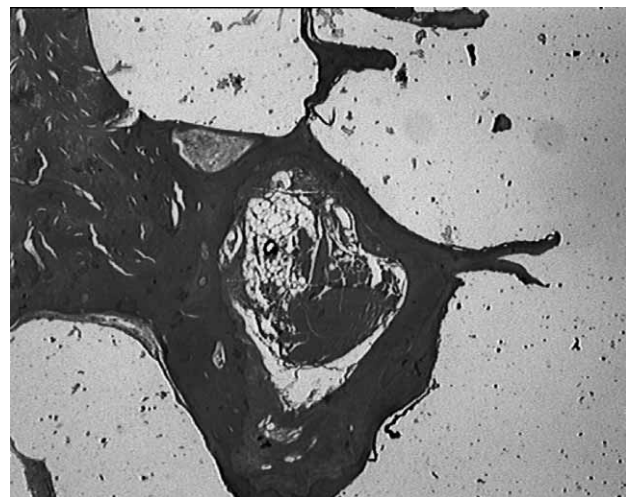


Fig. 3. Exit of the facial canal.

meters and determined the mean values for each entrance and exit of the canal. Although the distribution was found normal, we decided to use non-parametric Wilcoxon test for equivalent pairs regarding the small number of samples. The test showed a statistically significant difference between cross-sectional areas of the entrance and exit of the canal. Furthermore, the area of the exit was wider compared to the entrance, which meant that the canal was narrower proximally, where the nerve was thicker.

In conclusion, the results of the study suggested several interesting facts. First, they were compatible with some more recent studies of the facial canal concerning the site of the nerve lesion. Second, they failed to fulfill the expectations regarding the embryonic development of the facial nerve and temporal bone (it was expected that the diameter of the bony canal follows the diameter of the nerve). Although we did not manage to confirm our hypothesis that the canal was equal in diameter dur-

ing its course, the study had certainly given the answer to the question why the majority of the nerve lesions in Bell's palsy were suprapedial. According to our results, the width of the facial canal was growing distally, which gave even more reason for the entrapment to occur proximally in the canal. The discrepancy in size be-

tween the facial nerve and the surrounding bony canal was in that case larger compared to the supposed situation where the canal would have been uniformly wide throughout its route.

## REFERENCES

1. BELL C, Trans R Soc Lond, 111 (1821) 398. — 2. GOWERS WR, A Manual of Disease: The Nervous System (Churchill, London, 1893). — 3. CAPTIER G, CANOVAS F, BONNEL F, SEIGNARBIÉUX F, Plastic & Reconstructive Surgery, 115(6) (2005) 1457. — 4. BAILEY BJ (Ed) Head and Neck Surgery – Otolaryngology (Philadelphia, PA, J.B. Lippincott Co., 1996). — 5. BOIES LR (Ed) Fundamentals of Otolaryngology (Philadelphia, PA, J.B. Lippincott Co., 1989). — 6. CUMMINGS C (Ed) Otolaryngology – Head and Neck Surgery (St. Louis, MO, Mosby – Year Book, Inc., 1993). — 7. MAY M, The Facial Nerve (New York: Thieme – Stratton, 1986). — 8. LISTON SL, KLEID MS, Laryngoscope, 99 (1989) 23. — 9. BURGESS RC, MICHAELS L, BALE JF JR, SMITH RJ, Ann Otol Rhinol Laryngol, 103 (1994) 775. — 10. MURAKAMI S, MIZOBUCHI M, NAKASHIRO Y, DOI T, HATO N, YANAGIHARA N, Ann Intern Med, 124 (1996) 27. — 11. MULKENS PSJZ, BLEEKER JD, SCHRODER FF, Clin Otolaryngol, 5 (1980) 303. — 12. GORODEZKY C, Ghedini Pub, (1990) 315. — 13. BUMM P, SCHLIMOK G, Ghedini Pub, (1990) 319. — 14. ADOUR KK, BYL FM, HILSINGER RL JR, KAHN ZM, SHELDON ML, Laryngoscope, 88 (1978) 787. — 15. WEBER T, JURGENS S, LUER W, J Neurol, 234 (1987) 308. — 16. CAWTHORNE T, Annals Otol, 774 (1963). — 17. MAY M, Laryngoscope, 95 (1985) 406. — 18. FISCH U, ESSEN E, The acute facial palsies (Berlin, Springer Verlag, 1977). — 19. MARSH M, COKER NJ, Otolaryngol Clin North Am, 24 (1991) 675. — 20. LISTON SL, KLEID MS, Laryngoscope, 99 (1989) 23. — 21. ŠERCER A, Otolaringologija (Medicinska Knjiga, Zagreb, 1951). — 22. SCHRODER JM, Eur Arch Otorhinolaryngol, (1994) 16. — 23. EICHER SA, COKER NJ, ALFORD BR, IGARASHI M, SMITH RJ, Arch Otolaryngol Head Neck Surg, 116(9) (1990) 1030. — 24. THURNER KH, EGG G, SPOENDLIN H, SCHROTT-FISCHER A, Eur Arch Otorhinolaryngol, 250(3) (1993) 161. — 25. NAKASHIMA S, SANDO I, TAKAHASHI H, FUJITA S, Laryngoscope, 103(10) (1993) 1150. — 26. ARAI A, YAMAKAWA T, HAGIWARA A, YOSHIKAWA H, ICHIKAWA G, Auris Nasus Larynx, 30(3) (2003) 227.

K. Dawidowsky

University of Zagreb, Zagreb University Hospital Center, Department of Otorhinolaryngology, Kišpatićeva 12, 10 000 Zagreb, Croatia  
e-mail: krsto@mef.hr

## ANATOMSKA STUDIJA KANALA FACIJALISA OBZIROM NA MJESTO OŠTEĆENJA ŽIVCA U BELLOVOJ PAREZI

### SAŽETAK

Periferna kljenut ličnog živca kojoj se ne može pronaći neposredni uzrok naziva se Bellovom parezom. Klinička slika naglo nastale pareze lica vrlo je stresna za bolesnike, a liječenje je simptomatsko i sastoji se od davanja protuupalnih lijekova koji smanjuju edem živca i poboljšavaju oksigenaciju perifernog tkiva te na taj način dovode do bržeg oporavka. Od prvog opisa bolesti prošlo je 180 godina, postignut je napredak u dijagnostici i terapiji, ali do sada provedena istraživanja nisu uspjela objasniti etiologiju ove bolesti. Iako rezultati mnogobrojnih studija pokazuju da pareza nastaje zbog edema facijalisa unutar koštanog kanala u temporalnoj kosti, mjesto samog uklještenja živca nije određeno. Retrogradnom studijom na uzorku od 628 bolesnika s Bellovom parezom koji su proteklih 20 godina liječeni na Klinici za Bolesti uha, nosa i grla Medicinskog fakulteta KBC Zagreb autori članka su ustanovili suprapedijско oštećenje facijalisa kod njih 533 (85%). Prepostavili su da uklještenje nastaje u proksimalnom dijelu kanala ličnog živca, prije odvajanja grane za inervaciju stapedijskog mišića, upravo zbog nesrazmjera između širine kanala i debljine samog živca. Da bi to dokazali, proveli su studiju na 12 temporalnih kostiju u kojoj su kompjutorski izmjerili i usporedili površine poprečnog presjeka ulaza i izlaza koštanog kanala facijalisa. Rezultati su pokazali da je širina kanala značajno manja na ulazu nego na izlazu, dok je sam živac deblji na početku. Autori zaključuju da je razlog velike učestalosti suprapedijalnih oštećenja facijalisa u bolesnika s Bellovom parezom upravo u nesrazmjeru između debljine živca i površine poprečnog presjeka kanala u njegovom početnom dijelu.