

# C-myc expression in the microvessels of medulloblastoma

---

**Stanić, Gabriјela; Čupić, Hrvoje; Žarković, Kamelija; Tomas, Davor; Krušlin, Božo**

*Source / Izvornik:* **Collegium Antropologicum, 2011, 35, 39 - 42**

**Journal article, Published version**

**Rad u časopisu, Objavljena verzija rada (izdavačev PDF)**

*Permanent link / Trajna poveznica:* <https://um.nsk.hr/um:nbn:hr:105:289344>

*Rights / Prava:* [In copyright](#)/[Zaštićeno autorskim pravom.](#)

*Download date / Datum preuzimanja:* **2024-07-18**



*Repository / Repozitorij:*

[Dr Med - University of Zagreb School of Medicine  
Digital Repository](#)



# C-myc Expression in the Microvessels of Medulloblastoma

Gabrijela Stanić<sup>1</sup>, Hrvoje Čupić<sup>2</sup>, Kamelija Žarković<sup>3,4</sup>, Davor Tomas<sup>2,4</sup> and Božo Krušlin<sup>2,4</sup>

<sup>1</sup> University of Zagreb, »Sveti Duh« University Hospital, Department of Pathology and Cytology, Zagreb, Croatia

<sup>2</sup> University of Zagreb, »Sestre milosrdnice« University Hospital, »Ljudevit Jurak« Department of Pathology, Zagreb, Croatia

<sup>3</sup> University of Zagreb, Zagreb University Hospital Center, Department of Pathology, Zagreb, Croatia

<sup>4</sup> University of Zagreb, School of Medicine, Zagreb, Croatia

## ABSTRACT

*The increased expression of c-myc is related to neoplastic transformation and angiogenesis. Therefore, the assessment of expression of c-myc in endothelial cells and neovascularization could help to determine the biological behavior of the tumor. We analyzed neovascularization and c-myc expression in 36 medulloblastoma specimens. The results were shown by determining immunohistochemical staining index (ISI), the sum of staining intensity (SI) and the percentage of positive cells (PPC) in the blood vessels endothelium of the tumor. We also performed the microvessel count (MVC) in 10 high-power fields (400X) with the most prominent vascularization and expressed it as microvessel density per mm<sup>2</sup> (MVD). C-myc immunostaining intensity index in blood vessel endothelium is grouped into four groups, 0 – no reaction, I – weak reaction (ISI = 1 or 2), II – moderate reaction (ISI = 3 or 4), III – strong reaction (ISI = 5 or 6). Statistically significant differences ( $p=0.0214$ ) have been found between groups 0 and 1 compared to groups 2 and 3. A higher percentage of positive cells has been found in male patients than in female ones ( $p=0.0483$ ). C-myc PPC 0 or 1 has on the average smaller density of blood vessels per mm<sup>2</sup> than c-myc PPC 2 or 3, but the difference is not statistically significant. C-myc ISI 0 or 1 has, on the average, smaller density of blood vessels per mm<sup>2</sup> than c-myc ISI 2 or 3, but the difference is not statistically significant. We concluded that c-myc staining intensity was associated with higher microvessels density.*

**Key words:** c-myc, endothelium, medulloblastoma, microvessels, vascularization

## Introduction

Medulloblastoma is a malignant, invasive, neuroectodermal, embryonal tumor which originates from the precursors of cerebellar granular cells with predominantly neural differentiation<sup>1–4</sup>. It represents 20% of tumors in infants and it sporadically appears in genetic diseases such as Turcotte and Gorlin syndrome, in numerous chromosomal abnormalities and more often in male children (ratio M:F is 1.5:1)<sup>1,2</sup>. Its symptoms are related to hydrocephalus and leptomeningeal disease (LMD) as a consequence of metastases via the cerebrospinal fluid. Extracranial metastases are rare, but several cases have been described in literature<sup>5–11</sup>.

In many experimental models, increased c-myc expression induces neoplastic cell transformation as well as

the angiogenesis<sup>12–15</sup>. The ability of c-myc to intensify angiogenesis and lymphangiogenesis supports the theory of its participation in the process of tumor growth and metastasizing<sup>13–15</sup>. Uncontrolled angiogenesis has an important role in tumor growth and is an important factor of malignancy<sup>13–15</sup>. In humans, c-myc is more frequently expressed in solid and hematopoietic tumors, in which tumor growth is directly correlated with the intensity of angiogenesis. The ability of tumor cells to metastasize is also associated with the formation of new blood vessels. Early angiogenic changes are the consequence of myc clonal expression in progenitor cells, while the late ones are the consequence of local hypoxia. Increased tumor vascularization is a poor prognostic factor<sup>15,16</sup>.

Since brain tumors do not metastasize by lymphatics and exceptionally rarely cause distant metastases, the estimate of tumor vascularization and c-myc expression could be used to determine biological behaviour of the tumor<sup>9–11,17</sup>. The goal of our research was to estimate the c-myc expression in endothelial cells and to determine the average density of blood vessels in medulloblastomas, which could serve as predictors of aggressive behavior.

## Material and Methods

Thirty-six tumor specimens were obtained from patients who underwent surgery for medulloblastoma at the Neurosurgery Department of the »Sestre milosrdnice« University Hospital and the Zagreb University Hospital Center in the period from 1997 to 2006 were analyzed in our paper. Tumors were pathohistologically analyzed at the »Ljudevit Jurak« Department of Pathology, the »Sestre milosrdnice« University Hospital. The diagnosis of medulloblastoma was histologically confirmed in all cases. Tumors were classified as a classic type of medulloblastoma in 23 cases, while 13 tumors were other medulloblastoma type according to the World Health Organization (WHO) criteria<sup>1</sup>.

Formalin fixed, paraffin embedded tissue was cut at 5 µm thickness and stained by hematoxylin and eosin. Additional slides were deparaffinized and stained with monoclonal antibody 9E10 M3570 to c-myc (Dako Epos, Denmark), following the Microwave Streptavidin Immuno-Peroxidase (MSIP) protocol on the TechMate™ Horizon automated immunostainer. A breast cancer tissue served as a positive control and the removal of the primary antibody was used as a negative control. The immunohistochemical reaction was membranous and cytoplasmatic.

The results were expressed semi-quantitatively, considering the intensity of staining and the proportion of endothelial cells showing an unequivocal immunoreactivity in 10 high-power fields (HPFs), (400x). All analyzed specimens containing only the tumor tissue and endothelial cells in intratumoral vessels were counted. The immunohistochemical staining index (ISI) was obtained as the sum of the staining intensity (SI) and the percentage of positive cells (PPC):  $ISI=SI+PPC^{18,19}$ .

SI was expressed as 0 – no reaction, 1 – weak, 2 – moderate, and 3 – strong reaction, while the PPC was determined in 10 HPFs, and expressed as follows: 0 – no positive cells, 1 – ≤10% of positive cells, 2 – > 10 – 50 % of positive cells, and 3 – more than 50% of positive cells.

According to the ISI, 4 groups were formed, as follows:

0 – no reaction

I – weak reaction (ISI = 1 or 2),

II – moderate reaction (ISI = 3 or 4),

III – strong reaction (ISI = 5 or 6).

The number of tumor microvessels (MVC – microvessel count) was counted in the 10 most active regions of vascularization (»hot spots«). The average MVC was calculated from 10 vascular »hot spots« and expressed as intratumoral microvessel density/mm<sup>2</sup> (MVD).

All samples were examined independently by three specialists in pathology (G. S., D.T. and B. K.) and any difference was resolved by a joint review.

In the statistical analysis, we used  $\chi^2$ -test with Yates correction, Kruskal-Wallis ANOVA and Mann-Whitney U-test. The differences were considered statistically significant with  $p<0.05$ .

## Results

In 14 (38.9%) tumor specimens endothelial cells did not react, weak reaction appeared in 7 (19.4%) specimens, moderate immunohistochemical reaction appeared in 5 (13.9%) and strong reaction was noted in 10 (27.8%) specimens (Table 1 and Figures 1 a and b).

Out of the 22 positive specimens, in 3 of them the percentage of positive cells was ≤10%, up to 50% of positive cells were found in 6 specimens, and over 50% of positive cells in 13 examined specimens (Table 1).

The ISI was 0 in 14 specimens, I in 3, II in 8, and III in 11 specimens (Table 1).

Of 14 cases with c-myc negative endothelial cells in 7 cases c-myc positivity was observed in tumor cells.

There was no statistically significant association between gender and ISI ( $p=0.102$ ), but a statistically significant male predominance was observed in cases with a higher ISI (II and III) ( $p=0.0483$ ).

**TABLE 1**  
RELATIONSHIP OF STAINING INTENSITY OF IMMUNOHISTOCHEMICAL REACTION (SI), PERCENTAGE OF POSITIVE CELLS (PPC) AND IMMUNOSTAINING INTENSITY INDEX (ISI) IN BLOOD VESSEL ENDOTHELIUM OF MEDULLOBLASTOMA

SI		PPC		ISI	
Staining intensity	Number of cases	Percentage of positive cells	Number of cases	Imunohistochemical staining index	Number of cases
0	14	0	14	0	14
1	7	1	3	I	3
2	5	2	6	II	8
3	10	3	13	III	11
	36		36		36

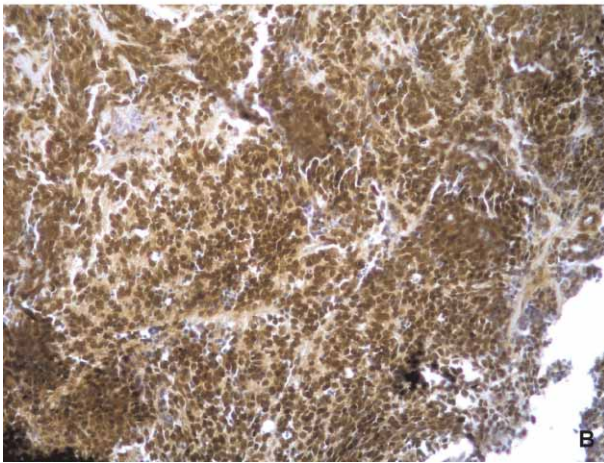
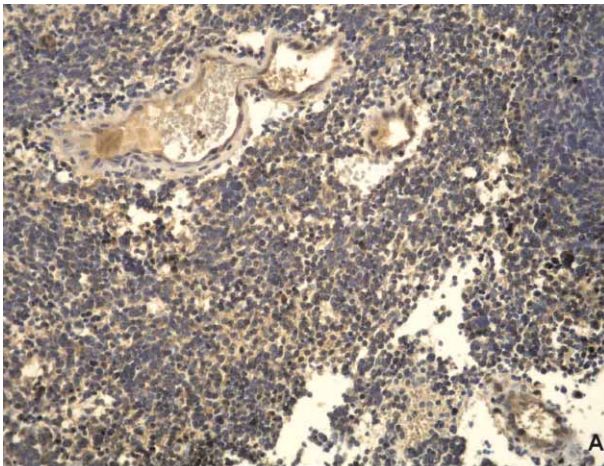


Fig. 1. (a) C-myc expression in the endothelial cells and (b) in the medulloblastoma cells (200x).

Neither MVC nor MVD correlated with SI, PPC and ISI, respectively (in all cases,  $p > 0.05$ ).

In specimens with weaker SI (groups 0 and 1) MVC and MVD were significantly lower compared to those in specimens with a stronger SI (groups 2 and 3) ( $p = 0.023$  and  $p = 0.021$ , respectively) (Table 2).

Neither PPC nor ISI showed a statistically significant correlation with MVC or MVD ( $p > 0.05$ ).

## Discussion and Conclusion

Angiogenesis, as a process of formation of new vascular spaces and blood supply, is crucial for a tumor cell survival. New blood vessels grow from pre-existing vascular spaces by proliferation of endothelial cells which kept the ability of multiplication and possible endothelial progenitor cells (EPC) present in bone marrow and circulation<sup>20</sup>. Factors included in the process of neovascularization can originate either from tumor cells or from host cells and act by autocrine or paracrine mechanism. Vascular growth factor (VEGF), angiopoietin 1 and 2 (Ang-1 and -2),

**TABLE 2**  
COMPARISON OF C-MYC STAINING INTENSITY IN THE ENDOTHELIAL CELLS WITH MICROVESSEL COUNT AND MICROVESSEL DENSITY

c-myc SI	N	MVC (median)	MVDx400/mm <sup>2</sup> (median)
0 or I	21	8 (0–32)	2.8 (0–11.4)
II or III	15	13 (6–20)	4.6 (2.1–7.1)
Mann-Whitney U-test	36	$p = 0.023$	$p = 0.021$

ephrin (Eph) and Eph tyrosine kinase receptor, platelet derived growth factor (PDGF), transforming growth factor (TGF)- $\beta$  and basic fibroblastic growth factor (bFGF) belong to this group. Uncontrolled angiogenesis has a significant role in tumor growth and is an important factor of malignancy<sup>20–27</sup>.

An increased c-myc expression is found in many models of neoplastic transformation. The ability to intensify angiogenesis as well as lymphangiogenesis supports the theory of participation of c-myc in metastasizing<sup>14,15</sup>. The research on mice has shown that hypoxia is followed by activation of c-myc and that the level of VEGF rises markedly compared to control groups, which shows that c-myc can induce the angiogenesis in vivo across soluble factors<sup>28</sup>.

Other authors have shown that the connection of c-myc and the expression of VEGF and other angiogenic factors were important for tumor neovascularization. The c-myc activation itself was sufficient to induce the VEGF expression and to suppress the expression of antiangiogenic factors such as thrombospondin 1 (TSP-1). These facts contribute strongly to the theory that c-myc is important in angiogenesis and tumor progression<sup>13,14,28–30</sup>.

Brain tumors of primitive neuroectodermal tumors/medulloblastomas (PNET/MB) group show the pronounced neovascularization, and it was shown that tumor cells produce angiogenic factors, particularly VEGF, which is important in tumor growth and tumor progression<sup>27</sup>. Quantitative analysis and 3D reconstruction of medulloblastoma microvasculature indicate that the classical medulloblastoma type has a dense microvasculature<sup>29</sup>. In nodular and desmoplastic type vascular spaces are arranged around nodular zones, while in giant cell type they form buds. Mean number of blood vessels is higher in classical form and medulloblastoma with extensive nodularity<sup>29</sup>.

We have not found statistically significant correlation between the percentage of positive cells and sex of patients, however, it has been noted that there were more cases with higher percentage of positive cells in male patient group; however it was not found statistically significant. Less intensive c-myc positivity and blood vessel density was observed in groups 0 and 1 comparing to groups 2 and 3.

We could conclude that the increased c-myc staining intensity is connected with a higher amount of blood vessels *per mm*<sup>2</sup>. If the increased c-myc expression is directly connected to the expression of angiogenic factors, particularly of VEGF, that fact can be important in further diagnostics and therapy.

It seems that using monoclonal neutralizing antibodies on VEGF, the therapeutic spectrum may be widened

and the possibility of tumor progression as well as of recurrence reduced<sup>31,32</sup>.

## Acknowledgements

Supported by Grant 108-1081870-1884 (B.K.) from the Ministry of Science and Technology, the Republic of Croatia.

## REFERENCES

1. KLEIHUES P, CAVENEE WK, Pathology and genetics of tumours of the nervous system. World Health Organization classification of tumours (Lyon, IARC Press, 2000) — 2. GIORDANA MT, SCHIFFER P, LANOTTE M, GIRARDI P, CHIO A, Int J Cancer, 80 (1999) 689. — 3. VANDENBERG SR, MAY EE, RUBINSTEIN LJ, Embryonal Cancer Metastasis Rev, 5 (1987) 343. — 4. HUBBARD JL, SCHEITHAUER BW, KISPERT DB, CARPENTER SM, WICK MR, LAWS ER JR, J Neurosurg, 70 (1989) 536. — 5. FOULADI M, GAJJAR A, BOYETT JM, WALTER AW, THOMPSON SJ, MERCHANT TE, JENKINS JJ, LANGSTON JW, LIU A, KUN LE, HEIDEMAN RL, J Clin Oncol, 10 (1999) 3234. — 6. LOUS DN, POMEROY SL, CAIRNCROSS JG, Cancer Cell, 1 (2002) 125. — 7. PALMER SL, GOLOUBEVA O, REDDICK WE, GLASS JO, GAJJAR A, KUN L, MERCHANT TE, MULHERN RK, J Clin Oncol, 19 (2001) 2303. — 8. GUPTA RK, NARAN S, LALLU S, FAUCK R, Cytopathology, 15 (2004) 38. — 9. AHMAD S, ROBERTS GJ, LUCAS VS, BARRETT AW, HARKNESS W, J Oral Pathol Med, 31 (2002) 244. — 10. TOPHAM EJ, FRANCIS N, BUNKER CB, Br J Dermatol, 154 (2006) 554. — 11. KOCH-BATI L, BOUAOUINA N, HENTATI D, NASR C, BESBES M, BENNA F, BOUSSEN H, MAALEJ M, Cancer Radiother, 10 (2006) 107. — 12. INDA MM, PEROT C, GUILLAUD-BATAILLE M, DANGLLOT G, REY JA, BELLO MJ, FAN X, EBERHART C, ZAZPE I, PORTILLO E, TUÑÓN T, MARTÍNEZ-PÉÑUELA JM, BERNHEIM A, CASTRESANA JS, Histopathology, 47 (2005) 631. — 13. BAUDINO TA, MCKAY C, PENDEVILLE-SAMAIN H, NILSSON JA, MACLEAN KH, WHITE EL, DAVIS AC, IHLE JN, CLEVELAND JL, Genes Dev, 16 (2002) 2530. — 14. RUDELL A, MEZQUITA P, BRANDVOLD KA, FARR A, IRITANI BM, Am J Pathol,

163 (2003) 2233. — 15. BRANDVOLD KA, NEIMAN P, RUDELL A, Oncogene, 19 (2000) 2780. — 16. BILLOTTE C, JANJI B, THIERY JP, JOUANNEAU J, Oncogene, 21 (2002) 8128. — 17. LOIACONO F, MORRA A, VENTURINI S, BALESTRERI L, Am J Roentgenol, 186 (2006) 1548. — 18. REMMELE W, SCHICKETANZ KH, Path Res Pract, 189 (1993) 862. — 19. AKSLEN LA, VARHAUG JE, Cancer, 76 (1995) 1643. — 20. DE PALMA M, VENNERI MA, GALLI R, SERGI SERGI L, POLITI LS, SAMPAOLESI M, NALDINI L, Cancer Cell, 8 (2005) 211. — 21. STEEG PS, Nature, 12 (2006) 895. — 22. CAO R, BJÖRNDAHL MA, RELIGA P, CLASPER S, GARVIN S, GALTER D, MEISTER B, IKOMI F, TRITSARIS K, DISSING S, OHHASHI T, JACKSON DG, CAO Y, Cancer Cell, 6 (2004) 333. — 23. COSTA C, SOARES R, SCHMITT F, APMIS, 112 (2004) 402. — 24. BENEZRA R, RAFII S, LYDEN D, Oncogene, 20 (2001) 8334. — 25. NIKOLOPOULOS SN, BLAIKIE P, YOSHIOKA T, GUO W, GIANCOTTI FG, Cancer Cell, 6 (2004) 471. — 26. OGAWA K, PASQUALINI R, LINDBERG RA, KAIN R, FREEMAN AL, PASQUALE EB, Oncogene, 19 (2000) 6043. — 27. HUBER H, EGGERT A, JANSS AJ, WIEWRODT R, ZHAO H, SUTTON LN, RORKE LB, PHILLIPS PC, GROTZER MA, Eur J Cancer, 37 (2001) 2064. — 28. KNIES-BAMFORTH UE, FOX SB, POULSOM R, EVAN GI, HARRIS AL, Cancer Res, 64 (2004) 6563. — 29. GILHUIS HJ, VAN DER LAAK JA, POMP J, KAPPELLE AC, GIJTENBEEK JM, WESSELING P, Angiogenesis, 9 (2006) 201. — 30. MEZQUITA P, PARGHI SS, BRANDVOLD KA, RUDELL A, Oncogene, 24 (2005) 889. — 31. SHIBUYA M, FEBS J, 276 (2009) 4636. — 32. GROTZER MA, CASTELLETTI D, FIASCHETTI G, SHALABY T, ARCARO A, Curr Cancer Drug Targes, 9 (2009) 176.

B. Krušlin

University of Zagreb, »Sestre milosrdnice« University Hospital, »Ljudevit Jurak« Department of Pathology, Vinogradska 29, 10000 Zagreb, Croatia  
e-mail: bkruslin@kbsm.hr

## EKSPRESIJA C-MYC-a U KAPILARAMA MEDULOBLASTOMA

### SAŽETAK

Povećana ekspresija c-myc-a povezana je s neoplastičnom transformacijom i stvaranjem krvnih žila. Procjena ekspresije c-myc-a u endotelnim stanicama i neovaskularizacija mogu pomoći u procjeni biološkog ponašanja tumora. U našem radu analizirali smo neovaskularizaciju i ekspresiju c-myc-a u 36 uzoraka tkiva meduloblastoma. Rezultati su prikazani semikvantitativno, određivanjem imunohistokemijskog indeksa bojenja (IIB) koji je dobiven kao zbroj intenziteta reakcije (IR) i postotka pozitivnih stanica (PPS). Broj tumorskih krvnih žila (MVC-microvessel count) dobiven je na 10 najaktivnijih područja neovaskularizacije pri povećanju od 400x. Brojčana vrijednost izražena je kao gustoća krvnih žila po mm<sup>2</sup> (MVD-microvessel density). Imunohistoelimijski indeks bojenja za c-myc u endotelu krvnih žila grupirali smo u četiri grupe, I – bez reakcije, I – slaba reakcija (IIB=1 ili 2), II – umjerena reakcija (IIB=3 ili 4), III – jaka reakcija (IIB=5 ili 6). Statistički značajne razlike (p=0,0214) našli smo između skupina 0 i 1 u odnosu na skupinu 2 i 3. Kod pacijenata muškog spola našli smo veći postotak reaktivnih stanica nego u pacijenata ženskog spola (p=0,0483). C-myc PPS 0 ili 1 ima u prosjeku manju gustoću krvnih žila po mm<sup>2</sup> nego c-myc PPS 2 ili 3, ali razlika nije statistički značajna. C-myc IIB 0 ili 1 ima u prosjeku manju gustoću krvnih žila po mm<sup>2</sup> nego c-myc IIB 2 ili 3, ali razlika nije statistički značajna. Na osnovu rezultata zaključili smo da je intenzitet c-myc bojanja povezan s većom gustoćom krvnih žila.