

# Sole stenting of large and giant intracranial aneurysms with self-expanding intracranial stents- limits and complications

---

Pavliša, Goran; Ozretić, David; Murselović, Tamara; Pavliša, Gordana; Radoš, Marko

Source / Izvornik: **Acta Neurochirurgica, 2010, 152, 763 - 769**

Journal article, Accepted version

Rad u časopisu, Završna verzija rukopisa prihvaćena za objavljivanje (postprint)

<https://doi.org/10.1007/s00701-009-0592-y>

Permanent link / Trajna poveznica: <https://um.nsk.hr/um:nbn:hr:105:700267>

Rights / Prava: [In copyright](#)/[Zaštićeno autorskim pravom.](#)

Download date / Datum preuzimanja: **2024-08-01**



Repository / Repozitorij:

[Dr Med - University of Zagreb School of Medicine Digital Repository](#)





## Središnja medicinska knjižnica

**Pavliša G., Ozretić D., Murselović T., Pavliša G., Radoš M. (2010) *Sole stenting of large and giant intracranial aneurysms with self-expanding intracranial stents-limits and complications. Acta Neurochirurgica, 152 (5). pp. 763-9. ISSN 0001-6268***

<http://www.springer.com/journal/701>

<http://www.springerlink.com/content/0001-6268>

<http://dx.doi.org/10.1007/s00701-009-0592-y>

<http://medlib.mef.hr/1408>

University of Zagreb Medical School Repository

<http://medlib.mef.hr/>

Sole stenting of large and giant intracranial aneurysms with self-expanding intracranial stents – limits and complications

Goran Pavlisa<sup>1</sup>, David Ozretic<sup>1</sup>, Tamara Murselovic<sup>2</sup>, Gordana Pavlisa<sup>3</sup>, Marko Rados<sup>1</sup>

<sup>1</sup>Clinical institute of diagnostic and interventional radiology, University hospital center Zagreb, Kispaticeva 12, 10000 Zagreb, Croatia

<sup>2</sup>Clinic of anesthesiology, reanimatology and intensive care, University hospital center Zagreb, Kispaticeva 12, 10000 Zagreb, Croatia

<sup>3</sup>Special hospital for pulmonary diseases, Rockefellerova 3, 10000 Zagreb, Croatia

Corresponding author

Goran Pavlisa, MD, PhD

Clinical institute of diagnostic and interventional radiology, University hospital center Zagreb

Kispaticeva 12, 10000 Zagreb

Croatia

e-mail: [gpavlisa@net.amis.hr](mailto:gpavlisa@net.amis.hr)

[phone: 0038512388118](tel:0038512388118)

[fax: 0038512388250](tel:0038512388250)

## ABSTRACT

### Background

Intracranial aneurysms may be difficult for endovascular treatment due to size, fusiform shape or wide neck. In such patients, intracranial stents are used to support the coils in the aneurysm sac, or they may be used as a sole stenting technique to divert the blood flow without coils. The aim of this paper is to contribute to the existing data by reviewing the risks of sole stenting of large and giant aneurysms.

### Methods

We treated 7 patients with 9 aneurysms by self-expanding intracranial stents, either by a single or multiple stents in a stent-in-stent configuration. The follow-up was performed by digital subtraction angiography, with a mean follow-up time of 6 months.

### Results

A positive response to stenting occurred in 5 out of 7 patients (71%), and 6 out of 9 aneurysms (67%). The aneurysms were occluded in 2 patients, and incomplete results were noted in 3 patients. The symptoms due to the compression of cranial nerves resolved in 4 patients (57%). Procedure-related subarachnoid hemorrhage occurred in 2 out of 7 patients (29%), with death of one patient as a result of hemorrhage (14%).

### Conclusions

Sole stenting of large and giant aneurysms with self-expanding intracranial stents may be associated with a higher risk than previously reported. The effect of stenting on intraaneurysmal flow in such aneurysms, even after the placement of multiple overlapping stents, seems to be unpredictable.

Keywords: Intracranial aneurysm; sole stenting; self-expanding stent; large and giant aneurysms.

## INTRODUCTION

Endovascular options in the treatment of intracranial aneurysms are expanding by the recent advances of materials and techniques. Aneurysms which are difficult for treatment due to wide neck, fusiform shape and incorporation of arterial branches are being treated by three-dimensional coils, balloon or stent-assisted coiling, parent artery occlusion, liquid embolics or combinations of these approaches [1,12,21,22,]. Various types of coronary and intracranial stents are used to support the coils in the aneurysm sac and/or to promote the thrombosis of the aneurysm and neointimal proliferation at the aneurysm neck by flow diversion. Stents may be used without coiling for the purpose of aneurysm thrombosis, in sole stenting technique, with favourable results [4,17,27,28,29,30,31,32], although serious complications have been described [15]. New devices in forms of stents with a high-density wire mesh are being investigated and used in daily practice, with a potentially good compromise between flow diversion and preservation of perforating arterial branches [13,19]. However, the publications concerning sole stenting include a relatively small number of patients with limited follow-up time.

We retrospectively analyzed our results on 7 patients with large and giant aneurysms treated by sole stenting with self-expanding intracranial stents. The aim of this paper was to contribute to the existing data and emphasise possible risks of this technique.

## METHODS AND MATERIALS

Indications for treatment were assessed for every patient by neuroradiologist performing endovascular treatment, vascular neurosurgeon and neurologist. The patients were referred to endovascular treatment due to the location of aneurysms on cavernous internal carotid artery (ICA) and basilar artery and their large and giant size, both of which factors are associated with higher surgical risks [9,25]. Extradural location of aneurysms and their wide neck or fusiform shape were considered suitable for sole stenting. All the patients were treated on a single-plane digital angiography system (Axiom Artis FA; Siemens AG, Erlangen, Germany), by self-expanding stents designed for intracranial vessels: Enterprise vascular reconstruction device (Codman Neurovascular, Warren, NJ), LEO Plus stent (Balt Extrusion, Montmorency, France) and Neuroform3 stent (Boston Scientific, Natick, MA). We aimed to use multiple closed-cell stents in a stent-in-stent configuration to achieve higher surface area coverage of the aneurysm neck. An open-cell Neuroform3 stent was placed in one patient, before the introduction of Enterprise and LEO stents in our practice. The choice between Enterprise and LEO stents was mostly influenced by their availability in our institution, as were the decisions to place a single stent in two patients. Pre-procedural dual antiplatelet medication consisted of 75 mg of clopidogrel daily and 100 mg of acetylsalicylic acid (ASA) daily during 3 days, or a loading dose of 300 mg of clopidogrel and 325 mg of ASA at least 4 hours before the procedure. The patients were heparinized during the procedure in order to double the baseline activated clotting time. The procedures were performed with patients in general anesthesia.

After the treatment, dual antiplatelet regimen was maintained for 6 weeks, and 100 mg of ASA daily was administered lifelong.

The follow-up of patients with endovascularly treated aneurysms in our institution is routinely performed 3 months after the treatment by 3D time-of-flight magnetic resonance angiography, and 6-12 months after the treatment by digital subtraction angiography (DSA). In patients treated by sole stenting, however, the follow-up was performed by DSA to avoid misinterpretation due to magnetic resonance signal from expected thrombus in the aneurysm and artifacts caused by metallic stents. The follow-up examinations were performed after 3 months and in the period from 6-12 months after the treatment.

This paper has been written in accordance with ethical standards laid down by the declaration of Helsinki and after the appropriate insitutional clearance. All the patients gave their informed consent for enrollment in this retrospective research.

## RESULTS

Among 311 patients with intracranial aneurysms treated endovascularly in our institution from 2003 to 2009, 7 patients (6 female, 1 male) with large and giant aneurysms were treated by sole stenting. The mean age of the patients was 59 years, ranging from 43 to 81. Three patients had giant aneurysms, over 25 mm in diameter, while 4 patients had large aneurysms, measuring 10-25 mm. The mean size of large and giant aneurysms was 20 mm. One patient with a large cavernous ICA aneurysm had two additional small

aneurysms at C7 segment of the same artery, and stents covered the necks of all three aneurysms.

Demographic data, characteristics of the aneurysms, type and number of implanted stents and results of the treatment are provided in Table 1. The Enterprise stent is manufactured only in a diameter of 4.5 mm, so Table 1 provides only the lengths of implanted stents.

#### Table 1

All the patients were symptomatic with opthalmoplegia present in five patients, due to cranial nerve compression. One patient with a partially thrombosed basilar trunk aneurysm (Patient 3) presented with right-sided hemiparesis caused by brainstem ischemia. One patient had impaired consciousness, paresis of tongue and palate and progressive tetraparesis due to brainstem compression by the giant basilar artery aneurysm.

A total of 16 intracranial stents were deployed, the majority of which were closed-cell stents: 12 Enterprise stents and 3 LEO stents, while one stent was an open-cell Neuroform3 stent. 5 patients were treated by multiple stents, and 2 patients received a single stent.

#### Immediate results

There were no immediate complete angiographic exclusions of the aneurysms from circulation. Immediate partial result, seen angiographically as partial exclusion of the aneurysm from circulation or slower intraaneurysmal flow, occurred in 5 patients, while in 2 patients there were no immediate results.

#### Follow-up



Angiographic follow-up ranged from 3 months to 1 year, with a mean follow-up time of 6 months. At follow-up, the aneurysms were completely thrombosed in 2 patients and incomplete results were noted in 3 patients, for a total of 5 patients or 71%. This positive response to stenting occurred in 6 out of 9 aneurysms (56%): 5 large and giant aneurysms and 1 small aneurysm in a patient with multiple aneurysms. In one patient there was no change in aneurysm size and morphology after one year. Two patients with previously unruptured aneurysms suffered subarachnoid hemorrhage on the second and third day after the treatment, respectively. One of these patients died 3 days after the treatment and the death was considered procedure-related.

The overall complication rate was 29% (2/7 patients), which included SAH in one patient and SAH and ischemia in the other patient. The procedure-related mortality was 14% (1/7 patients).

The symptoms due to the compression of surrounding structures, mainly cranial nerves, resolved in 4 patients (57%) with ICA aneurysms: in one patient with a complete occlusion of the aneurysm, in two patients with partial results and in one patient with no angiographic result.

One patient with an immediate partial result had no further angiographic improvement after 6 months and was treated by additional coiling. One patient that had no angiographic result 1 year after sole stenting remained in follow-up without further treatment, since her symptoms due to extradural ICA aneurysm were gradually resolving.

Illustrative cases

## Patient 2

A 51-year old man was hospitalized for a planned treatment of an unruptured giant basilar trunk aneurysm. Patient had altered consciousness with somnolence progressing to stupor during weeks before the treatment, paresis of tongue and palate and progressive tetraparesis due to brainstem compression by the giant basilar artery aneurysm.

Angiography preceding the implantation of stent was performed by double injection of the contrast agent in both vertebral arteries to precisely evaluate the aneurysm, since there was no adequate visualization of basilar artery itself in previous examination. The aneurysm was arising at the level of anterior inferior cerebellar arteries, with slow and diminished distal flow, which was visible only after an injection through a microcatheter (Prowler select plus, 0,021, Codman Neurovascular, Warren, NJ) (Figure 2a,b). Three Enterprise stents (two stents 4,5 mm x 37 mm, one stent 4,5 mm x 28 mm) were implanted in a stent-in-stent configuration across the aneurysm neck with a marked reduction of flow in the aneurysm and improvement of distal flow (Figure 2c,d). The patient has been kept on dual antiplatelet regimen after the procedure, and experienced significant improvement of his clinical condition, until on the third day after the treatment he lost consciousness. Computed tomography (CT) scan revealed diffuse subarachnoid and intraventricular hemorrhage with brain edema, and the patient died. Retrograde analysis of angiographic images led to a conclusion that the site of rupture may have been at the distal part of the aneurysm, near the neck, probably due to the

redistribution of blood inflow (Figure 2d). Contrast retention in the aneurysm may have been associated with reduced blood outflow.

#### Patient 6

A 54-year old female patient presented with left retroorbital pain and diplopia of the left eye. She had prominent palsy of the left abducens nerve. CT and CT angiography disclosed a large unruptured aneurysm of the C7 segment of the left ICA and she was referred to endovascular treatment. After dual antiplatelet preparation, the neck of the aneurysm was bridged by 4 closed-cell stents in a stent-in-stent configuration, with immediate slowing of the blood flow in the aneurysm with narrower inflow and improved distal flow (Figure 3a,b). There were no intraprocedural complications, and the patient was kept on dual antiplatelet medications. 24 hours after the procedure, she developed sudden right hemiparesis and lost consciousness. CT scan revealed acute subarachnoid hemorrhage and an acute ischemia in the left anterior and middle cerebral artery territory (Figure 3c,d). At MR angiography there was no flow in the left terminal ICA, the aneurysm and left MCA. The patient gradually stabilized and was transferred to a rehabilitation centre.

Figure 2

#### DISCUSSION

Sole stenting was reported for the first time as an ancillary method to stent-assisted coiling [14,18], and is recently receiving attention as a planned definitive method of treatment of intracranial aneurysms. This method is appealing since modern intracranial stents are easily deployed, even in a stent-in-stent fashion, with low risk for vessel injury and short procedure times. Furthermore, thromboembolic events seem to be less frequent in patients who undergo stent-assisted coiling than in those treated by coiling alone, probably attributed to antiplatelet medications, accentuating the safety of stenting [6]. In comparison with coiling, which aims to fill the aneurysmal sac, stenting has the theoretical advantage of treating the diseased segment of the parent artery wall where the aneurysm arises. Published results are mostly in favor of this technique, although the rate of complications may reach up to 10% [8,17,32].

We retrospectively analyzed our results on 7 patients treated by stenting. These results are poor, with complete occlusion of aneurysms in 2 patients at the mean follow-up time of 6 months, which may not be the sufficient follow-up time for the full effect of stent to occur [3].

#### Hemorrhagic complications

Aneurysms in two patients ruptured within 3 days of the procedure and one patient died as a result of treatment. These results may be partially due to the fact that the patients had large and giant symptomatic aneurysms with wide neck or fusiform in shape, which are difficult for any type of treatment. Nevertheless, the rupture of 2 out of 7 treated large and giant aneurysms within days of the procedure represents a high bleeding rate of 29% which was unexpected, especially having in mind that these two aneurysms were treated

by 3 and 4 overlapping stents, respectively. This was expected to result in a higher surface area coverage of the orifice of the aneurysm, providing additional security against rupture. The pathogenesis of rupture of these aneurysms after treatment is not entirely clear. Both procedures were uneventful, with short procedure times and with standard pre- and postprocedural antiplatelet regimen, which is accepted by most authors. After the procedures, the patients were monitored in neurological intensive care units, with no adverse events noted. In these two patients, we speculate that the causes of rupture may have been a changed direction and narrowing of blood inflow, since the computational dynamics of in-vivo intraaneurysmal flow showed that ruptured aneurysms may have a changing region of impingement as well as narrower inflow jets, compared to unruptured ones [7]. The sizes of aneurysms in these two patients were 31 mm and 20 mm, respectively. Such size inevitably stretches the wall of the aneurysm, making it thin and inflexible. Therefore it is more vulnerable to rupture by the suddenly narrowed inflow jet of blood, which is directed to a different part of the aneurysm as a result of stents at the orifice of the aneurysm. In both patients, at final angiograms at the end of the procedure, the inflow jets were oriented slightly more distally at the upper portions of the aneurysms, compared to pre-treatment angiograms, supporting this hypothesis. The other factor which we should consider is the outflow from the aneurysm, which is most probably reduced as well, and may be seen angiographically as the retention of contrast in the aneurysm. Although it suggests slowing of the intraaneurysmal blood flow which promotes thrombosis, it may be dangerous if combined with persistent and narrower inflow jet. The subsequent rise of intraaneurysmal pressure may result in

rupture [32]. Although some authors report similar complications [15], the overall rate of SAH after sole stenting is low, up to 2.1 % [10,11,32]. These reports focused on the treatment of small aneurysms, in contrast to those in our patients, which may be the cause of significantly higher rate of post-treatment aneurysm rupture in our series.

In patient 6, there were signs of bleeding as well as a large ischemic infarction. We speculate that the aneurysm ruptured and subsequently the formation of thrombus occluded both the aneurysm and the parent artery, causing ischemia.

#### Antiplatelet medication and risk of hemorrhage

Stenting is proposed to promote aneurysm thrombosis by redistribution of flow away from the aneurysm, by bridging of the diseased vessel wall at the aneurysm neck and by the change of arterial angle. At the same time, porosity of the stent preserves perforating arteries. The process of aneurysm thrombosis is, however, hampered by the necessity of antiplatelet medications, which may be an inherent problem of the technique.

We excluded the patients who had previous subarachnoid hemorrhage due to the need of pre- and postprocedural antiplatelet therapy, although there is growing body of data indicating that the risk of rebleeding after stenting of acutely ruptured aneurysms is very low [11,20,24,26,32]. However, these studies varied regarding the timing and the type of antiplatelet medication, using intraprocedural abciximab and postprocedural ASA and clopidogrel therapy [11]; ticlopidine postprocedurally [20]; or intraprocedural tirofiban and ASA and clopidogrel after the treatment [32]. We avoid stenting in the setting of acute SAH whenever possible, since there are no clear guidelines regarding antiplatelet

therapy, and the number of reported patients treated by this method is still relatively small.

#### Design and number of stents

We treated all the patients with dedicated intracranial stents, mostly of a closed-cell type. These stents are, however, designed primarily for a purpose of stent-assisted coiling, not for the reconstruction of blood flow in the parent artery. Other devices, such as balloon-expandable coronary stents, are more rigidly structured and may provide additional change of arterial angle with more accentuated flow redistribution [32]. Such stents also have up to three times higher surface area coverage than self-expanding stents. This may contribute to a higher degree of aneurysm occlusion [30,31]. On the other hand, both aneurysms that ruptured after stenting in our series were bridged by multiple stents, which probably provided a comparable or even higher surface area coverage and rigidity compared to balloon expanding stents. This density of mesh across the aneurysm neck may, however, only be assumed, since there is no possibility of actual visualization of overlapping stent struts during flouroscopy.

It may be difficult to decide how many intracranial stents should be applied across the neck of the aneurysm to adequately redistribute the flow. Double-stenting method has been suggested as more efficient [5,16,24], and we aimed to place multiple stents in our patients. The drawback of such treatment is virtually impossible microcatheterization of the aneurysm in case of recanalization or regrowth.

Our study is limited by a small number of patients and a heterogeneity regarding the type of stents we used. Longer follow-up of the patients may be necessary.

In conclusion, this limited series suggests that the results of sole stenting in the endovascular treatment of large and giant aneurysms may be unpredictable with the possibility of severe complications. The use of coronary stents in the management of small wide-necked aneurysms may bring more satisfying results.

The authors declare to have no conflict of interest.



## ACKNOWLEDGEMENTS:

We thank Marko Kralik, M.D. for his help in the technical preparation of the manuscript.

## REFERENCES

1. Ahn JY, Han IB, Kim TG, Yoon PH, Lee YJ, Lee BH, Seo SH, Kim DI, Hong CK, Joo JY (2006) Endovascular treatment of intracranial vertebral artery dissections with stent placement or stent-assisted coiling. *AJNR Am J Neuroradiol* 27:1514-152
2. Albanese E, Russo A, Ulm AJ (2009) Fenestrated vertebrobasilar junction aneurysm: diagnostic and therapeutic considerations. *J Neurosurg* 110:525-529
3. Aziz-Sultan A, Heros RC (2008) Sole stenting. *J Neurosurg* 108:1101-1103
4. Benitez RP, Silva MT, Klem J, Veznedaroglu E, Rosenwasser RH (2004) Endovascular occlusion of wide-necked aneurysms with a new intracranial microstent (Neuroform) and detachable coils. *Neurosurgery* 54:1359-1368
5. Benndorf G, Herbon U, Sollmann WP, Campi A (2001) Treatment of a ruptured dissecting vertebral artery aneurysm with double stent placement: case report. *AJNR Am J Neuroradiol* 22:1844-1848

6. Brooks NP, Turk AS, Niemann DB, Aagaard-Kienitz B, Pulfer K, Cook T (2008) Frequency of thromboembolic events associated with endovascular aneurysm treatment: retrospective case series. *J Neurosurg* 108:1095-1100
  
7. Cebral JR, Castro MA, Burgess JE, Pergolizzi RS, Sheridan MJ, Putman CM (2005) Characterization of cerebral aneurysms for assessing risk of rupture by using patient-specific computational hemodynamics models. *AJNR Am J Neuroradiol* 26:2550-2559
  
8. Crowley RW, Evans AJ, Kassell NF, Jensen ME, Dumont AS (2009) Endovascular treatment of a fusiform basilar artery aneurysm using multiple "in-stent stents". *J Neurosurg Pediatr* 3:496-500
  
9. Diaz FG, Ohaegbulam S, Dujovny M, Ausman JI (1998) Surgical management of aneurysms in the cavernous sinus. *Acta Neurochir (Wien)* 91:25-28
  
10. Doerfler A, Wanke I, Egelhof T, Stolke D, Forsting M (2004) Double-stent method: therapeutic alternative for small wide-necked aneurysms. Technical note. *J Neurosurg* 100:150-154
  
11. Fiorella D, Albuquerque FC, Deshmukh VR, Woo HH, Rasmussen PA, Masaryk TJ, McDougall CG (2006) Endovascular reconstruction with the Neuroform stent as

monotherapy for the treatment of uncoilable intradural pseudoaneurysms. *Neurosurgery* 59:291-300

12. Fiorella D, Albuquerque FC, Masaryk TJ, Rasmussen PA, McDougall CG (2005) Balloon-in-stent technique for the constructive endovascular treatment of “ultra-wide necked” circumferential aneurysms. *Neurosurgery* 57:1218-1227

13. Fiorella D, Woo HH, Albuquerque FC, Nelson PK (2008) Definitive reconstruction of circumferential, fusiform intracranial aneurysms with the pipeline embolization device. *Neurosurgery* 62:1115-1121

14. Higashida RT, Smith W, Gress D, Urwin R, Dowd CF, Balousek PA, Halbach VV (1997) Intravascular stent and endovascular coil placement for a ruptured fusiform aneurysm of the basilar artery. Case report and review of the literature. *J Neurosurg* 87:944-949

15. Kaku Y, Yoshimura S, Yamakawa H, Sakai N (2003) Failure of stent-assisted endovascular treatment for ruptured dissecting aneurysms of the basilar artery. *Neuroradiology* 45:22-26

16. Kim M, Levy EI, Meng H, Hopkins LN (2007) Quantification of hemodynamic changes induced by virtual placement of multiple stents across a wide-necked basilar trunk aneurysm. *Neurosurgery* 61:1305-1313
  
17. Lubicz B, Collignon L, Lefranc F, Bruneau M, Brotchi J, Balériaux D, De Witte O (2008) Circumferential and fusiform intracranial aneurysms: reconstructive endovascular treatment with self-expandable stents. *Neuroradiology* 50:499-507
  
18. Lylyk P, Ceratto R, Hurvitz D, Basso A (1998) Treatment of a vertebral dissecting aneurysm with stents and coils: technical case report. *Neurosurgery* 43:385-388
  
19. Lylyk P, Miranda C, Ceratto R, Ferrario A, Scrivano E, Luna HR, Berez AL, Tran Q, Nelson PK, Fiorella D (2009) Curative endovascular reconstruction of cerebral aneurysms with the pipeline embolization device: the Buenos Aires experience. *Neurosurgery* 64:632-643
  
20. Manabe H (2008) Ruptured cerebral aneurysms treated by stent-assisted GDC embolization - two case reports with long-term follow-up. *Acta Neurochir Suppl* 103:5-8
  
21. Mehta B, Burke T, Kole M, Bydon A, Seyfried D, Malik G (2003) Stent-within-a-stent technique for the treatment of dissecting vertebral artery aneurysms. *AJNR Am J Neuroradiol* 24:1814-1818

22. Molyneux AJ, Cekirge SH, Saatci I, Gal G (2004) Cerebral aneurysm multicenter European Onyx (CAMEO) trial: results of a prospective observational study in 20 European centers. *AJNR Am J Neuroradiol* 25:39-51
23. Moret J, Cognard C, Weill A, Castaings L, Rey A (1997) Reconstruction technic in the treatment of wide-neck intracranial aneurysms. Long-term angiographic and clinical results. Apropos of 56 cases. *J Neuroradiol* 24:30-44
24. Park SI, Kim BM, Kim DI, Shin YS, Suh SH, Chung EC, Kim SY, Kim SH, Won YS (2009) Clinical and angiographic follow-up of stent-only therapy for acute intracranial vertebrobasilar dissecting aneurysms. *AJNR Am J Neuroradiol* 30:1351-1356
25. Raaymakers TW, Rinkel GJ, Limburg M, Algra A (1998) Mortality and morbidity of surgery for unruptured intracranial aneurysms: a meta-analysis. *Stroke* 29:1531-1538
26. Santos-Franco JA, Zenteno M, Lee A (2008) Dissecting aneurysms of the vertebrobasilar system. A comprehensive review on natural history and treatment options. *Neurosurg Rev* 31:131-140

27. Szikora I, Berentei Z, Kulcsar Z, Barath K, Berez A, Bose A, Nyary I (2006) Endovascular treatment of intracranial aneurysms with parent vessel reconstruction using balloon and self expandable stents. *Acta Neurochir (Wien)* 148:711-723
28. Vanninen R, Manninen H, Ronkainen A (2003) Broad-based intracranial aneurysms: thrombosis induced by stent placement. *AJNR Am J Neuroradiol* 24:263-266
29. Wakhloo AK, Mandell J, Gounis MJ, Brooks C, Linfante I, Winer J, Weaver JP (2008) Stent-assisted reconstructive endovascular repair of cranial fusiform atherosclerotic and dissecting aneurysms: long-term clinical and angiographic follow-up. *Stroke* 39:3288-3296
30. Zenteno MA, Modenesi Freitas JM, Aburto-Murrieta Y, Koppe G, Machado E, Lee A (2006) Balloon-expandable stenting with and without coiling for wide-neck and complex aneurysms. *Surg Neurol* 66:603-610
31. Zenteno MA, Murillo-Bonilla LM, Guinto G, Gomez CR, Martinez SR, Higuera-Calleja J, Lee A, Gomez-Llata S (2005) Sole stenting bypass for the treatment of vertebral artery aneurysms: technical case report. *Neurosurgery* 57: E208
32. Zenteno MA, Santos-Franco JA, Freitas-Modenesi JM, Gómez C, Murillo-Bonilla L, Aburto-Murrieta Y, Díaz-Romero R, Nathal E, Gómez-Llata S, Lee A (2008) Use of the

sole stenting technique for the management of aneurysms in the posterior circulation in a prospective series of 20 patients. J Neurosurg 108:1104-1118

**Table 1.** Summary of the results of patients treated by sole stenting

Patients, sex, age	Aneurysm characteristics				Complication	Stent type and size (mm)	Immediate result	Follow –up result
	Artery, segment	Size	Neck	Clinical Presentation				
1, f, 75 y	ICA, C4	26 mm	12 mm	ophtalmoplegia	none	Enterprise 28 Enterprise 22	partial	complete, 1y
2, m, 51 y	basilar trunk	31 mm	23 mm	impaired consciousness, cranial nerve palsy	3d SAH, death	Enterprise 37 Enterprise 28 Enterprise 28	partial	death, 3d
3, f, 48 y	basilar trunk	10 mm	5 mm	hemiparesis	none	Enterprise 22 Enterprise 22	partial	partial, coiled 6m
4, f, 81 y	ICA, C4	15 mm	fusiform	ophtalmoplegia	none	Neuroform3 4.5 x 30	none	none, 1y
5, f, 63 y	ICA, C4 + 2 small C7 aneurysms	14 mm, 2 mm, 3 mm	7 mm, 2 mm, 3 mm	ophtalmoplegia	none	Enterprise 37 Enterprise 37 LEO 3.5 x 25	partial	partial, 3m
6, f, 54 y	ICA, C7	20 mm	7 mm	ophtalmoplegia	2d SAH + ischemia	Enterprise 22 Enterprise 22 Enterprise 14 LEO 4.5 x 25	partial	complete PAO, 2d
7, f, 43 y	ICA, C4-C7	27 mm	10 mm	ophtalmoplegia	none	LEO 4.5 x 40	none	partial, 3m

m – male, f – female, ICA – internal carotid artery, SAH – subarachnoid hemorrhage,

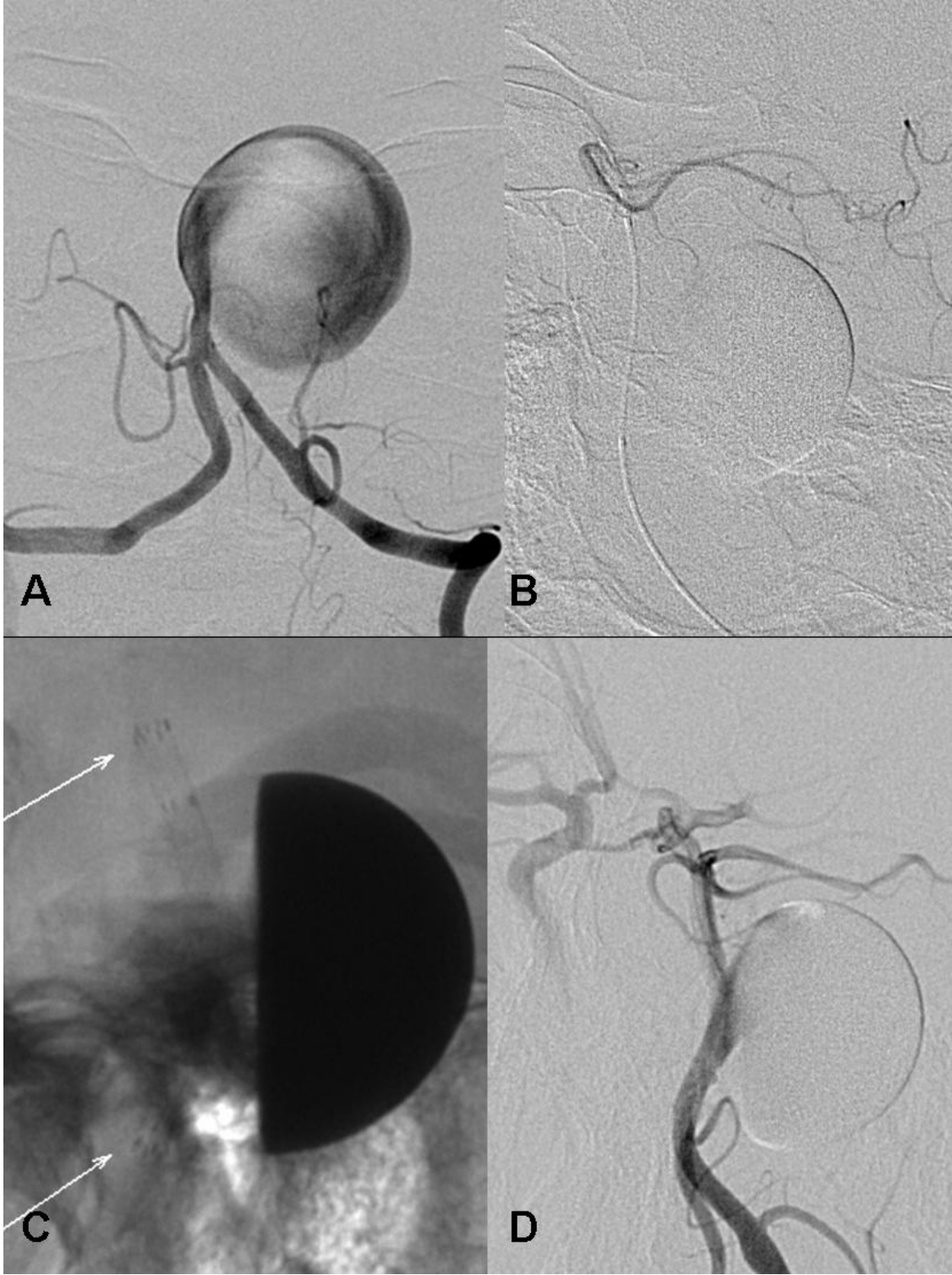
PAO – parent artery occlusion, y – year, m – month, d - day



## FIGURE LEGENDS

### **Figure 1**

2a,b: A giant basilar artery aneurysm shown by double vertebral artery injection with diminished distal flow, which is assessed by microcatheterization of basilar artery distal to the aneurysm. 2c: Unsubtracted image with contrast retention in the aneurysm after the placement of 3 stents; stents are depicted by arrows. 2d: Significant reduction of blood flow in the aneurysm with improvement of distal flow



**Figure 2**

3a: Digital angiography showing giant intradural ICA aneurysm. 3b: Slower filling of the aneurysm and improvement of distal arterial flow after the placement of 4 stents. 3c: axial CT image 24 hours after the treatment reveals subarachnoid hemorrhage. 3d: Loss of gray-white matter differentiation due to acute ischemia in the territory of left anterior and middle cerebral artery

