

Pre-B-cell acute lymphoblastic leukemia with bulk extramedullary disease and chromosome 22 (EWSR1) rearrangement masquerading as Ewing sarcoma

Jakovljević, Gordana; Nakić, Melita; Rogošić, Srđan; Kardum-Skelin, Ika; Mrsić-Davidović, Sanja; Zadro, Renata; Krušlin, Božo

Source / Izvornik: **Pediatric Blood & Cancer, 2010, 54, 606 - 609**

Journal article, Accepted version

Rad u časopisu, Završna verzija rukopisa prihvaćena za objavljivanje (postprint)

<https://doi.org/10.1002/pbc.22365>

Permanent link / Trajna poveznica: <https://um.nsk.hr/um:nbn:hr:105:056791>

Rights / Prava: [In copyright](#)/[Zaštićeno autorskim pravom.](#)

Download date / Datum preuzimanja: **2024-07-24**



Repository / Repozitorij:

[Dr Med - University of Zagreb School of Medicine](#)
[Digital Repository](#)





Središnja medicinska knjižnica

Jakovljević G., Nakić M., Rogošić S., Kardum-Skelin I., Mrsić-Davidović S., Zadro R., Krušlin B. (2010) *Pre-B-cell acute lymphoblastic leukemia with bulk extramedullary disease and chromosome 22 (EWSR1) rearrangement masquerading as Ewing sarcoma. Pediatric Blood & Cancer, 54 (4). pp. 606-9. ISSN 1545-5009*

<http://www.wiley.com/bw/journal.asp?ref=1545-5009>

<http://www.interscience.wiley.com/jpages/1545-5009>

<http://dx.doi.org/10.1002/pbc.22365>

<http://medlib.mef.hr/1410>

University of Zagreb Medical School Repository

<http://medlib.mef.hr/>

Pre-B Cell Acute Lymphoblastic Leukemia with Bulk Extramedullary Disease and Chromosome 22 (EWSR1) Rearrangement Masquerading as Ewing Sarcoma

Gordana Jakovljević, MD, MSc^{1*}, Melita Nakić, MD, PhD¹, Srđan Rogošić¹, Ika Kardum-Skelin, MD, PhD², Sanja Mrsić-Davidović, MD, PhD³, Renata Zadro, PhD³, Božo Krušlin, MD, PhD⁴

¹ Department of Hematology and Oncology, Pediatric Clinic, Children's Hospital Zagreb, Zagreb, Croatia

² Laboratory for Cytology and Hematology, Clinic of Internal Medicine, Merkur University Hospital, Zagreb, Croatia

³ Clinical Institute of Laboratory Diagnostics, Zagreb University Clinical Hospital Center and School of Medicine, Zagreb, Croatia

⁴ Ljudevit Jurak University Department of Pathology, Sestre milosrdnice University Hospital, Zagreb, Croatia

*Correspondence to: Gordana Jakovljević, MD, MSc, Department of Hematology and Oncology, Pediatric Clinic, Children's Hospital Zagreb, Klaićeva 16, 10000 Zagreb, Croatia. Phone +385914600152. Fax +385014826053. E-mail address: gordanajakovljevic@yahoo.com

Abstract word count: 93

Text word count: 1284

Figures count: 2

Tables count: 0

Short running title: ALL with EWSR1 rearrangement

Keywords: pre-B cell lymphoblastic lymphoma/leukemia, Ewing sarcoma family of tumors, t(11;22)(q24;q12), EWSR1 rearrangement

ABSTRACT

We report a 2-year-old female with a subcutaneous tumor who was initially misdiagnosed as suffering from Ewing sarcoma with a positive EWSR1 rearrangement and EWS/FLI1 transcript. After finding lymphoblasts in peripheral blood, the diagnosis of acute lymphoblastic leukemia was established. This necessitated further analysis of the subcutaneous tumor. The tissue was positive for immature B-cell markers and an immunoglobulin heavy chain gene rearrangement, which confirmed the final diagnosis of common type acute lymphoblastic leukemia with bulk extramedullary disease. The patient was treated with chemotherapy and was in remission 30 months after the diagnosis.

INTRODUCTION

The process of diagnosis of small blue round cell tumors (SBRCT) is a difficult task from both an oncological and pathological perspective. This group of neoplasms contains a considerable number of different tumors, which have similar histological features under light microscopy. Therefore, a great help in making this diagnosis and choosing the correct treatment has been the introduction of techniques such as immunohistochemistry and polymerase chain reaction (PCR) (1-3). Despite the great advances in technology, problems still exist with regards to differentiating between similar tumors from that group. This difficulty is evident in the differentiation of the Ewing sarcoma family of tumors (ESFT) from lymphoblastic lymphoma (LBL) (4,5).

Here, we report a patient with common type acute lymphoblastic leukemia (ALL), bulk extramedullary disease, a chromosome 22 (EWSR1) rearrangement and a positive EWS/FLI1 fusion transcript initially presented as a subcutaneous lymphoma masquerading as Ewing sarcoma (EWS).

CASE REPORT

The patient was a 2-year-old female, who was referred to our surgical department due to a subcutaneous mass in the left parietal region. The mass was not painful and her parents did not report any other abnormalities. There was no previous significant illnesses in her past medical history. The physical examination revealed that she was slightly underweight. There was no organomegaly, enlarged lymph nodes, or other abnormalities. The complete blood count (CBC) was normal at that time. There was no evidence of leukemic blasts or tumor cells in the peripheral blood smear.

Within a few days of presentation, the patient underwent a scheduled surgical excision of the parietal mass. The initial pathological findings of the resected tissue showed

that the tumor consisted of clusters of atypical small cells with hyperchromatic nuclei (Figure 1a). Immunohistochemistry of the tumor tissue demonstrated a positive reaction to the antigens for CD99 (Figure 1b), neuron specific enolase and synaptophysin, but the studies were negative for leukocyte common antigen (LCA). Reverse-transcriptase polymerase chain reaction (RT-PCR) analysis of the fresh pathological specimen was performed as previously described (6). It showed the existence of an EWS/FLI1 type 2 transcript, which is commonly associated with ESFT (Figure 1c) (3). A EWSR1 rearrangement from formalin-fixed paraffin-embedded tumor tissue was subsequently confirmed by fluorescence in situ hybridization (FISH) (7).

The patient was diagnosed with an extrasosseous EWS, and she was transferred to our oncology department. Upon admission, another CBC with a differential was performed. This showed white blood cells of $12.5 \times 10^9 /L$, a hemoglobin level of 10.3 g/dl and normal platelet values of $168 \times 10^9 /L$. Serum levels of lactate dehydrogenase and uric acid were found to be within the normal ranges. Malignant blasts (17%) were found in the peripheral blood smear. That finding, together with EWS staging requirements, necessitated a bone marrow examination. The bone marrow specimen was obtained from the sternum and morphologically showed no elements of EWS, but was infiltrated with 65% lymphoblasts (Figure 2a). These were positive for periodic acid-Schiff (PAS) and negative for peroxidase, acid phosphatase, and alpha-naphthylacetate esterase (ANAE). Flow cytometric immunophenotyping of the bone marrow material was positive for terminal deoxynucleotidyl transferase (TdT), CD10, CD19, CD34, cytoplasmic expression of CD79a (cCD79a) and HLA-DR, all of which was consistent with the diagnosis of common B cell precursor type ALL. Immunocytochemistry of the bone marrow specimen also confirmed CD10 positivity (Figure 2b). Furthermore, RT-PCR analysis of the bone marrow was performed as previously described (8). The results were negative for TEL/AML-1, BCR/ABL, ALL-1/AF-4 transcripts. Polymerase chain

reaction (PCR) analysis of the bone marrow for immunoglobulin heavy chain gene rearrangement (IgH-R) was carried out as described previously and was found to be positive (9). However, the bone marrow EWS/FLI1 transcript analysis was not performed by RT-PCR at that time due to the scarcity of the specimen; the positive result for the bone marrow EWSR1 rearrangement was confirmed by FISH (Figure 2c) (7).

The original diagnosis was challenged by these results, and further investigations of the excised tumor were deemed to be necessary. More detailed immunohistochemistry of the subcutaneous mass showed positivity for CD10, CD34, CD79a, CD99, TdT and PAX5. CD20 antigen, a common marker in B cell lymphomas was negative. We also found a high positivity for the Fli1 protein, which is uncommon in lymphomas, although it has been reported (2). PCR analysis for IgH-R within the subcutaneous tumor was also positive and showed an identical rearrangement to the type that had been found in the analysis of the bone marrow (9). The final results indicated that the subcutaneous tumor mass was in fact a bulk extramedullary disease as a part of ALL, with a positive EWSR1 rearrangement, expression of a EWS/FLI1 fusion transcript and of the FLI1 protein.

The patient was treated with chemotherapy according to the ALL IC-BFM 2002 protocol. She went into complete remission on the 33rd day of therapy. Thirty months later and after regular follow-up visits to the oncology clinic, the patient shows no signs of her previous illness.

DISCUSSION

The distinction between ESFT and LBL with extramedullary disease can be difficult and a limited panel of antibodies can lead to an erroneous diagnosis. The main problems in diagnosis have been the histological features and the presence of the CD99 antigen, which has been reported to be positive in both malignancies (1,4). Employing additional tumor-specific

markers may be helpful, but the most reliable method is detection of the t(11;22)(q24;q12) translocation and expression of EWS/FLI1 transcripts (10). Positivity for the FLI1 protein could indicate the existence of the fusion gene since FLI1 protein has been shown to have increased expression in most cases with the proven presence of the EWS/FLI1 translocation (2, 11). Rare cases have demonstrated that both ESFT and lymphomas can have positivity for the CD99 and FLI1 proteins (2). Therefore, the presence of the EWS/FLI1 transcript itself as a result of t(11;22)(q24;q12) seems to be important for differential diagnosis. Approximately 85% of all ESFT cases have been found to be positive for this transcript (12). RT-PCR and FISH are the most reliable methods to prove the existence of such a translocation. However, it is important to note that a translocation involving the EWSR1 gene detected by the FISH method supports a diagnosis of ESFT, but does not prove it. Other solid tumors, such as desmoplastic small round cell tumors, clear cell sarcoma, and extraskeletal myxoid liposarcoma, may demonstrate the rearrangement of EWSR1 (13).

The same genetic rearrangement can be present across malignancies of different phenotypes. The presence of BCR/ABL in chronic myeloid leukemia (CML) and ALL is the most classic example. EWSR1 and ETS (FLI1, ERG) rearrangements associated with ESFT have also been described in hematopoietic malignancies (14,15). One case of acute myeloid leukemia (AML) with t(11;22)(q24;q12) and a case of granulocytic sarcoma masquerading as EWS have been reported (16,17). Also, one case of concomitant EWS and ALL (18), as well as the case of EWS as second malignant neoplasm after ALL, have been described (19).

The present case, which demonstrated both positive EWSR1 gene rearrangement and a EWS/FLI1 fusion transcript, suggests that even a confirmation of the EWS/FLI1 transcript should not exclude the possibility of a lymphatic origin of the tumor. It is important to know that the identification of genetic rearrangements associated with specific solid tumors, leukemias or types of lymphoma, and their use as potential tools in the differential diagnosis

of these neoplasms, should not be confused with the fact that the diagnosis of any malignancy has to be made carefully by integrating all of the diagnostic components. Histopathology, immunophenotyping and genetic analysis must all be integrated within the final diagnosis and correlated with the clinical data. Therefore, no single marker should be utilized to finalize the diagnosis of any malignancy.

Conflict of Interest Statement

The authors have no conflicts of interest to declare.

References

1. Lucas DR, Bentley G, Dan ME, et al. Ewing sarcoma vs. lymphoblastic lymphoma. A comparative immunohistochemical study. *Am J Clin Pathol* 2001;115:11-17.
2. Folpe AL, Hill CE, Parham DM, et al. Immunohistochemical detection of FLI-1 protein expression: a study of 132 round cell tumors with emphasis on CD99-positive mimics of Ewing's sarcoma/primitive neuroectodermal tumor. *Am J Surg Pathol* 2000;24:1657-1662.
3. Jambhekar NA, Bagwan IN, Ghule P, et al. Comparative Analysis of Routine Histology, Immunohistochemistry, Reverse Transcriptase Polymerase Chain Reaction, and Fluorescence In Situ Hybridization in Diagnosis of Ewing Family of Tumors. *Arch Pathol Lab Med* 2006;131:1813-1818.
4. Ozdemirli M, Fanburg-Smith JC, Hartmann DP, et al. Precursor B-Lymphoblastic lymphoma presenting as a solitary bone tumor and mimicking Ewing's sarcoma: a report of four cases and review of literature. *Am J Surg Pathol* 1998;22:795-804.
5. Ozdemirli M, Fanburg-Smith JC, Hartmann DP, et al. Differentiating lymphoblastic lymphoma and Ewing's sarcoma: lymphocyte markers and gene rearrangement. *Mod Pathol* 2001;14:1175-1182.
6. Downing JR, Head DR, Parham DM, et al. Detection of the (11;22)(q24;q12) Translocation of Ewing's Sarcoma and Peripheral Neuroectodermal Tumor by Reverse Transcription Polymerase Chain Reaction. *Am J Pathol* 1993;143:1294-1300.
7. Bridge RS, Rajaram V, Dehner LP, et al. Molecular diagnosis of Ewing sarcoma/primitive neuroectodermal tumor in routinely processed tissue: a comparison of two FISH strategies and RT-PCR in malignant round cell tumors. *Modern Pathology* 2006;19:1-8.
8. Harbott J, Viehmann S, Borkhardt A, et al. Incidence of TEL/AML1 fusion gene analyzed consecutively in children with acute lymphoblastic leukemia in relapse. *Blood* 1997;90:4933-4937.
9. van Dongen JJ, Langerak AW, Brüggemann M, et al. Design and standardization of PCR primers and protocols for detection of clonal immunoglobulin and T-cell receptor gene recombinations in suspect lymphoproliferations: Report of the BIOMED-2 Concerted Action BMH4-CT98-3936. *Leukemia* 2003;17:2257-2317.

10. Khoury JD. Ewing sarcoma family of tumors: a model for the new era of integrated laboratory diagnostics. *Expert Rev Mol Diagn* 2008;8:97-105.
11. Llombart-Bosch A, Navarro S. Immunohistochemical detection of EWS and FLI-1 proteins in Ewing sarcoma and primitive neuroectodermal tumors. Comparative analysis with CD99 (MIC-2) expression. *Appl Immunohistochem Mol Morphol* 2001;9:255-260.
12. Riggi N, Stamenkovic I. The biology of Ewing sarcoma. *Cancer Lett* 2007;254:1-10.
13. Gulley ML, Kaiser-Rogers KA. A Rational Approach to Genetic Testing for Sarcoma. *Diagn Mol Pathol* 2009;18:1-10.
14. Martini A, La Starza R, Janssen H, et al. Recurrent Rearrangement of the Ewing's Sarcoma Gene, EWSR1, or Its Homologue, TAF 15, with the Transcription Factor CIZ/NMP4 in Acute Leukemia. *Cancer Research* 2002;62:5408-5412.
15. Marcucci G, Baldus CD, Ruppert AS, et al. Overexpression of the ETS-Related Gene, ERG, Predicts a Worse Outcome in Acute Myeloid Leukemia. *J Clin Oncol* 2005;23:9234-9242.
16. Hawkins JM, Craig JM, Secker-Walker LM, et al. Ewing's sarcoma t(11;22) in a case of acute nonlymphocytic leukemia. *Cancer Genet Cytogenet* 1991;55:157-162.
17. Hareh KP, Joshi N, Gupta C, et al. Granulocytic sarcoma masquerading as Ewing's sarcoma: A diagnostic dilemma. *J Cancer Res Ther* 2008;4:137-139.
18. Masjosthusmann K, Bielack SS, Köhler G, et al. Concomitant Ewing Sarcoma and Acute Lymphoblastic Leukemia in a 5-Year-Old Girl. *Pediatr Blood Cancer* 2005;45:846-849.
19. Kim GE, Beach B, Gastier Foster JM, et al. Ewing sarcoma as a second malignant neoplasm after acute lymphoblastic leukemia. *Pediatr Blood Cancer* 2005;45:57-59.

Figures

Figure 1. Subcutaneous mass arising from the parietal region: **(a)** tumor tissue is composed of clusters of atypical, small blue cells with hyperchromatic nuclei, demonstrated by the hematoxylin-eosin stain (H&E)(x40); **(b)** tumor cells showing positive immunostaining for CD99 (Dako Cytomation), using the labeled streptavidin biotin (LSAB) method (x400); and **(c)** reverse-transcriptase polymerase chain reaction (RT-PCR) with the EWS/FLI1 type 2 transcript (**lane 1:** DNA Molecular Weight Marker VIII; **lane 2:** negative control for EWS/FLI1 transcript; **lane 3:** positive control for EWS/FLI1 type 2 transcript; **lane 4:** positive control for EWS/FLI1 type 1 transcript; **lane 5:** specimen positive for EWS/FLI1 type 2 transcript).

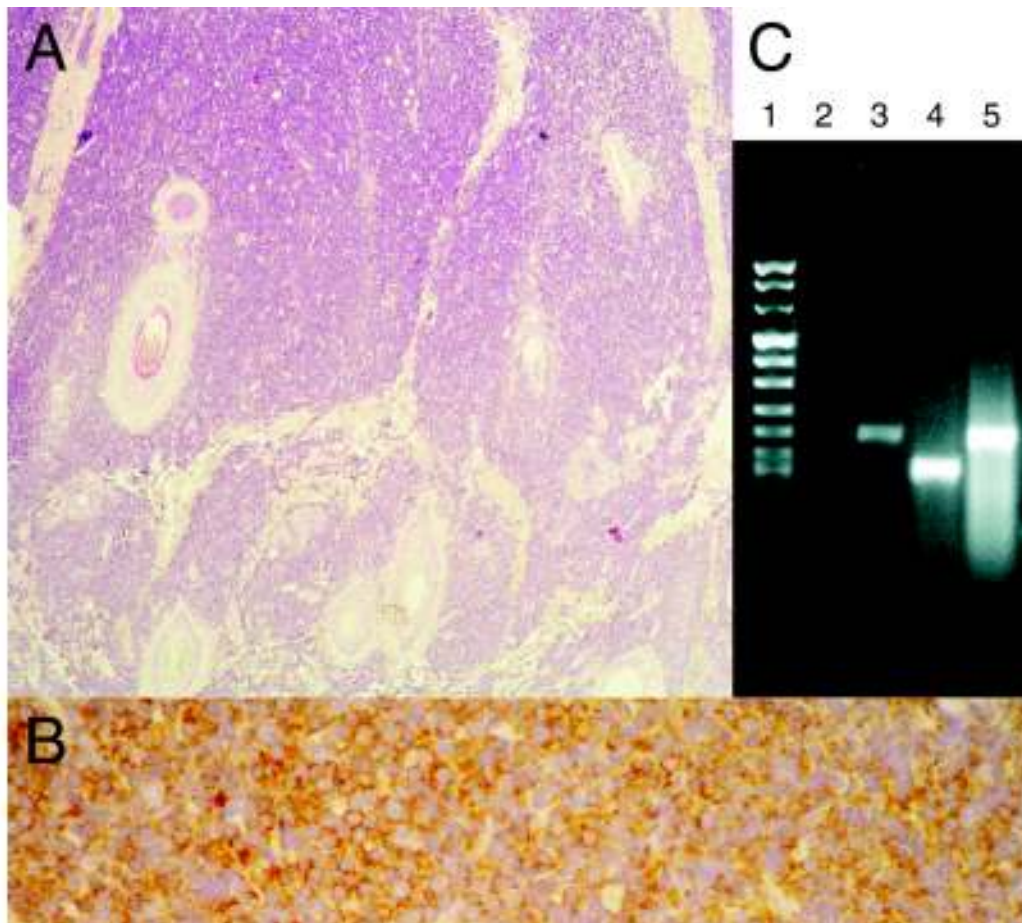


Figure 2. Bone marrow specimen (aspirate): **(a)** lymphoblasts, shown using the May-Grunwald-Giemsa staining technique (x1000); **(b)** positive immunocytochemical staining for CD10 (Dako Cytomation) (x1000); and **(c)** results of fluorescent in situ hybridisation (FISH) using a locus-specific fluorochrome labeled EWSR1 dual-color break-apart probe showing the t(11;22)(q24;q12) translocation in the bone marrow. Fusion of the red and green signal pattern is indicative of an intact copy of the EWS gene. A separated signal pattern of green (der(11)) and red (der(22)) demonstrates a rearrangement of the EWS gene.

