

# The role of the spectral domain ocular coherence tomography in detection of age-related macular degeneration

---

**Mrak, Bernard; Čaljkušić-Mance, Tea; Mrak, Bernarda; Cerovski, Branimir; Trobonjača, Zlatko**

*Source / Izvornik:* **Collegium antropologicum, 2011, 35, 157 - 60**

**Journal article, Published version**

**Rad u časopisu, Objavljena verzija rada (izdavačev PDF)**

*Permanent link / Trajna poveznica:* <https://urn.nsk.hr/urn:nbn:hr:105:156718>

*Rights / Prava:* [In copyright](#) / [Zaštićeno autorskim pravom.](#)

*Download date / Datum preuzimanja:* **2024-08-17**



*Repository / Repozitorij:*

[Dr Med - University of Zagreb School of Medicine  
Digital Repository](#)



# The Role of the Spectral Domain Ocular Coherence Tomography in Detection of Age-Related Macular Degeneration

Bernard Mrak<sup>1</sup>, Tea Čaljkušić-Mance<sup>1</sup>, Bernarda Mrak<sup>2</sup>, Branimir Cerovski<sup>3</sup> and Zlatko Trobonjača<sup>4</sup>

<sup>1</sup> Department of Ophthalmology, Rijeka University Hospital Center, University of Rijeka, Croatia

<sup>2</sup> University of Rijeka, School of Medicine, Rijeka, Croatia

<sup>3</sup> Department of Ophthalmology, Zagreb University Hospital Center, Zagreb, Croatia

<sup>4</sup> Department of Physiology and Immunology, University of Rijeka, School of Medicine, Rijeka, Croatia

## ABSTRACT

*Age-related macular degeneration (ARMD) is one of the most common causes of the vision loss and blindness in developed countries. Among other harmful effects, exposure to the UV radiation is the most prominent factor for the development of the disorder. Using the method of SD OCT (Spectral Domain Ocular Coherence Tomography) we performed measurement of the neurosensory retinal thickness of 19 eyes of low vision patients from the population of Primorsko-Goranska County of Republic of Croatia, with dry form of the terminal macular degeneration. These results we compared with control measurements performed on 28 eyes of healthy, normal vision subjects from same County. We determined following parameters: central foveal thickness (CFT), macular volume (MV) and mean foveal thickness (MFT) in the both groups. Results showed statistically significant reduction of CFT in the group of normal vision female patients when compared to males, while any significant difference of CFT between total groups of normal vision individuals and low vision patients was not detected. Furthermore, we noticed statistically significant ( $p < 0.000001$ ) decrease of the MV in the group of the low vision patients in comparison to healthy subjects and statistically significant ( $p < 0.000001$ ) reduction of the MFT of the low vision patients when compared to normal vision individuals. In our study we detected the absence of any significant difference of the CFT between healthy and low vision population, what looks like controversial finding, because neurosensory retina in the ARMD is thin and atrophic, but on the other side it is known that fixation point in low vision patients is translocated from the damaged fovea to extrafoveal region, usually above the fovea, where neurosensory retina is of the normal thickness, but with the less sensitivity. Furthermore, our results suggest possible connection of higher incidence of ARMD with lower CFT in females. Owing to the thicker neurosensory retina in males and better protection, damaging effect of the UV irradiation, which is the proven factor of ARMD development, is smaller. From the evolutionary point of view it is possible that males in all vertebrates have more resistant macula because during the evolutionary process they have spent much more time outside in the sunlight than females.*

**Key words:** dry form macular degeneration, SD OCT, non ionizing radiation, gender conditioned prevalence

## Introduction

Age-related macular degeneration (ARMD) is the most common cause of eyesight loss in the developed countries. UV radiation exposure is a substantial risk factor for the disease development<sup>1–3</sup> and it's significance is still growing because of the rising proportion of the elderly in the general population. Except UV radiation known ARMD risk factors are age over 50, gender (female predominance), family tendency, race (white predominance),

smoking (2–3 times more frequent), diet (fats–pelagic fish, Zn, omega 3 fatty acids are lowering incidence), high blood pressure and cholesterol as well as obesity and oxidative stress<sup>3</sup>.

There are several important symptoms of the ARMD which has two forms. »Dry form« is either asymptomatic or can be characterised by the gradual central sight loss and »wet form« which is characterized by much faster

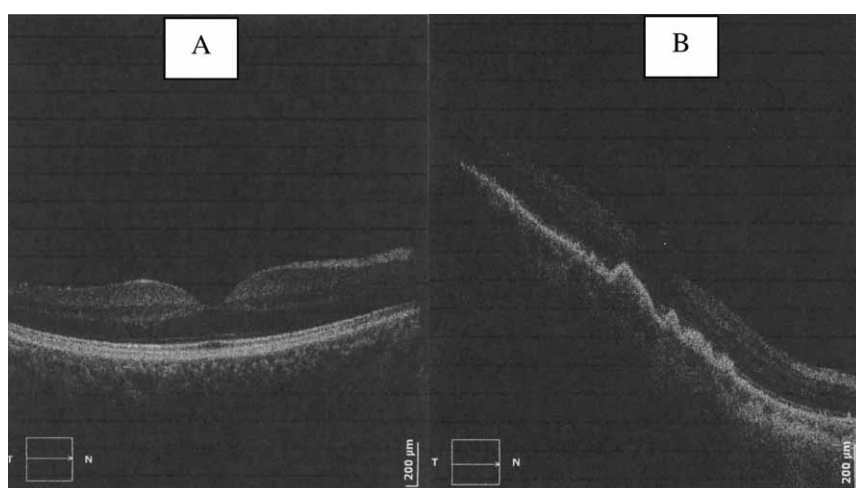


Fig. 1. SD OCT tomography of dry macula (a) and dry form ARMD (b).

onset of sight loss. Main symptom is blurred vision and other symptoms include: central scotoma (shadows or areas with vision loss), metamorphopsia (distorted vision), diminished colour vision, reduced possibility to distinguish bright from brighter and dark from darker forms, slower flash sight recovery rate and lower contrast sensitivity.

In our research, we investigated the dry form of the terminal phase of the ARDM which is characterized by accumulation of detritus between the neurosensory retina (NSR) and the base of the reticulopigmental epithelium zone (RPE). The separation of the NSR from the RPE is gradual and also includes NSR thinning<sup>4,5</sup>.

Spectral domain three-dimensional ocular coherent tomography (3D SD OCT) is a new, *in vivo*, imaging technique, which uses a sophisticated wave length reflexion of 840 nm to enable 3D tomography in visualizing various structures inside the eye. With the aid of SD OCT we can visualize the following: Retina (macula) which is scanned by light penetrating 2.2 mm in depth, optical disc with the retinal nerve fiber layer (RNFL) and the cornea with frontal segment of the eye. SD OCT enables *in vivo* insight into the pathogenesis and the progression of dry macular degeneration (Figure 1)<sup>6</sup>. Also, SD OCT is very useful in detection and monitoring of the wet form ARDM, which is characterized by a progressive eyesight loss as a result of the choroid angiogenesis and the fast separation of NSR from RPE. Modern treatment of wet form of ARDM includes Avastin, and a variety of anti-VGF medicaments.

## Patients and Methods

We divided our patients in two groups. The control group comprised of a healthy, normal vision population from Primorsko-Goranska County (28 eyes). The second group consisted of 19 visually impaired Primorsko-Goranska County patients that had dry form of terminal ARDM. The eye correction range of both target groups

was  $\pm 3.0$  dpt. Furthermore, the exclusion criteria in the visually impaired group were the absence of other retinal pathology, absence of cataract, absence of diabetes and the optimal eyesight of 0.3 or less. SD OCT anthropometric measurements and comparison of the neurosensory retina of the normal vision population and the visually impaired population of Primorsko-Goranska County has been conducted to the 3D SD OCT »Copernicus« imaging by »Optopol Technology«. The following data has been obtained from both groups: central foveal thickness (CFT), macular volume (MV) and the mean foveal thickness (MFT).

## Results

Investigation comprises of groups of healthy, normal vision individuals and low vision patients that differs in the average age of 52.04 and 76,6 years, respectively. Average spherical correction value of control subjects and low vision patients was 0.48 and 0.82 dioptre, respectively. Analysis of central foveal thickness (CFT) revealed difference between male and female patients. Mean male CFT was 223.625  $\mu\text{m}$ , while females had statistically significant lower CFT of 206.45  $\mu\text{m}$  that gave difference of 17.175  $\mu\text{m}$  or 8.32% (Table 1). On the other hand, we didn't find any significant difference of CFT between normal vision individuals (211.357  $\mu\text{m}$ ) and low vision patients (207.263  $\mu\text{m}$ ) (Table 2). Furthermore, we compared macular volume (MV) of two experimental groups and notice statistically significant ( $p < 0.000001$ ) reduction of the MV in the group of the 19 low vision patients (average MV was 10.299  $\text{mm}^3$ ) in comparison to 28 healthy subjects that had average MV of 11.74  $\text{mm}^3$ . Average reduction was 1.441  $\text{mm}^3$  or 11.18% (Table 3). Measurement of the mean foveal thickness (MFT) in the groups of the normal and low vision subjects revealed statistically significant ( $p < 0.000001$ ) reduction of the MFT in the group of the low vision patients (average MFT was 210.157  $\mu\text{m}$ ) in comparison to normal vision in-

**TABLE 1**  
NORMAL VISION FEMALES HAS STATISTICALLY SIGNIFICANT LOWER CFT THAN MALES

Variable	$\bar{X}$ Males	$\bar{X}$ Females	t-value	df	p	Valid N of Males	Valid N of Females	SD Males	SD Females
CFT	223,625	206,45	2,345	26	0,027	8	20	23,838	14,489

CFT – central foveal thickness

**TABLE 2**  
NO DIFFERENCE OF CFT BETWEEN NORMAL VISION SUBJECTS AND LOW VISION PATIENTS

Variable	$\bar{X}$ Normal vision subjects	$\bar{X}$ Low vision subjects	t-value	df	p	Valid N of Normal vision subjects	Valid N of Low vision subjects	SD Normal vision subjects	SD Low vision subjects
CFT	211,357	207,263	0,459	45	0,649	28	19	18,91	41,43

CFT – central foveal thickness

**TABLE 3**  
LOW VISION PATIENTS SHOWED STATISTICALLY SIGNIFICANT REDUCTION OF THE MV IN COMPARISON TO HEALTHY SUBJECTS

Variable	$\bar{X}$ Normal vision subjects	$\bar{X}$ Low vision subjects	t-value	df	p	Valid N of Normal vision subjects	Valid N of Low vision subjects	SD Normal vision subjects	SD Low vision subjects
MV	11,74	10,3	5,79	45	0,000001	28	19	0,62	1,08

MV – macular volume

**TABLE 4**  
LOW VISION PATIENTS SHOWED STATISTICALLY SIGNIFICANT REDUCTION OF THE MFT IN COMPARISON TO HEALTHY SUBJECTS

Variable	$\bar{X}$ Normal vision subjects	$\bar{X}$ Low vision subjects	t-value	df	p	Valid N of Normal vision subjects	Valid N of Low vision subjects	SD Normal vision subjects	SD Low vision subjects
MFT	239,18	210,16	5,7	45	0,000001	28	19	12,82	22,06

MFT – mean foveal thickness

dividuals (average MFT 239.178  $\mu\text{m}$ ). Difference of average MFT between two groups was 29.021  $\mu\text{m}$  or 12.13% (Table 4).

## Discussion and Conclusion

Our results show that, within the healthy group, population of males showed significantly thicker CFT in comparison to females. These results are consistent with similar studies showing the reduction of central subfield thickness in the women compared with the men, although authors found significant thinning in parafoveal regions in the women<sup>7</sup>.

Finding of the significantly lower CFT in the healthy women than men is of the strong importance allowing us to post original anthropological hypothesis, possibly applicable to other vertebrates, whose structure of the retina is inverse (i.e. the sensory epithelium is sited in the deepest layer of the retina, the light rays to reach the rods and cones must pass through the layers of nerve

cells and capillaries). This is the reason why we connected a greater prevalence of ARMD in women compared to men with a smaller CFT in the female population. Men's population, according to our hypothesis, thanks to thicker neurosensory retina, might have a greater biological shield against light, particularly UV radiation, which has been proven as a factor provoking the development of ARMD. This evolutionary theory may be connected with the ancient difference in the rhythm of the daily life – where man spent time mainly outside the home, in the sun, and women, on the other side, mostly within the home, protected from the sunlight exposure<sup>2,8</sup>. Central foveal (field) thickness in the visually impaired group with the dry form of ARMD does not differ from the CFT found in the healthy group, although we found strong difference in the macular volume and mean foveal (fixation zone) thickness between these groups. Paradoxical is statistically insignificant CFT difference between healthy group and low vision group, although it is well known that neurosensory retina becomes atrophic and thin in the form of dry ARMD, what is, on the other side,

confirmed by significant reduction of MV and MFT in low vision group. These results can be explained by the already well-known phenomenon of dislocation of damaged fixation point to extrafoveal region, usually above the fovea, in area with thicker neurosensory retina, but with a lower perceptual sensitivity. So, the new extra-

foveal fixation point in the low vision eye is taking the role of the damaged foveal zone, and enables further visual function<sup>9</sup>. These results have important implications for the use of SD-OCT in detecting the sex-associated differences in retinal structure between the man and woman as well as diagnosing retinal disease.

## REFERENCES

1. VOJNIKOVIĆ B, VOJNIKOVIĆ D, Coll Antropol, 34 (2010) 5. — 2. CALJKUSIĆ-MANCE T, KOVACEVIĆ D, NOVAK-STROLIGO M, ALPEZA-DUNATO Z, Coll Antropol, 34 (2010) 109. — 3. KELLIHER C, KENNY D, O'BRIEN C, Br J Ophthalmol, 90 (2006) 367. — 4. GODARA P, SIEBE C, RHA J, MICHAELIDES M, CAROLL J, Ophthalmic Surg Lasers Imaging, 41 (2010) 104. — 5. SCHMITZ-VALCKENBERG S, STEINBERG JS, FLECKENSTEIN M, VISVALINGAM S, BRINKMANN CK, HOLZ FG, Ophthalmology, 117 (2010) 1169. — 6. BRAR M, KOZAK I, CHENG L, BARTSCH DU, YUSON R, NIGAM N, OSTER SF, MOJANA F, FREEMAN WR, Am J Ophthalmol, 148 (2009) 439. — 7. WAGNER-SCHUMAN M, DUBIS AM, NORDGREN RN, LEI Y, ODELL D, CHIAO H, WEH E, FISCHER W, SULAI Y, DUBRA A, CARROLL J, Invest Ophthalmol Vis Sci, 52 (2011) 625. — 8. OOTO S, HANGAI M, SAKAMOTO A, TOMIDOKORO A, ARAIE M, OTANI T, KISHI S, MATSUSHITA K, MAEDA N, SHIRAKASHI M, ABE H, TAKEDA H, SUGIYAMA K, SAITO H, IWASE A, YOSHIMURA N, Invest Ophthalmol Vis Sci, 51 (2010) 465. — 9. AL-KARMI R, MARKOWITZ SN, Can J Ophthalmol, 41 (2006) 313.

*B. Mrak*

*Department of Ophthalmology, Rijeka University Hospital Center, University of Rijeka, Croatia  
e-mail: bernard.mrak2@ri.t-com.hr*

## ULOGA SPECTRAL DOMAIN OKULARNE KOHERENTNE TOMOGRAFIJE U DIJAGNOSTICI SENILNE DEGENERACIJE MAKULE

### SAŽETAK

Senilna degeneracija makule (SDM) je jedan od najčešćih uzroka gubitka vida i sljepoće u razvijenim zemljama, pri čemu je izloženost UV radijaciji značajan faktor rizika nastanka bolesti. Uz pomoć SD OCT (Spectral Domain okularna koherentna tomografija) aparata izvršeno je antropometrijsko mjerenje i usporedba debljine neurosenzorne retine u zdrave, normovidne populacije Primorsko Goranske Županije (PGŽ), te slabovidne populacije PGŽ i to sa suhom terminalnom formom SDM. Izmjerene su vrijednosti: centralne fiksacijske debljine (CFT), makularnog volumena (MV), te srednja fiksacijska debljina (MFT). Statistički neznčajna razlika CFT u zdrave i slabovidne skupine je podatak koji je paradoksalan, obzirom da znamo kako je u suhoj degeneraciji makule neurosenzorna retina atrofična, stanjena. Ove rezultate objašnjavamo već poznatim fenomenom dislokacije oštećene fiksacijske točke extrafoveolarno, i to iznad foveole, u područje s debljom neurosenzornom retinom, no s manjom perceptivnom osjetljivošću. Statistički značajno manja CFT u zdravih žena (206,45 mikr) u odnosu na zdrave muškarce (223,63) navodi na originalnu, antropološku hipotezu, primjenjivu i na sve kralježnjake da je moguća povezanost veće učestalosti SDM u žena s manjom CFT u žena. Muška bi populacija prema ovoj hipotezi, zahvaljujući debljoj neurosenzornoj retini mogla imati jači biološki štiti od svjetlosnih, osobito UV zračenja, koja su dokazano provocirajući faktor razvoja SDM. Evolucijsko gledano ova je teorija o povezanosti debljine makule i spolno nesrazmjerne učestalosti SDM poveziva s dnevnim životnim ritmom – uglavnom van doma, na suncu u muškaraca, te uglavnom unutar doma, zaštićeno od sunca u žena.