

# Electrocoagulation versus suture after laparoscopic stripping of ovarian endometriomas assessed by antral follicle count: preliminary results of randomized clinical trial

---

Ćorić, Mario; Barišić, Dubravko; Pavičić, Dinka; Karadža, Magdalena; Banović, Maja

Source / Izvornik: **Archives of Gynecology and Obstetrics, 2011, 283, 373 - 378**

Journal article, Accepted version

Rad u časopisu, Završna verzija rukopisa prihvaćena za objavljivanje (postprint)

<https://doi.org/10.1007/s00404-010-1676-x>

Permanent link / Trajna poveznica: <https://um.nsk.hr/um:nbn:hr:105:658915>

Rights / Prava: [In copyright](#) / [Zaštićeno autorskim pravom.](#)

Download date / Datum preuzimanja: **2024-08-30**



Repository / Repozitorij:

[Dr Med - University of Zagreb School of Medicine  
Digital Repository](#)





## Središnja medicinska knjižnica

**Ćorić M., Barišić D., Pavičić D., Karadža M., Banović M. (2011)**  
***Electrocoagulation versus suture after laparoscopic stripping of ovarian endometriomas assessed by antral follicle count: preliminary results of randomized clinical trial. Archives of Gynecology and Obstetrics, 283 (2). pp. 373-8. ISSN 0932-0067***

<http://www.springer.com/journal/404>

<http://www.springerlink.com/content/0932-0067>

<http://dx.doi.org/10.1007/s00404-010-1676-x>

<http://medlib.mef.hr/1639>

University of Zagreb Medical School Repository

<http://medlib.mef.hr/>

**Electrocoagulation versus suture after laparoscopic stripping of ovarian endometriomas assessed by antral follicle count; preliminary results of randomized clinical trial**

Mario Coric, Dubravko Barisic, Dinka Pavicic, Magdalena Karadza, Maja Banovic

Department of Gynecological Surgery, Zagreb University Hospital Center, Croatia

Mario Coric

Department of Gynecological Surgery, Zagreb University Hospital Center

Petrova 13, Zagreb 10 000, Croatia

e-mail: [mario.coric@zg.t-com.hr](mailto:mario.coric@zg.t-com.hr)

tel: 0038514604616

fax: 0038514633512

## **Abstract**

### *Purpose*

The assessment of ovarian reserve by antral follicle count (AFC) following electrocoagulation versus suture after laparoscopic stripping of ovarian endometriomas.

### *Methods*

Forty-five patients between 18 and 35 years, with unilateral endometriomas were randomly analyzed. Laparoscopic cystectomy was performed by the stripping method. Ovarian haemostasis was obtained either by suturing (group A, n = 23) or by bipolar electrocoagulation (group B, n = 22). AFC was performed by ultrasound on the third day of the three postoperative menstrual cycles. The sum of AFC was compared between sutured (A1) and electrocoagulated (B1) ovaries, as well as between intact ovaries of both groups (A0 – intact ovaries in sutured group; B0 – intact ovaries in electrocoagulated group).

### *Results*

The median of AFC was significantly lower in operated ovaries than in intact ovaries in both groups of patients, regardless of suturing (A1 median: 12 (range 9-19) versus A0 median: 21.0 (range 15-27),  $p < 0.05$ ) or electrocoagulation (B1:5.0 (2-10) vrs B0:18.5 (8-29)  $p < 0.05$ ). The median AFC was significantly higher in sutured ovaries than in electrocoagulated ovaries (A1:12 (9-19) vrs B1:5.0 (2-10),  $p < 0.05$ ).

### *Conclusion*

Our preliminary data show that operation on ovarian endometriomas could reduce ovarian reserve. The AFC value suggests that the ovarian reserve was less reduced in sutured ovaries than in those electrocoagulated. Suturing as a method of haemostasis could be a better choice after stripping ovarian endometriomas.

*Keywords:* ovarian reserve; endometrioma; antral follicle count; laparoscopy

## **Introduction**

There are many investigated hormonal, chemical and immunologic mechanisms by which endometriosis may affect reproductive function on the level of ovulation and oocyte quality, tubal and sperm function and fertilization and implantation, as well (1). In addition, the fertility of patients with endometriomas is seriously compromised due to decrease in the follicle ovarian reserve (FOR) even before any ovarian surgery (2), and due to distorted pelvic anatomy, as well (3). Laparoscopic excision of endometriomas by stripping off the pseudocapsule is the most common operative technique (4). The stripping technique is considered to be superior to fenestration and coagulation due to greater pain relief, less recurrence and higher pregnancy rates (5,6,7,8). This procedure however implies haemostatic bipolar coagulation of ovarian tissue which further diminishes FOR as evaluated by the postoperative serum FSH levels (9), postoperative ovarian volume (10) as well as results in assisted reproductive technology (ART) procedures (11), and additionally disturb patient's fertility. Haemostatic procedure after stripping of endometrioma could be one of the step in the procedure by which surgeon is in possibility to consciously save future reproductive function and patient's fertility. Fedele et al. however reported that suturing of an ovary after the endometrioma stripping was a tissue sparing technique of haemostasis as compared to bipolar coagulation (9). The study of Fedele et al. involved patients with previous ovariectomy with endometrioma in the residual ovary and they used the FSH level as the measure for FOR. Commonly used clinical test for ovarian reserve, antral follicle count (AFC), is in the best correlation with the true ovarian reserve as histological assessed by the ovarian primordial follicle number even after adjustment for chronological age (12).

Therefore we designed a prospective study to assess whether the laparoscopic suturing for haemostasis of the remaining ovarian tissue after the stripping of endometriomas had less adverse effect on the ovarian reserve compared to bipolar electrocoagulation. The postoperative ovarian reserve was assessed by the AFC.

## Patients and methods

### *Patients*

Fifty patients 21-35 years (mean 30.3 +/-4.4) with clinical and ultrasound diagnosis of unilateral ovarian endometriomas were included in the study from November 2008 to December 2009. The institutional Ethics Committee approved the study that was conducted at the Department of Obstetrics and Gynecology of Medical School of Zagreb University, according to the guidelines of the Declaration of Helsinki. Inclusion criteria were unilateral ovarian endometrioma confirmed by ultrasound examination in the great diameter of 30 mm or above, age between 18 and 35 years, regular menstrual bleeding (defined as cycle length less than 25 or more than 35 days), negative history of any previous gynecological surgical procedures and negative history of hormonal therapy (GnRH or OC) in the six month period before surgery. Exclusion criteria: pregnancy, active PID, genital or extragenital malignancy, combined PCO syndrome and endometriosis, intraoperative diagnosis of another cyst type present, any complication during operation or conversion to laparotomy, GnRH or OC therapy in the follow-up period, pregnancy and irregular attendance of follow up examinations.

Patients' analyzed characteristics were: age, time of first visit, presenting complaint, menstrual cycle, any previous surgery or disease as well as number of pregnancies and deliveries. All patients suspected of endometriosis underwent a clinical exam and ultrasound scan in the first part of the menstrual cycle.

All included patients were randomized in group A - ovarian haemostasis was obtained by suturing and group B - ovarian haemostasis was obtained by bipolar electrocoagulation (<http://www.randomizer.org>).

Statistical power analyses for the independent t-test were done (*G\*Power*: [www.pscho.uni-duesseldorf.de](http://www.pscho.uni-duesseldorf.de)). It calculated the minimal sample size of 119 patients (test power 0,95, sample size power 0,5, significance level  $\alpha$  0,05). These are preliminary results of the study until December 2009 and 50 patients were analyzed.

### *Technique*

All laparoscopies were performed in the first part of the menstrual cycle by two experienced surgeons (M.C and D.B) who had had the same endoscopic training and suturing skills. They also assisted each other on every operation. In the group A with unilateral endometriomas, haemostasis was achieved by ovarian suturing. These were marked as A1, while intact ovaries were marked as A0. In the group B haemostasis was achieved by bipolar electrocoagulation and the affected ovary was marked as B1 while intact ovaries were marked as B0. After the initial diagnostic evaluation of the pelvis and abdomen peritoneal washings for cytology were taken. If no sign of malignancy was present the ovary with endometrioma was mobilized from its usual adhesion to the ovarian fossa. All endometriotic cysts were removed by stripping the cyst wall. It was done by applying careful traction-countertraction technique over the edges of the cyst wall with two atraumatic grasping forceps (Storz). Sutured ovaries (A1 group) had one or two single polydioxanone sutures (2-0 Vicryl on a CT curved needle, Ethicon,

Edinburgh, UK) placed by Ethicon (E705R) needle holders to re-approximate the edges thus achieving satisfying haemostasis. The suture was performed with intraovarian knots and the knots were not detectable on the ovarian surface. Bleeding from ovarian hilus was resolved only by suturing, as well. There was no hematoma or any other complication related to suturing in all patients.

The cyst bed of ovaries marked as B1 was treated with careful desiccation of all bleeding sources using a bipolar Storz forceps by 25-30 W bipolar current.

#### *Follow-up and ultrasound*

Follow-up visits included three-dimensional (3D) vaginal ultrasound (GE Healthcare's Voluson® 730) examination performed by two independent examiners, blinded to the clinical and surgical history of patients. They had a good agreement in the follicle count measuring 2-10 mm on the third day of menstrual cycle. Visits were scheduled on the third day of the second, fourth and sixth regular menstrual cycle after the surgery. The AFC of both ovaries was determined and the sum of antral follicles of three cycles was noted. The pool of all primordial follicles in the remaining ovarian tissue was related to the number of growing antral follicles usually determined on day-3 of the menstrual cycle.

#### *Statistical analysis*

Data were analyzed using SPSS Version 16.0 (SPSS, Chicago, IL, USA). Distribution of numeric variables was analyzed by Smirnov-Kolmogorov test. One-Way ANOVA and  $\chi^2$  analysis were used to analyze differences in age, parous and size of endometriomas between group A and B. Independent t-test and Mann-Whitney U non-parametric test was applied to test differences between AFC inside groups and between groups and those variables are reported as median and ranges.  $P < 0.05$  was considered statistically significant.

## Results

Out of 50 patients five were excluded after randomization. In group A two patients (one became pregnant during follow up and in another patient endometrioma was not confirmed during operation). In group B three patients were excluded (one became pregnant, in another endometrioma was not confirmed during operation and there was an active PID in the third patient (Figure1). None of 45 patients escaped from the follow-up visits.

Age, parity and the size of endometriomas were comparable between both groups (Table 1).

The median of the sum of AFC in three postoperative cycles of operated ovaries in both groups was significantly lower than the median of the AFC of intact ovaries. In the group A sutured ovaries (A1) median was 12.0 (range 9-19) and in intact ovaries (A0) median was 21.0 (range 15-27);  $p < 0,05$  (Figure 2). In the group B in electrocoagulated ovaries (B1) median was 5.0 (range 2-10), while in intact ovaries (B0) median was 18.5 (range 8-29);  $p < 0,05$  (Figure 3). There was no significant difference between intact ovaries in group A (A0 - median was 21.0 range 15-27) and in group B (B0 - median was 18.5 range 8-29). However there was a significantly higher median of the AFC in ovaries that had been sutured (A1) than in ovaries that had been electrocoagulated (B1),  $p < 0,05$  (Figure 4).



## Discussion

Our study suggests that laparoscopic surgery of endometrioma could reduce ovarian reserve. Our preliminary data show that bipolar electrocoagulation after stripping of endometrioma during laparoscopy reduces ovarian reserve more than suturing. In addition, we observed significantly less sum of AFC during three postoperative cycles in electrocoagulated ovaries than in sutured ovaries. Furthermore, the sum of AFC in three cycles was also significantly lower in operated ovaries than in intact ovaries, whichever the haemostatic technique was used.

In the current study we used the antral follicle count (AFC) measured by transvaginal ultrasound for the assessment of the ovarian reserve after surgery. Antral follicles are defined as early follicles, 2-10 mm in size, imaged by transvaginal ultrasound on day 3 of menstrual cycle. They represent a cohort of follicles awaiting further recruitment and stimulation by gonadotropins (13). The AFC has been confirmed as a good predictor of ovarian response in *in vitro* fertilization (IVF) cycles (14). The lower AFC is associated with lower clinical pregnancy and live birth rates in unexplained subfertile couples treated with controlled ovarian hyperstimulation (15). All of these results and studies proved some predictive power of AFC in ART and provided only general approximations. But in the recent study Hansen et al (12) have demonstrated that AFC is reflective of the true ovarian reserve as histological assessed by the ovarian primordial follicle number. The correlation between the ovarian AFC with ovarian primordial follicle number remained significant even after adjustment for chronological age. In addition, AFC showed its better predictive power than pulsatility and resistance indexes in comparison of two laparoscopic management of endometriomas in the study of Pados et al (16).

Data on the use of the AFC in the assessment of the ovarian reserve after operation of endometriomas are scarce. In the current study two independent gynecologists, blinded to the clinical and surgical history of the patient, but had in good agreement by counting antral follicles, counted antral follicles on day-3 of the second, fourth and sixth regular menstruation cycle after surgery. There are some technical difficulties to count follicles in endometrioma consumed-ovary so we have not checked AFC before operation. We decided to count follicles in three cycles postoperatively and used the sum of AFC to diminish technical problem caused by tissue damage during surgery and by restitution process after electrocoagulation, as well. Other aim was to diminish the influence of the intercycle variability of the AFC (17) caused by well-known observer, but not biological, variability.

Few prospective randomized trials have been published and established laparoscopic excision with stripping as the optimal method of treatment of endometriomas from the aspects of recurrence, reoperation rate, pain relief and postoperative conception rate even regardless of the cyst size (5,7). Certain degree of ovarian tissue loss is related to removing of the pseudocapsule of endometriomas that is actually the ovarian tissue (6). The excised ovarian tissue adjacent to the endometrioma wall is morphologically different from the normal ovarian tissue and it never shows the normal follicular pattern that can be observed in normal

ovaries (6). But, the excised tissue near the ovarian hilus shows normal ovarian functional development (18). Taking into consideration that histological finding of Muzii et al we have performed careful surgical technique over the edges of the cyst wall with two atraumatic grasping forceps by special attention to the ovarian hilus. However, postoperative AFC data of operated and intact ovaries show significant functional reduction in operated ovaries, whichever the haemostatic technique was used. This finding cannot confirm whether the damage of residual ovarian tissue is caused by stripping or not and if the damage caused by stripping exists, how great it is. Nevertheless, Hachisuga and Kawarabayashi have indicated that even relative ease removal of the capsules is associated with loss of follicles and damage to the ovarian stroma (19).

Lemos et al. (2), measuring AMH level in patients with minimal and mild endometriosis, represented data that confirmed that follicular status and ovarian reserve were seriously compromised in patients with endometriosis even before any kind of surgery. Additionally, Benaglia et al suggested that severe ovarian damage, occurring in gonads operated on for ovarian endometriomas, is not a rare event (20). We are aware of advantages (5,6,7,8, 21) and possible disadvantages (18,19) of laparoscopic excision by stripping of the cyst wall as one of the preferred surgical approach in laparoscopy of endometriomas. There is also an „old“ three-stage technique of Donez et al (22) described in 1996 that became acceptable and showed its advantages over „classic“ laparoscopic stripping in the recent studies of Pados and Tsolakidis et al (16,23). But, in control group of both studies haemostasis was achieved with application of 30 W bipolar current. In the current study our intention was to make surgeons aware on the additional adverse effect that bipolar electrocoagulation may induce on the rest of healthy ovarian parenchyma. It was based on an original report by Fedele et al (9). The group focused on patients with previous history of unilateral ovariectomy and an endometrioma in the residual ovary. Due to very restrictive inclusion criteria the study had limited number of patients, but also showed advantages of suturing over electrocoagulation of ovaries by mean FSH level before and after surgery. The level of ovarian damage in our research was analyzed using the AFC. In the group to which haemostasis was achieved by suturing all bleeding even from ovarian hilus was resolved only by suturing. The suture might induce ischemic damage to the ovary, but there is no doubt that the thermal damage induced by bipolar electrocoagulation is by far more extensive and irreversible. In order to diminish the chance of postoperative adhesions we also tried to performed intraovarian knots in sutured ovaries. Pellicano et al investigated that that use of sutures on ovaries treated for endometrioma is associated with lower rate of postoperative ovarian adhesion formation compared with bipolar electrocoagulation (24).

Despite our preliminary results included less than 50% of minimal sample size, still relative value of results confirmed results of Fedele et al. that suturing of ovarian tissue and reconstruction of ovary following the stripping of endometrioma has had less adverse effect on ovarian reserve than bipolar electrocoagulation.

In conclusion, our preliminary results show that laparoscopic operation on ovarian endometrioma could reduce ovarian reserve. There is an additional adverse effect on the

ovarian reserve when bipolar electrocoagulation is used for haemostasis. That adverse effect could be less if the haemostasis is achieved by suturing of the rest ovarian tissue. Therefore, suturing as a method of haemostasis should be recommended in laparoscopic surgery for ovarian endometriosis. However, in spite of longer operative time surgeons should be aware of the need for proper laparoscopic suturing training and encourage themselves to practice as well.

### **Acknowledgement**

We thank Dr. Ludovico Muzii for an initial support.

## References

1. Gupta S, Goldberg JM, Aziz N, Goldberg E, Krajcir N, Agarwal A (2008) Pathogenic mechanisms in endometriosis-associated infertility. *Fertil Steril* 90(2):247-57.
2. Lemos NA, Arbo E, Scalco R, Weiler E, Rosa V, Cunha-Filho JS (2008) Decreased anti-Müllerian hormone and altered ovarian follicular cohort in infertile patients with mild/minimal endometriosis. *Fertil Steril* 89(5): 1064-8.
3. Practice Committee of the American Society for Reproductive Medicine (2006) Endometriosis and infertility. *Fertil Steril* 86(5 Suppl): S156-60.
4. Jones KD, Sutton CJ (2000) Laparoscopic management of ovarian endometriomas: a critical review of current practice. *Curr Opin Obstet Gynecol* 12(4): 309-15.
5. Beretta P, Franchi M, Ghezzi F, Busacca M, Zupi E, Bolis P (1998) Randomized clinical trial of two laparoscopic treatments of endometriomas: cystectomy versus drainage and coagulation. *Fertil Steril* 70:1176-80.
6. Muzii L, Bianchi A, Crocè C, Mancini N, Panici PB (2002) Laparoscopic excision of ovarian cysts: is the stripping technique a tissue-sparing procedure? *Fertil Steril* 77(3):609-14.
7. Alborzi S, Momtahan M, Parsanezhad ME, Dehbashi S, Zolghadri J, Alborzi S. (2004) A prospective, randomized study comparing laparoscopic ovarian cystectomy versus fenestration and coagulation in patients with endometriomas. *Fertil Steril* 82(6):1633-7.
8. Yeung PP Jr, Shwayder J, Pasic RP. (2009) Laparoscopic management of endometriosis: comprehensive review of best evidence. *J Minim Invasive Gynecol* 16(3):269-81.
9. Fedele L, Bianchi S, Zanconato G, Bergamini V, Berlanda N (2004) Bipolar electrocoagulation versus suture of solitary ovary after laparoscopic excision of ovarian endometriomas. *Am Assoc Gynecol Laparosc* 11(3):344-7.
10. Exacoustos C, Zupi E, Amadio A, et al (2004) Laparoscopic removal of endometriomas: sonographic evaluation of residual functioning ovarian tissue. *Am J Obstet Gynecol* 191(1): 68-72.
11. Barnhart K, Dunsmoor-Su R, Coutifaris C (2002) Effect of endometriosis on in vitro fertilization. *Fertil Steril* 77(6): 1148-55.
12. Hansen KR, Hodnett GM, Knowlton N, Craig LB. (2010) Correlation of ovarian reserve tests with histologically determined primordial follicle number. *Fertil Steril* [Epub ahead of print]
13. Chow GE, Criniti AR, Soules MR (2004) Antral follicle count and serum follicle-stimulating hormone levels to assess functional ovarian age. *Obstet Gynecol* 104(4): 801-4.

14. Soldevila PN, Carreras O, Tur R, Coroleu B, Barri PN (2007) Sonographic assessment of ovarian reserve. Its correlation with outcome of in vitro fertilization cycles. *Gynecol Endocrinol* 23(4): 206-12.
15. Erdem M, Erdem A, Guler I, Atmaca S (2008) Role of antral follicle count in controlled ovarian hyperstimulation and intrauterine insemination cycles in patients with unexplained subfertility. *Fertil Steril* 90(2): 360-6.
16. Pados g, Tsolakidis D, Assimakopoulos E, Athanatos D, Tarlatzis B (2010) Sonographic changes after laparoscopic cystectomy compared with three-stage management in patients with ovarian endometriomas: a prospective randomized study. *Hum Reprod* 25(3): 672-7.
17. Jayaprakasan K, Campbell B, Hopkisson J, Clewes J, Johnson I, Raine-Fenning N. (2008) Establishing the intercycle variability of three-dimensional ultrasonographic predictors of ovarian reserve. *Fertil Steril* 90(6):2126-32.
18. Muzii L, Bellati F, Bianchi A, Palaia I, Mancini N, Zullo MA et al (2005) Laparoscopic stripping of endometriomas: a randomized trial on different surgical techniques. Part II: pathological results. *Hum Reprod* 20(7): 1987-92.
19. Hachisuga T, Kawarabayashi T. (2002) Histopathological analysis of laparoscopically treated ovarian endometriotic cysts with special reference to loss of follicles. *Hum Reprod* 17(2):432-5.
20. Benaglia L, Somigliana E, Vighi V, Ragni G, Vercellini P, Fedele L (2010) Rate of severe ovarian damage following surgery for endometriomas. *Hum Reprod* 25(3):678-82.
21. Hart RJ, Hickey M, Maouris P, Bucket W. (2008) Excisional surgery versus ablative surgery for ovarian endometriomata. *Cochrane Database Syst Rev* 2:CD004992.
22. Donnez J, Nisolle M, Gillet N, Smets M, Bassil S, Casanas-Roux F (1996) Large ovarian endometriomas. *Hum Reprod* 11:641-6.
23. Tsolakidis D, Pados G, Vavilis D, Athanatos D, Tsalikis T, Giannakou A, Tarlatzis BC (2010) The impact on ovarian reserve after laparoscopic ovarian cystectomy versus three-stage management in patients with endometriomas: a prospective randomized study. *Fertil Steril*. Jun;94(1):71-7.
24. Pellicano M, Bramante S, Guida M, Bifulco G, Di Spiezio Sardo A, Cirillo D, Nappi C (2008) Ovarian endometrioma: postoperative adhesions following bipolar coagulation and suture. *Fertil Steril* 89:796-9.

Figure 1. Diagnostic procedures and treatment performed

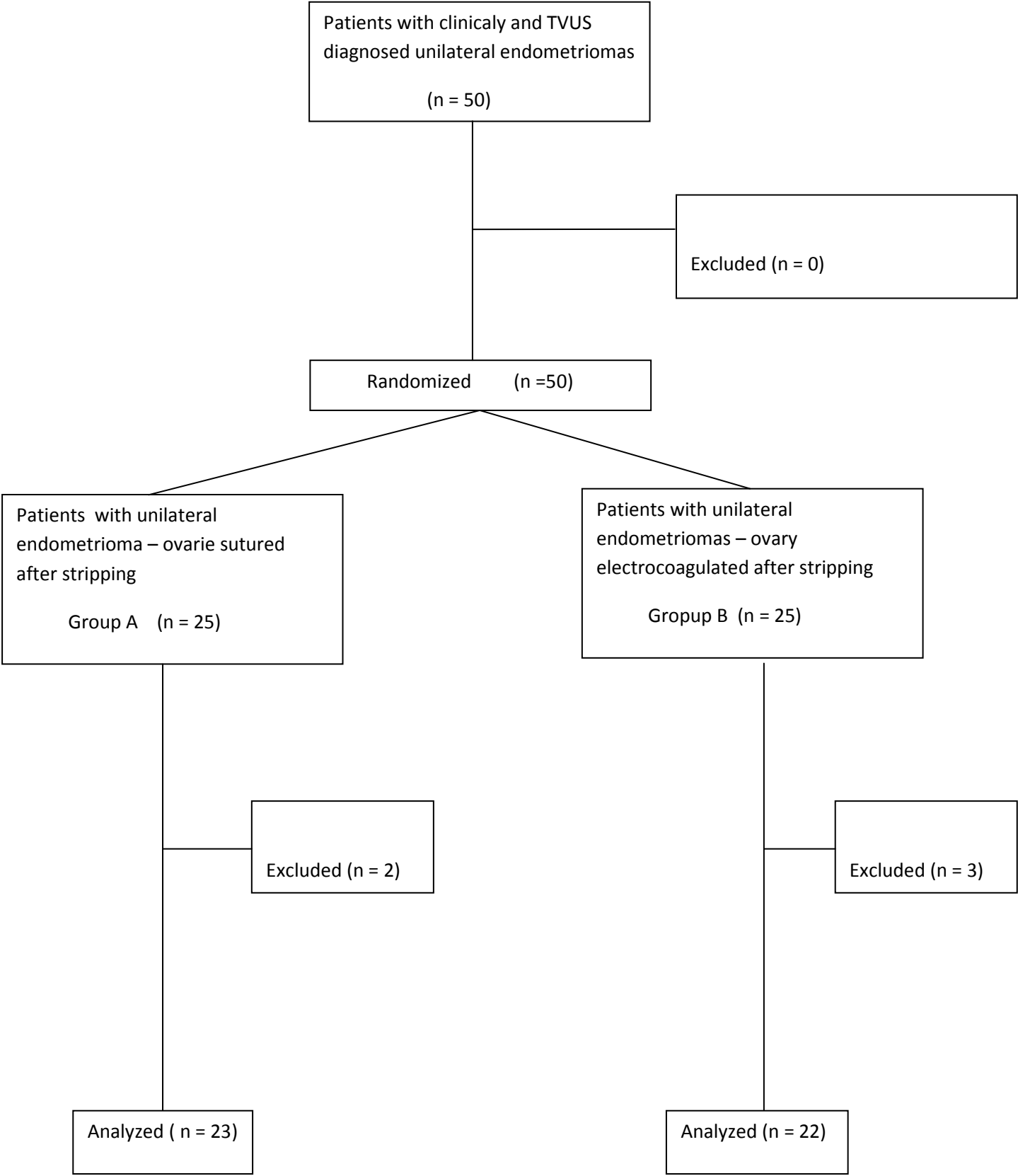


Figure 2.

Comparison of AFC between sutured (A1) and intact (A0) ovaries in groups A; Each box represents median and range. (Mann-Whitney U test ;  $p < 0,05$ )

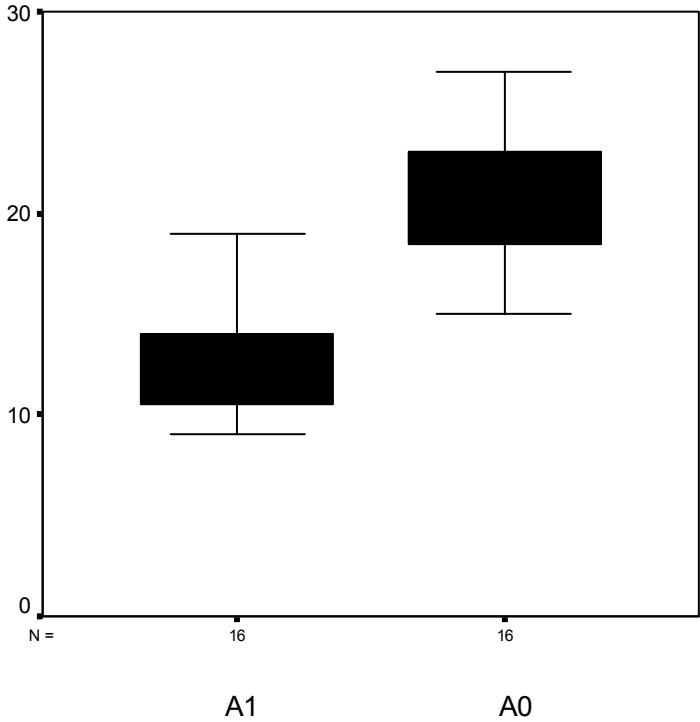


Figure 3.

Comparison of AFC between electrocoagulated (B1) and intact (B0) ovaries in group B; Each box represents median and range. (Mann-Whitney U test;  $p < 0,05$ )

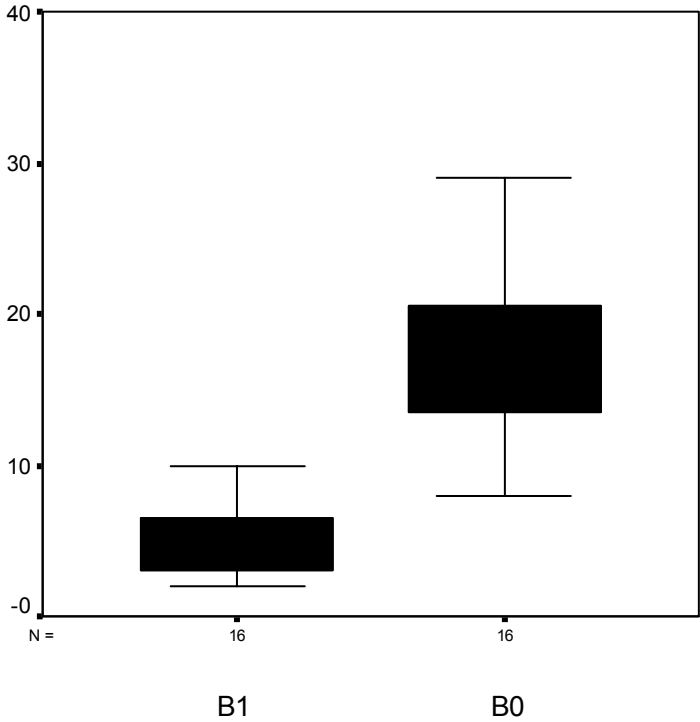




Figure 4.

Comparison of AFC between sutured (A1) and electrocoagulated (B1) ovaries in groups A and B; Each box represents median and range. (Mann-Whitney U test;  $p < 0,05$ )

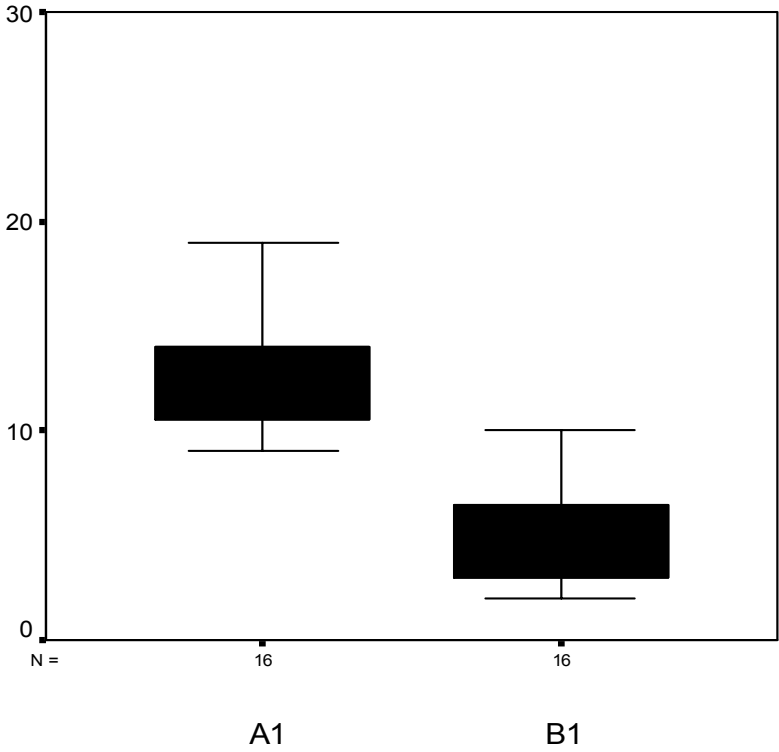


Table 1. The patient's characteristics in groups - Age, Parity and  
Size of endometriomas

	<b>A</b> <b>(n=23)</b>	<b>B</b> <b>(n=22)</b>	<b>P</b>
<b>Age (years)</b> <b>(range)</b>	<b>29,6</b> <b>(21-35)</b>	<b>31,0</b> <b>(22-35)</b>	<b>-</b>
<b>Nuliparous</b> <b>(%)</b>	<b>16</b> <b>(69,6%)</b>	<b>15</b> <b>(68,1%)</b>	<b>NS</b>
<b>Size (mm)</b> <b>of endometriomas</b> <b>(range)</b>	<b>42,8</b> <b>(33-59)</b>	<b>42,4</b> <b>(30-61)</b>	<b>NS</b>