

Paraganglioma of the urinary bladder - clinicopathological, immunohistochemical and electron microscopy analysis - a case report

Peršec, Zoran; Buković, Damir; Peršec, Jasminka; Sović, Tomislav;
Ljubanović, Danica; Lambaša, Smiljka; Radan, Mirjana; Babić, Ivan

Source / Izvornik: *Collegium Antropologicum*, 2012, 36, 1041 - 1043

Journal article, Published version

Rad u časopisu, Objavljena verzija rada (izdavačev PDF)

Permanent link / Trajna poveznica: <https://urn.nsk.hr/urn:nbn:hr:105:708707>

Rights / Prava: [In copyright](#) / [Zaštićeno autorskim pravom](#).

Download date / Datum preuzimanja: **2024-08-10**



Repository / Repozitorij:

[Dr Med - University of Zagreb School of Medicine
Digital Repository](#)



Paraganglioma of the Urinary Bladder – Clinicopathological, Immunohistochemical and Electron Microscopy Analysis – A Case Report

Zoran Peršec¹, Damir Buković², Jasminka Peršec³, Tomislav Sović¹, Danica Ljubanović⁴,
Smiljka Lambaša⁴, Mirjana Radan⁵ and Ivan Babić².

¹ University of Zagreb, Dubrava University Hospital, Department of Urology, Zagreb, Croatia

² University of Zagreb, Zagreb University Hospital Center, Department of Obstetrics and Gynecology, Zagreb, Croatia

³ University of Zagreb, Dubrava University Hospital, Anesthesiology, Resuscitation and Intensive Care Medicine Clinic, Zagreb, Croatia

⁴ University of Zagreb, Dubrava University Hospital, Department of Pathology, Zagreb, Croatia

⁵ Čakovec General Hospital, Department of Obstetrics and Gynecology, Čakovec, Croatia

ABSTRACT

Tumors that grow within the adrenal medulla are called pheochromocytoma; when located extra-adrenal, they are called paraganglioma. Paraganglioma of the bladder are very rare, with only 180 reported cases. Less than 30 were malignant. We report a case of a 72-years old man with bladder paraganglioma who presented with painless hematuria. Urgent transurethral resection (TUR) was performed. Definitive pathohistological diagnosis was confirmed to immunohistochemical and electron microscopy. Clinical diagnostic showed normal value of epinephrine and norepinephrine in the urine. Scintigraphy of entire body and targeted pictures of pelvis where taken 24, 48 and 72 hours after administration of RI. No loci of pathologic accumulation of 131-I MIBG where found. Computer tomography (CT) of pelvis and abdomen were normal. Considering staging and pathohistological analysis, we treated our patient with TUR and longtime follow-up afterwards.

Key words: paraganglioma of urinary bladder; hematuria, immunohistochemical study, electron microscopy analysis

Introduction

Paraganglioma are rare cromaffin cell tumors developed from the neural crest cells^{1,2}. Tumors derived from the parasympathetic ganglia are found almost always in the neck and skull base and usually do not secrete catecholamines. Most of the tumor derived from sympathetic ganglia are found in the abdomen and produce catecholamines. Tumors that grow within the adrenal medulla are called pheochromocytoma and paraganglioma is a term for the extra-adrenal pheochromocytomas^{1,2}. Paraganglioma of the bladder are very rare, with only 180 reported cases²⁻⁶. Less than 30 were malignant⁴⁻⁶. The first case of paraganglioma of the urinary bladder was reported by Zimmerman et al. 1953¹. There are no definitive histological, immunohistochemical and/or molecular feature to determine its malignant potential. Malignancy is basically confirmed by presence of deep local invasion,

invasion to adjacent structures and metastases to lymph nodes or bones. In general it is recognized by its clinical behavior, not by its histological features. Paraganglioma can be presented by various symptoms from painless hematuria, headache, vertigo and dizziness to the palpitation and anxiety during and after micturition. Affects both gender and age groups equally. There are reports of paraganglioma of the bladder in 11-year-old boy and 81-year old women, who is also the oldest reported patient⁸⁻¹⁰. We present a case of the 72-year-old man with the bladder paraganglioma.

Case Report

72-years old man presented to urologist in emergency unit, with painless hematuria lasted for two days and no

temperature. Initial laboratory analysis showed normal values of leukocytes and erythrocytes. Urine sediment showed >100 Leukocytes, >100 Erythrocytes, few bacteria. X-ray of urotract showed no lithiasis.

On digitorectal examination prostate was like a small apricot, elastic, confined, painless, PSA within normal ranges (2.0 µg/L). Ultrasound of urinary system (US) showed both kidneys without dilatation and lithiasis, bladder partially filled with urine, within its lumen hyperechogenic mass is visible, size 27 mm, prostate size was 30 gr. By cystoscopy in area of the trigone, we found on the left side tumors mass, 3 cm in diameter, narrow base, with little venous bleeding. Urgent transurethral resection (TUR) and electrocauterisation was performed under spinal anesthesia. Tumor tissue was sent to pathohistological analysis: tissue was mostly composed of monomorphic cells with relatively large cytoplasm that partially form solid clusters and partially smaller clusters with delicate connective tissue and blood vessels between them. In many parts of the tumor, cells had cylindrical shape. Tumor infiltrated muscle layer of the bladder, but surface epithelium, where present had normal morphology. On pathohistological analysis 6 mitosis was present on 10 large microscopic fields. Tumor cells were negative for pancytokeratin, cytokeratin of high molecular mass, epithel membrane antigen (EMA), cytokeratin 7, cytokeratin 20, HMB-45, desmin and alfa-actin, diffusely positive for vimentin (3+), neuron specific enolase (NSE) (3+), chromogranin (2+), and focally positive for synaptophysin (1+). S-100 was partially positive in small cells between tumor cells (Figure 1A, 1B, and 1C). On electron microscopy neurosecretory granules are seen (Figure 1D).

Definitive pathohistological finding confirmed diagnosis: paraganglioma of urinary bladder (pT2).

On computerized tomography (CT) both adrenal glands and kidneys were normal, with normal parenchyma, and without dilatation of canal system. Urinary bladder was also normal. No enlarged lymph nodes were found in the abdomen and pelvis.

Epinephrine in the urine was 5 nmol/24h (normal value <70 nmol/24h) and norepinephrine 163 nmol/24h (normal value <400 nmol/24h). Scintigraphy of entire body and especially targeted pictures of pelvis before and after micturition where taken 24, 48 and 72 hours after administration of RI. No loci of pathologic accumulation of 131-I MIBG were found. Regular controls and observation of the patient was planned.

Discussion

Paraganglioma of the bladder is a rare pathological entity and therefore there is very little information in the literature regarding diagnostics and especially therapy and patients follow-up^{1,9,10}. Paragangliomas can, in some cases, secrete catecholamines that can cause high blood pressure, perspiration, headache, anxiety. Majority of the patients present with painless hematuria, and most common localization of the paraganglioma is trigone as it was in our patient⁵. Only additional pathohistological analysis confirmed the diagnosis of paraganglioma. In our case electronic microscopy was also performed. Urine levels of epinephrine and norepinephrine were not elevated. Scintigraphy with I-131 MIBG, that is described in the literature as valuable complementary method

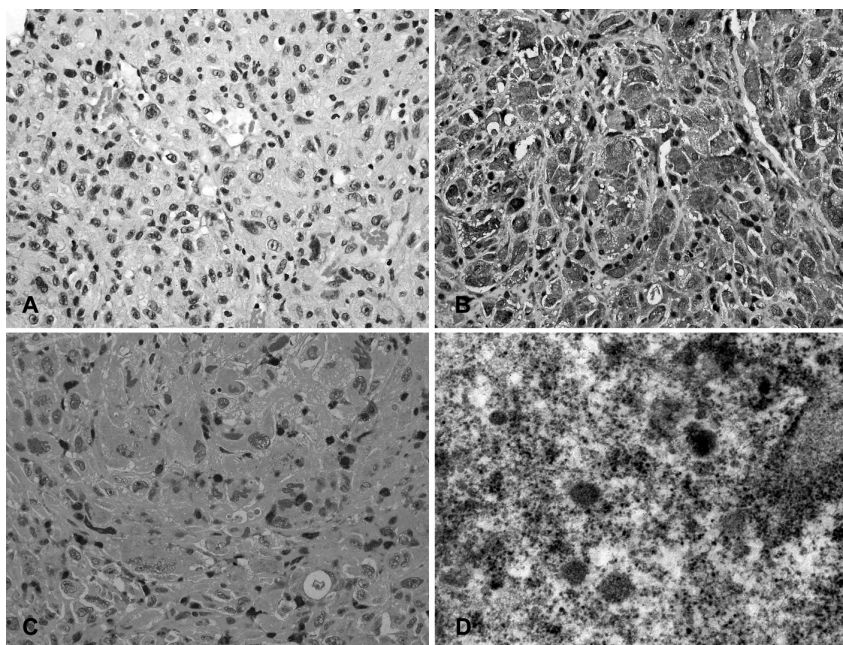


Fig. 1. Paraganglioma of the urinary bladder is shown. The tumor is composed of cells with eosinophilic cytoplasm and central vesicular nuclei (A). Immunostaining for chromogranin is strongly positive (B). Sustentacular cells are highlighted on immunostaining for S-100 protein (C). On electron microscopy neurosecretory granules are seen (D).

was performed, and no pathological accumulation is found⁷. Despite the fact that tumor is localized in the trigone urine flow was not compromised, no dilatation of renal canal system was found on US or CT. Therefore, although pathohistological analysis showed infiltration of muscular layer of the bladder, we choose regular follow-up (control cystoscopy after 3 and 6 months was normal). Control CT of abdomen and pelvis was also normal.

According to literature, patients with advanced stage tumors (T3) were treated with partial cystectomy^{8,9}. De-

spite that, they are at high risk of recurrence and metastasis. Stages T1 and T2 were treated with TUR and long-time follow-up as in our case¹⁰. These patients had favorable outcomes after complete tumor resection^{9,10}.

By reviewing database and literature we conclude that there is very small number of cases and that there are no relevant guidelines regarding treatment of bladder paraganglioma.

Further analysis and consolidation of experiences is necessary.

REFERENCES

1. ZIMMERMAN I, BIRON R, MAC MAHON H, *N Engl J Med*, 249 (1953) 25. DOI:10.1056/NEJM195307022490106. — 2. DIXON J, GOSLING J, CANNING D, GEARHART J, *J Anat*, 181 (1992) 431. — 3. MOU JW, LEE KH, TAM YH, CHEUNG ST, CHAN KW, THAKRE A, *Pediatr Surg Int*, 24 (2008) 479. DOI:10.1007/s00383-007-2013-8. — 4. KAIRI-VASSILATOU E, ARGEITIS J, NIKA H, GRAPSA D, SMYRNIOTIS V, KONDI-PAFITI A, *Eur J Gynaecol Oncol*, 28 (2007) 149. — 5. YADAV R, DAS AK, KUMAR R, *Int Urol Nephrol*, 39 (2007) 449. DOI: 10.1007/s11255-006-9017-5. — 6. CHAO JW, CHIA YC, JIA HW, CHIN CP, CHUI

MT, YI HC, CHENG YC, *Chin J Radiol*, 26 (2001) 233. — 7. NAQIYAH I, ROHAIZAK M, MEAH FA, NAZRI MJ, SUNDRAM M, AMRAM AR, *Singapore Med J*, 46 (2005) 344. — 8. SAFWAT AS, BISSADA NK, *Can J Urol*, 14 (2007) 3757. — 9. YOUNG WF JR, *Ann N Y Acad Sci*, 1073 (2006) 21. — 10. PASTOR-GUZMÁN JM, LÓPEZ-GARCÍA S, GIMÉMEZ-BACHS JM, RUIZ-MONDEJAR R, CANAMARES-PABOLAZA L, ATIÉNZAR-TOBARRA M, CASADO-MORAGÓN L, VIRSEDA-RODRIGUEZ JA, *Urol Int*, 73 (2004) 270.

Z. Peršec

University of Zagreb, Dubrava University Hospital, Department of Urology, av. G. Šuška 6, 10 000 Zagreb, Croatia
e-mail: zpersec@net.amis.hr

PARAGANGLIOM MOKRAČNOG MJEHURA – KLINIČKO-PATOLOŠKA I IMUNOHISTOKEMIJSKA ANALIZA – PRIKAZ SLUČAJA

SAŽETAK

Tumori koji rastu unutar nadbubrežne žlijezde su feokromatocitomi; kada se nalaze ekstra-adrenalno, tada se zovu paragangliomi. Paragangliomi mokraćnog mjehura su vrlo rijetki, samo je 180 opisanih slučajeva u literaturi. Manje od 30 je maligno. U našem prikazu radi se o 72-godišnjem muškarcu, sa simptomima bezbolne hematurije. Učinjena je hitna transuretralna resekcija (TUR) mokraćnog mjehura. Konačna patohistološka dijagnoza postavljena je na osnovi imunohistokemije i elektronske mikroskopije. Dijagnostička obrada pokazala je normalne vrijednosti epinefrina i nor-epinefrina u urinu. Scintigrafija cijelog tijela i ciljane snimke zdjelice učinjene su 24, 48 i 72 sata nakon primjene radioaktivnog joda (RI). Nije nađeno patološko nakupljanje kontrasta (131-I MIBG). Kompjuterizirana tomografija (CT) zdjelice i abdomena je bila uredna. Uzimajući u obzir stadij i patohistološku dijagnozu, mi smo se odlučili za TUR i dugoročno poslijeoperacijsko praćenje bolesnika.