

Pectoralis major myocutaneous flap in the reconstructive surgery of the head and neck - our experience

Rudeš, Mihael; Bilić, Mario; Jurlina, Martin; Prgomet, Drago

Source / Izvornik: **Collegium Antropologicum, 2012, 36, 137 - 142**

Journal article, Published version

Rad u časopisu, Objavljena verzija rada (izdavačev PDF)

Permanent link / Trajna poveznica: <https://urn.nsk.hr/urn:nbn:hr:105:784924>

Rights / Prava: [In copyright](#)/[Zaštićeno autorskim pravom.](#)

Download date / Datum preuzimanja: **2024-07-13**



Repository / Repozitorij:

[Dr Med - University of Zagreb School of Medicine Digital Repository](#)



Pectoralis Major Myocutaneous Flap in the Reconstructive Surgery of the Head and Neck – Our Experience

Mihael Rudeš, Mario Bilić, Martin Jurlina and Drago Prgomet

University of Zagreb, Zagreb University Hospital Center, University Department of Otorhinolaryngology and Head and Neck Surgery, Zagreb, Croatia

ABSTRACT

The goal of this retrospective study is the evaluation of pectoralis major myocutaneous pedicle flap (PMMPF) reliability in clinical practice based on the analysis of the leading indication and postoperative complications. In the period from 2005 to 2011 at the University Department of Otorhinolaryngology and Head and Neck Surgery, Zagreb University Hospital Center, a total number of 27 PMMPF were used in the treatment of 26 patients. Indications for flap use were upper aerodigestive tract and soft tissue defects following resection of head and neck cancer. One-stage reconstructive technique was used in all patients. Basic demographic data, clinical stage of malignant disease, indications, postoperative complications and management of flap-related complications were systematically analyzed. In 24 cases (89%) leading indication for flap use was primary defect reconstruction following head and neck carcinoma resection and in 3 cases (11%) »salvage« reconstruction following salivary fistula formation and flap-related complications. Tumor invaded skin in 2 (8%) cases, oral cavity in 1 (4%) case, oropharynx in 12 (46%) cases, larynx and/or hypopharynx in 10 (38%) cases and major salivary gland in 1 case (4%). Mucous defect occurred in 21 (81%), cutaneous defect in 3 (11%) and muco-cutaneous defect in 2 patients (8%), respectively. 16 postoperative complications (59.3%) were recorded but only one patient (4%) sustained total flap necrosis. Previously irradiated patients had significantly higher postoperative complication rate. The rate of complications requiring surgical treatment was 25%. Although the overall complication rate was substantially high, PMMPF achieved desired reconstructive goal in 96% cases. Functional and aesthetic assessment was difficult due to the small series of patients. In conclusion, pectoralis major myocutaneous pedicle flap is still safe and acceptable reconstructive method in surgical treatment of patients with head and neck tumors.

Key words: Pectoralis major myocutaneous flap, head and neck reconstruction, complications

Introduction

Since the first published description by Ariyan^{1,2} in 1979, the pectoralis major myocutaneous pedicle flap (PMMPF) has become the most used regional pedicle flap in the head and neck reconstructive surgery. Years later, many authors advocated PMMPF as significant advantage in reconstructive surgery over other previously employed methods^{3–5}. The size of the flap, simple harvest technique, reliable vascular supply, excellent rotational arc and versatility clearly depict advantages over other myofascial/myocutaneous flaps. Unfortunately, PMMPF has been associated with higher overall complication rate^{3–10}.

In the past two decades due to the development of microsurgical techniques, free flap transfer has broadly emerged as a new and alternative reconstructive method. Free flaps offer versatile reconstructive options even in the most demanding three-dimensional head and neck defects. Free flaps have been associated with lower morbidity to the donor and recipient site and usually provide better functional and aesthetic outcome^{11,12}. Therefore, they are presently considered »the state of the art« in the field of reconstructive head and neck surgery. Unfortunately, free flap technique requires special microsurgical instrumentation, specialized surgical team, accurate

postoperative surveillance, and longer learning curve. All previously mentioned facts limit its use in many world-wide institutions^{13–15}.

Indications for PMMPF use include reconstruction of oral cavity, pharyngeal, partial oesophageal and soft tissue defects. It can be used either alone or in combination with other reconstructive methods, such as free flaps or other pedicle flaps. Reconstruction can be achieved immediately through one-stage procedure, which is a preferred option, or it can be delayed. Accordingly, simple and low-cost technique and its versatility should sustain PMMPF as mainstay in reconstructive head and neck surgery^{4–10,16–19,20–23}. Due to the increasing number of published articles citing the high overall complication rate and doubtful reliability of PMMPF, we conducted this study in order to assess the PMMPF reliability in the clinical practice based upon 6 years of experience.

Patients and Methods

A retrospective study was conducted between March 2005 and March 2011 at the University Department of Otorhinolaryngology and Head and Neck Surgery, Zagreb University Hospital Center. 27 reconstructions with PMMPF for closure of the upper aerodigestive tract defects and soft tissue coverage were carried out on 26 patients. All operative procedures were performed by 3 surgeons with standardized one-stage reconstructive technique.

The medical history charts were retrospectively analyzed. Systematic analysis included basic demographic data, indication for flap use, site of the primary tumor, site of the defect, clinical stage of malignant disease, postoperative complications and management of flap-related complications. Complications were classified as suggested by Chepeha et al.²⁴, into *major complications* and *minor complications*. Major complications resulted in failure to attain the reconstruction goal and required secondary surgical procedure due to flap-related complications. Minor complications did not require surgical attention and were treated conservatively with daily toilette, drainage, debridement and antimicrobial medication. No matter if one complication gave rise to another, both complications were recorded. The disease was staged based on preoperative clinical examination assisted by radiological examination (CT or MRI) in accordance to the TNM classification of the UICC (Union Internationale Contre le Cancer, 2002) criteria. Postoperative photographs of final result and complications were an adjunct to the study analysis.

Description of surgical technique

After ablative procedure, the xiphoid and acromion were identified and properly marked. The size of the skin island was calculated by direct intraoperative measurement of the defect size. Skin island was then properly marked at the inferior medial border of the pectoralis major muscle (Figure 1). The initial incision was performed along previous markings in the oblique fashion down to the pectoral fascia in order to include more musculocutaneous perforators. Afterwards, the skin island

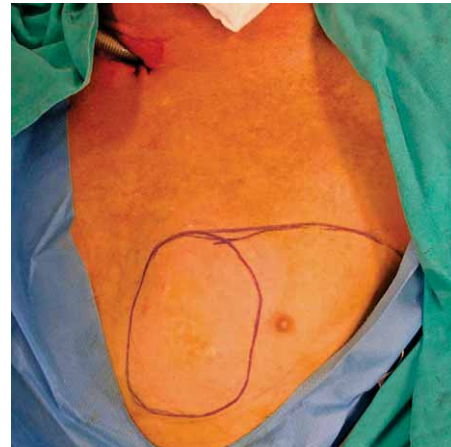

Fig. 1. Skin island markings.

was sutured to the muscle with interrupted absorbable sutures to secure the perforators during the operative handling. In order to preserve other possible regional flaps, like deltopectoral Backamijan's flap²⁵, low skin incision was performed from the lateral border of the island to the anterior axillary fold²⁶. Finding the lateral border of the pectoralis major muscle was facilitated by a blunt dissection from inferiorly to superiorly. Vascular pedicle was identified on the deep surface of the pectoralis major muscle by palpation and visualization after the flap has been completely dissected of the pectoralis minor muscle. Major vascular contribution comes from the pectoral branch of the thoracoacromial artery, and minor from lateral thoracic artery²⁷. Special attention was required during dissection of sternal border and abdominal border of the muscle. Perforators from internal mammary artery should be preserved because they feed deltopectoral flap above the 4th rib and give cutaneous vessels for the flap between 4th and 6th rib. If one should extend the flap below the 7th rib, partial flap necrosis is in jeopardy, because the cutaneous perforators derive from superior epigastric artery²⁸. After completing the dissection (Figure 2), a subcutaneous tunnel was formed

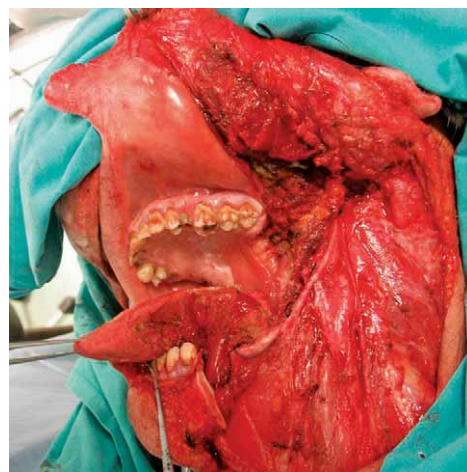

Fig. 2. Postresection defect.

between the neck and chest. The flap was passed through the tunnel and properly placed into the defect (Figure 3, 4). The donor site was closed primarily or with skin graft in case of skin shortage. Variation to the described technique would include flap without overlying skin island in the form of myofascial flap²⁹. If the patient is female, better aesthetical outcome is achieved by placing the inferior skin incision line into the submammary fold.

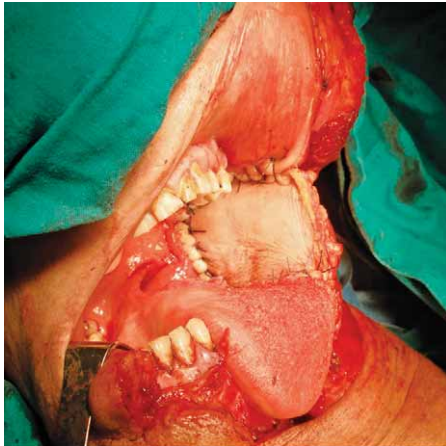

Fig. 3. Flap insertion.

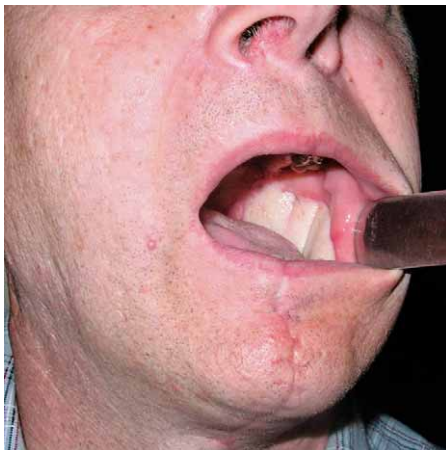

Fig. 4. Final outcome.

Results

A total of 26 patients underwent 27 reconstructive procedures with PMMPF for surgical treatment of advanced stage of head and neck cancer and related complications. 24 patients (92.3%) were men and the mean age of patient group was 61 years (47–74).

In 24 cases (89%) the leading indication for flap use was primary reconstruction of upper aerodigestive tract defects and soft tissue defects following head and neck carcinoma resection. In 3 cases (11.1%) the leading indication was »salvage« reconstruction following salivary fistula formation due to the partial or total flap loss.

17 patients presented with advanced stage of head and neck cancer (T3/T4 in 65.4%), 1 patient presented in early stage of disease (T1/T2 in 3.9%) and for 8 patients the T status could not be determined due to the recurrence (Figure 5). The tumors were located in the oropharynx (12; 46%) followed by larynx/hypopharynx (10; 38%), oral cavity (1, 4%), salivary gland (1, 4%) and skin and underlying soft tissue (2; 8%). After the surgical resection mucous defects were left behind in 21 patients (81%), cutaneous in 3 patients (11%) and muco-cutaneous in 2 patients (8%), respectively.

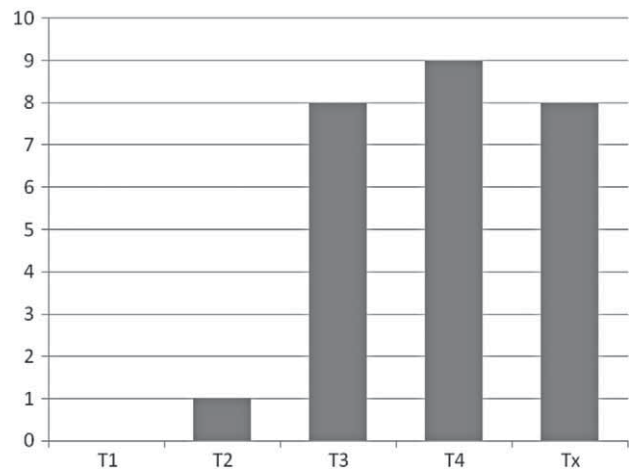


Fig. 5. Tumor related T classification.
T – size of the tumor according to the UICC, 2002.

Pathological history analysis revealed squamous cell carcinoma in 25 specimens (96.1%) and acinic cell carcinoma in 1 specimen (3.9%).

11 patients have been previously treated with either surgery or radiotherapy or both. They were divided into three separate groups. In the radiation therapy group 2 patients (2/2, 100%) have developed postoperative complication. The same rate (4/4, 100%) was recorded in the combined therapy group. In the surgery group only 1 patient (1/5, 20%) had postoperative complication. In the previously untreated group postoperative complications have occurred in 3 patients (3/14, 21.4%). The follow-up period ranged from 4 to 11 months.

16 postoperative complications were recorded, which yield overall postoperative complication rate of 59.3% (16/27). There was only one case (3.7%) of total flap necrosis leading to salvage surgery with free fasciocutaneous forearm flap in combination with contralateral PMMPF. Partial flap necrosis, salivary fistula, wound dehiscence, infection, hematoma and donor site complication were also recorded (Table 2). Complications were managed mostly conservatively (12; 75%) with daily toilette, drainage, debridement and antimicrobial medication. Surgical attention was necessary in 4 cases (4/16, 25%), 1 case required new flap and other 3 cases required

TABLE 1
COMPARATIVE STUDY ANALYSIS

Author	Number of flaps	Overall complication rate, %	Total flap necrosis rate, %	Partial flap necrosis rate, %	Salivary fistula rate, %
Ossoff ³ (1983)	95	35.0	1.0	4.0	5.0
Wilson ¹⁹ (1984)	112	16.0	7.0	9.0	NA
Kroll ⁴ (1990)	168	63.0	2.4	17.0	21.0
Shah ⁵ (1990)	211	63.0	3.0	29.0	29.0
Ijsselstein ⁶ (1996)	224	53.0	0.0	13.0	21.0
Mehta ⁷ (1996)	220	40.5	2.7	11.8	12.7
Liu ⁸ (2001)	224	34.8	4.0	11.1	7.8
Dedivitis ⁹ (2002)	17	41.2	5.9	5.9	11.8
Vartanian ¹⁰ (2004)	371	36.1	2.4	11.4	7.1
El-Marakby ²⁰ (2006)	25	60.0	7.7	11.5	46.2
Milenović ²¹ (2006)	506	33.0	1.9	10.2	5.5
McLean ²² (2010)	139	18.0	0.8	NA	NA
Present study	27	59.3	3.7	11.1	18.5

NA – not available

TABLE 2
COMPLICATIONS

Major complications	N	%	Minor complications	N	%
Total flap necrosis	1	3.7	Salivary fistula	5	18.5
Partial flap necrosis	3	11.1	Wound dehiscence	2	7.4
			Infection	3	11.1
			Hematoma	1	3.7
			Donor site complication	1	3.7
Total	4	14.8	Total	12	44.4

N – number of complications

salivary fistula closure following wide debridement. Postoperative complications were photographed (Figure 6, 7) to facilitate overall functional outcome. In the postoperative period no lethal outcome was recorded.

Discussion

Advancement in microsurgical technique and its application have generally established free flaps as preferred method in reconstructive head and neck surgery. However, free flaps are not ideal reconstructive option for every patient. Severely debilitated patients, patients with cardiovascular co-morbidities who cannot tolerate long operations and patients with inadequate recipient vessels are certainly not the best candidates for free flaps^{13,30}. In such patients pedicle flaps such as PMMPF should be preferred reconstructive technique. Advantages of the PMMPF relate to versatility, simple and short harvesting technique, proximity to the head and neck, large tissue volume and ability for one-stage operation^{16,17}. PMMPF can reconstruct various soft tissue defects, including one or two epithelial surfaces in the form of Janus flap, previously described by Dennis and

Kashima³¹. Due to its reliable and safe blood supply PMMPF is an excellent option in patients with high risk for wound failure. Moreover, large tissue volume helps to protect important neurovascular structures during healing and/or postoperative radiation period²¹. This flap can also be successfully used in combination with free flaps. Additional indications include salvage procedures after salivary fistula formation or free flap failure. If one occurs, PMMPF can be promptly harvested in order to minimize delay in healing, particularly if postoperative radiotherapy is planned³².

Just as every sword has two blades, so does reconstruction with PMMPF. Flap related complications include total or partial flap necrosis, salivary fistula formation, hematoma, infection, wound dehiscence, exposure of reconstruction material and donor site complications. Large tissue volume can hide recurrence²¹ and complicate swallowing and speech rehabilitation. Many postoperative complications were associated with flap bulk and inappropriate vascular supply to the distal part of the skin island, and therefore some authors advocate addition of lateral thoracic artery³³ as secondary vascular pedicle.

Over the last 30 years, overall complication rates reported in the literature ranged from 16% (Wilson et al.¹⁹) to 63% (Shah et al.⁵, Kroll et al.⁴). Total flap loss is the only complication that leads to reconstructive failure outcome and impose additional surgical treatment. In literature total flap necrosis occurred rarely with the lowest incidence of 0% (Ijsselstein et al.⁶) and highest 7.7% (El-Marakby et al.²⁰), respectively. In the largest series published by Milenovic and al.²¹ its incidence rate was only 1.9%. Partial flap necrosis and salivary fistula formation were much higher^{3-10,19-22} (Table 1).

Overall complication rate in the present study was significantly high (59.3%) but still comparable to other studies. Only one patient sustained a total flap necrosis (3.7%). In his case main indication was closure of the sal-

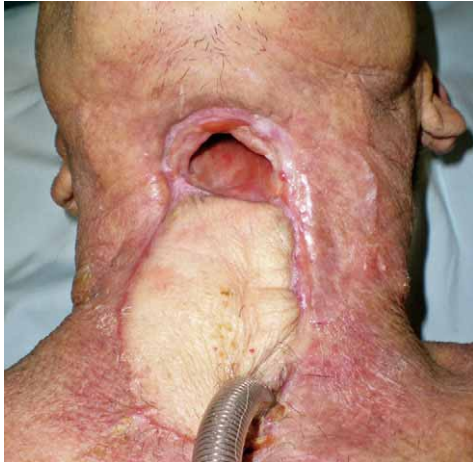


Fig. 6. Salivary fistula formation.

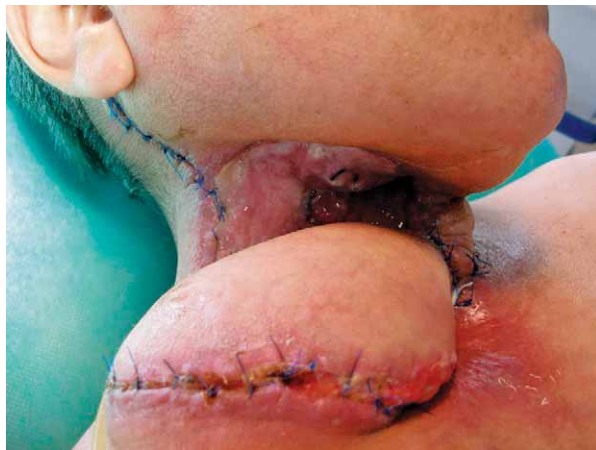

Fig. 7. Partial flap necrosis.

ivary fistula, which occurred as a postoperative complication following surgical treatment of advanced laryngeal carcinoma. The patient had no risk factors other than heavy smoking. He had successful second salvage procedure with fasciocutaneous forearm flap in combination with contralateral PMMPF. Partial flap necrosis occurred in 3 patients (11.1%) and all of them had records of previous treatment, one with surgery alone, and other two with surgery and radiation therapy. The incidence of salivary fistula occurred in 5 patients, and interestingly 4 out of 5 patients had hypopharyngeal reconstruction. PMMPF attained favorably successful result in 96.3% of cases.

REFERENCES

1. ARIYAN S, *Plast Reconstr Surg*, 63 (1979) 73, DOI: 10.1097/00006534-197901000-00012. — 2. ARIYAN S, *Plast Reconstr Surg*, 64 (1979) 605, DOI: 10.1097/00006534-197964050-00002. — 3. OSSOFF RH, WURSTER CF, BERKTOLD RE, KRESPI YP, SISSON GA, *Arch Otolaryngol*, 109 (1983) 812, DOI: 10.1001/archotol.1983.00800260034008. — 4. KROLL SS, GOEPFERT H, JONES M, GUILLAMONDEGUI O, SCHU-

When the complications were compared to the previous treatment with radiotherapy, significant difference could be observed. All patients (6/6, 100%) with previous history of radiotherapy developed flap-related complications, opposite to patients (3/14, 21.4%) who had no records of any previous treatments.

Several risk factors have been associated with flap-related complications but they are inconsistent^{4-8,16-18}. In present study we found causal connection with previous radiotherapy. The same result was reported in recent study by McLean et al²². Higher incidence of postoperative complications were also detected when leading indications were salvage procedures, oral cavity reconstructions or when patient had substantial number of comorbidities²⁴ with extension of the skin island below the 7th rib²⁸.

It is of utmost importance to stress several important notes related to surgical technique: the skin island should not be too small in order to include sufficient number of skin perforators¹⁰; any intraoperative handling must be anticipated with protective sutures²⁶; motor nerve should be identified and cut to prevent muscle contraction²¹, enhance bulk reduction⁴ and prevent crossover with vascular pedicle³⁴; extensive electrocautery use³³ should be avoided.

Conclusion

The results of our study support pectoralis major myocutaneous pedicle flap as a safe, reliable and versatile reconstructive method with acceptable number of postoperative complications and associated morbidity. The most suitable indications for flap utilization are extensive head and neck defects following primary or recurrent disease, advanced stage of disease with increased number of comorbidities and salvage procedures following free flap failure. Analysis of potential risk factors in flap survival showed correlation with previous radiotherapy, while analysis of functional outcome was difficult due to the small series of patients. Although overall complication rate was high, the flap failed to accomplish desired goal in only one case. We believe that precise surgical technique and better perioperative assessment would yield much better functional outcome and decrease possible complication issues.

Special remarks

All patients were treated in accordance to the ethical standards of the Zagreb University Hospital Center.

STERMAN M, *Ann Plast Surg*, 25 (1990) 93, DOI: 10.1097/0000637-199008000-00003. — 5. SHAH JP, HARIBHAKTI V, LOREE TR, SUTARIA P, *Am J Surg*, 160 (1990) 352, DOI: 10.1016/S0002-9610(05)80541-0. — 6. IJSSELSTEIN CB, HOVIUS SE, TEN HAVE BL, WIJTHOFF SJ, SONNEVELD GJ, MEEUWIS CA, KNEGT PP, *Am J Surg*, 172 (1996) 259, DOI: 10.1016/S0002-9610(96)00161-4. — 7. MEHTA S, SARKAR S,

- KAVARANA N, BHATHENA H, MEHTA A, *Plast Reconstr Surg*, 98 (1996) 31, DOI: 10.1097/00006534-199607000-00006. — 8. LIU R, GULLANE P, BROWN D, IRISH J, *J Otolaryngol*, 30 (2001) 34, DOI: 10.2310/7070.2001.21011. — 9. DEDIVITIS RA, GUIMARAES AV, *World J Surg*, 26 (2002) 67. — 10. VARTANIAN JG, CARVALHO AL, CARVALHO SM, MIZOBE L, MAGRIN J, KOWALSKI LP, *Head Neck*, 26 (2004) 1018, DOI: 10.1002/hed.20101. — 11. SCHUSTERMAN MA, MILLER MJ, REECE GP, KROLL SS, MARCHI M, GOEPFERT H, *Plast Reconstr Surg*, 93 (1994) 472, DOI: 10.1097/00006534-199403000-00004. — 12. KROLL SS, EVANS GR, GOLDBERG D, WANG BG, REECE GP, MILLER MJ, ROBB GL, BALDWIN BJ, SCHUSTEMAN MA, *Plast Reconstr Surg*, 99 (1997) 1282, DOI: 10.1097/00006534-199704001-00011. — 13. FUNK GF, KARNELL LH, WHITEHEAD S, PAULINO A, RICKS J, SMITH RB, *Otolaryngol Head Neck Surg*, 127 (2002) 205, DOI: 10.1067/mhn.2002.127591. — 14. TSUE TT, DESYATNIKOVA SS, DELEYIANIS FW, FUTRAN ND, STACK BC Jr, WEYMULLER EA Jr, GLEN MG, *Arch Otolaryngol Head Neck Surg*, 123 (1997) 731, DOI: 10.1001/archotol.1997.01900070075012. — 15. PETRUZZELLI GJ, BROCKENBROUGH JM, VANDEVENDER D, CREECH SD, *Arch Otolaryngol Head Neck Surg*, 128 (2002) 1377. — 16. MAGEE WP Jr, MCCRAW JB, HORTON CE, MCINNIS WD, *Am J Surg*, 140 (1980) 507, DOI: 10.1016/0002-9610(80)90201-9. — 17. BAEK SM, LAWSON W, BILLER HF, *Plast Reconstr Surg*, 69 (1982) 460, DOI: 10.1097/00006534-198203000-00010. — 18. SCHULLER DE, *Arch Otolaryngol* 109 (1983) 185, DOI: 10.1001/archotol.1983.00800170051013. — 19. WILSON JS, YIACOUMETTIS AM, O'NEILL T, *Am J Surg*, 147 (1984) 273, DOI: 10.1016/0002-9610(84)90106-5. — 20. EL-MARAKBY HH, *J Egypt Natl Canc Inst*, 18 (2006) 41. — 21. MILENOVIĆ A, VIRAG M, UGLEŠIĆ V, ALJINOVIĆ-RATKOVIĆ N, *J Craniomaxillofac Surg*, 34 (2006) 340, DOI: 10.1016/j.jcms.2006.04.001. — 22. MCLEAN JN, CARLSON GW, LOSKEN A, *Ann Plast Surg*, 64 (2010) 570, DOI: 10.1097/SAP.0b013e3181c51f4a. — 23. ZBAR RIS, FUNK GF, MCCULLOCH TM, GRAHAM SM, HOFFMAN HT, *Head Neck*, 19 (1997) 412, DOI: 10.1002/(SICI)1097-0347(199708)19:5<412::AID-HEDS>3.0.CO;2-2. — 24. CHEPEHA DB, ANNICH G, PYNNO-NEN MA, BECK J, WOLF GT, TEKNOS TN, BRADFORD CR, CARROL WR, ESCLAMADO RM, *Arch Otolaryngol Head Neck Surg*, 130 (2004) 181, DOI: 10.1001/archotol.130.2.181. — 25. BAKAMJIAN VY, *Plast Reconstr Surg*, 36 (1965) 173, DOI: 10.1097/00006534-196508000-00004. — 26. VIRAG M, *Chir Maxillofac Plast*, 12 (1982) 11. — 27. FREEMAN JL, WALKER EP, WILSON JS, SHAW HJ, *Br J Plast Surg*, 34 (1981) 3. — 28. RIKIMARU H, KIYOKAWA K, INOUE Y, TAI Y, *Plast Reconstr Surg*, 115 (2005) 1342, DOI: 10.1097/01.PRS.0000156972.66044.5C. — 29. PHILLIPS JG, POSTLETHWAITE K, PECKITT N, *Br J Oral Maxillofac Surg*, 26 (1988) 479, DOI: 10.1016/0266-4356(88)90069-1. — 30. AVERY CM, CRANK ST, NEAL CP, HAYTER JP, ELTON C, *Oral Oncol* 46 (2010) 829, DOI: 10.1016/j.oraloncology.2010.08.004. — 31. DENNIS D, KASHIMA H, *Arch Otolaryngol*, 107 (1982) 431, DOI: 10.1001/archotol.1981.00790430033009. — 32. HYODO I, NAKAYAMA B, KATO H, HASEGAWA Y, OGAWA T, TERADA A, TORII S, *Laryngoscope*, 117 (2007) 357, DOI: 10.1097/mlg.0b013e3180312380. — 33. ORD RA, *J Oral Maxillofac Surg*, 54 (1996) 1292, DOI: 10.1016/S0278-2391(96)90484-X. — 34. CUNHA-GOMES D, CHOUDHARI C, KAVARANA NM, *Ann Plast Surg*, 51 (2003) 450, DOI: 10.1097/01.sap.0000095649.87358.b7.

M. Rudeš

University of Zagreb, Zagreb University Hospital Center, University Department of Otorhinolaryngology and Head and Neck Surgery, Kišpatičeva 12, Zagreb 10000, Croatia
e-mail: mihael.rudes@gmail.com

VELIKI PEKTORALNI MIOKUTANI REŽANJ U REKONSTRUKTIVNOJ KIRURGIJI GLAVE I VRATA – NAŠE ISKUSTVO

SAŽETAK

Cilj ove retrospektivne studije je evaluacija pouzdanosti velikog pektoralnog miokutanog režnja (VPMR) u kliničkoj praksi temeljem analize vodeće indikacije za njegovu primjenu i procjene postoperativnih komplikacija. Od 2005. do 2011. godine na Klinici za otorinolaringologiju i kirurgiju glave i vrata, KBC Zagreb, ukupno 27 VPMR je primjenjeno u liječenju 26 bolesnika. Indikacije za primjenu režnja su bili defekti gornjeg aerodigestivnog trakta i mekih tkiva nakon resekcije karcinoma glave i vrata. Svi pacijenti su operirani standardiziranom tehnikom u jednom aktu. Sistematska analiza je potom izvršena prema osnovnim demografskim podatcima, vodećoj indikaciji, kliničkom stadiju maligne bolesti, postoperativnim komplikacijama te sanaciji komplikacija vezanih uz režanj. U 24 slučaja (89%) vodeća indikacija za primjenu režnja je bila primarna rekonstrukcija nakon resekcije karcinoma glave i vrata, dok je u 3 slučaja (11%) indikacija bila »spasonosna« rekonstrukcija zbog razvoja fistule i komplikacija vezanih uz režanj. Tumori su zahvatili kožu u 2 (8%), usnu šupljinu u 1 (4%), srednje ždrijelo u 12 (46%), grkljan i/ili donje ždrijelo u 10 (38%) i veliku žlijezdu slinovnicu u 1 (4%) bolesnika. Defekti su bili mukozni kod 21 (81%), kožni kod 3 (11%) i kombinirani mukozni-kožni kod 2 (8%) bolesnika. Zabilježeno je 16 postoperativnih komplikacija (59.3%) ali samo u jednog bolesnika (4%) je zabilježena kompletna nekroza režnja. Prethodno zračeni bolesnici su imali značajno viši postotak postoperativnih komplikacija. Broj postoperativnih komplikacija koji je zahtijevao operativni tretman je iznosio 25%. Iako je udio svih postoperativnih komplikacija bio visok, VPMR je ispunio željeni cilj u 96% slučajeva. Ocjena funkcionalnog i estetskog uspjeha je značajno bila otežana malom serijom bolesnika liječenih ovom metodom. Naposljetku možemo zaključiti da je VPMR i dalje sigurna i prihvatljiva rekonstruktivna metoda u bolesnika oboljelih od malignih tumora glave i vrata.