

Neuroendocrine tumors of larynx - two case reports and literature review

Carić, Tomislav; Bilić, Mario; Kovač Bilić, Lana; Prgomet, Drago; Kovačić, Jelena; Topić Grahovac, Iva; Hutinec, Zdenka

Source / Izvornik: **Collegium Antropologicum, 2012, 36, 173 - 178**

Journal article, Published version

Rad u časopisu, Objavljena verzija rada (izdavačev PDF)

Permanent link / Trajna poveznica: <https://um.nsk.hr/um:nbn:hr:105:889140>

Rights / Prava: [In copyright](#)/[Zaštićeno autorskim pravom.](#)

Download date / Datum preuzimanja: **2024-06-22**



Repository / Repozitorij:

[Dr Med - University of Zagreb School of Medicine
Digital Repository](#)



Neuroendocrine Tumors of Larynx – Two Case Reports and Literature Review

Tomislav Carić¹, Mario Bilić², Lana Kovač Bilić², Drago Prgomet², Jelena Kovačić¹, Iva Topić Grahovac² and Zdenka Hutinec³

¹ University of Zagreb, Dubrava University Hospital, Department of ENT, Head and Neck Surgery, Zagreb, Croatia

² University of Zagreb, Zagreb University Hospital Center, Department of ENT, Head and Neck Surgery, Zagreb, Croatia

³ University of Zagreb, Zagreb University Hospital Center, Department of Pathology, Zagreb, Croatia

ABSTRACT

Neuroendocrine tumors (NET) of the larynx are rare and heterogenous group, with much confusion about nature and classification of these neoplasms in the past. Diagnosis is based primarily on light microscopy and confirmed by immunohistochemistry and electron microscopy. A classification in 4 different types; paraganglioma, typical carcinoid, atypical carcinoid and small cell neuroendocrine carcinoma (SCNC) is a current consensus. Thorough diagnostic and a proper classification of neuroendocrine neoplasms are of paramount importance – prognosis and treatment differ significantly. We present two cases: 63-year old patient with SCNC of the larynx and a 53-year old patient with atypical carcinoid of the larynx. OctreoScan is useful tools for diagnostics and follow up of the patients and it is predictive for effectiveness of octreotide therapy.

Key words: neuroendocrine tumors, laryngeal neoplasms, therapy

Introduction

Laryngeal cancer accounts for approximately 2% and 5% of new malignancies worldwide every year, of which 85% to 90% are of the squamous type^{1,2}. NET are rare in the head and neck region, most commonly they originate in the gastrointestinal system or the bronchial system: the appendix, small intestine, rectum and bronchus^{3,4}. Within head and neck region, larynx is most commonly NET involved site, in fact, NET are most common non-epidermoid larynx carcinoma type⁵. NET represent 0.5–1% of larynx epithelial cancers⁶, and within larynx, they occur more often in epiglottis and supraglottic region⁷. First NET larynx case was described back in 1969 by Goldman et al.⁸ and over 700 cases of this neoplasm have been reported in literature since then^{9–12}. Other NET head and neck described sites include petrous apex, nasopharynx, tonsil, tongue, hypopharynx, salivary glands^{13–18}. NET of larynx are divided into 2 categories based on their tissue of origin: epithelial and neural. Epithelial category consists of 3 types: typical carcinoid (well differentiated neuroendocrine carcinoma, grade I), atypical carcinoid (moderately differentiated neuroendocrine carcinoma, grade II; large cell neuroendocrine carcinoma)

and small cell neuroendocrine carcinoma (poorly differentiated neuroendocrine carcinoma, grade III). Neural category consists of paraganglioma. NET of larynx are also divided into primary and secondary types with the latter being extremely rare. Only 5 cases of secondary SCNC of larynx are reported in literature¹⁰ and differentiation between primary lung and larynx SCNC is made by imaging lung studies¹⁹. In this article, we describe two cases of these rare neoplasms, summarize the current literature regarding NET and emphasize OctreoScan as valid additional method for diagnostic and follow up of patients, as well as predictive test for useful octreotide therapy.

Materials and Methods

Case 1 presentation

A 63-yr-old man was referred to our center with dispnea, dry cough and febrility up to 38 °C. He was previously, 2 months ago, treated in other hospital for leg weakness and urine retention. Preliminary diagnostics

showed L3 vertebra fracture, and the MR of the lumbal spine and chest X-ray was performed. Laminectomy, reposition and traspedicular biopsy was made and pathohistological report showed metastasis of SCNC. MSCT of the thorax and upper abdomen was performed. We performed fiberoendoscopy which revealed a submucosal tumorous expansive mass on laryngeal side of epiglottis, left ariepiglottic fold, left venricular fold with left cord fixation (Figure 1). Clinical examination of the neck showed bilaterally enlarged and fixated lymph nodes in reg. III. A

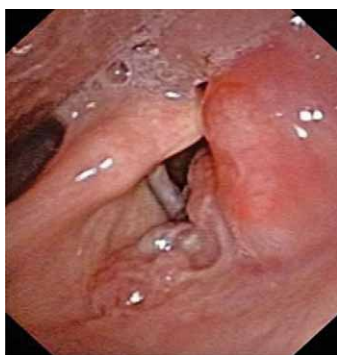


Fig. 1. Laryngoscopic image showing a tumorous mass involving laryngeal surface of epiglottis with left cord fixation.

MSCT of the head and neck (Figure 2) showed an expansive mass involving left side of the larynx, left side of the epiglottis with possible infiltration, prominating in left valecula, involving sinus piriformis, paralaryngeal space, left vocal cord and anterior commisure reaching slightly over the medial line. Infiltration and the destruction of the left thyroid cartilage are seen, with possible left cricoarythenoid joint destruction. Enlarged neck lymph nodes on the left I region 12mm, II region 16mm right

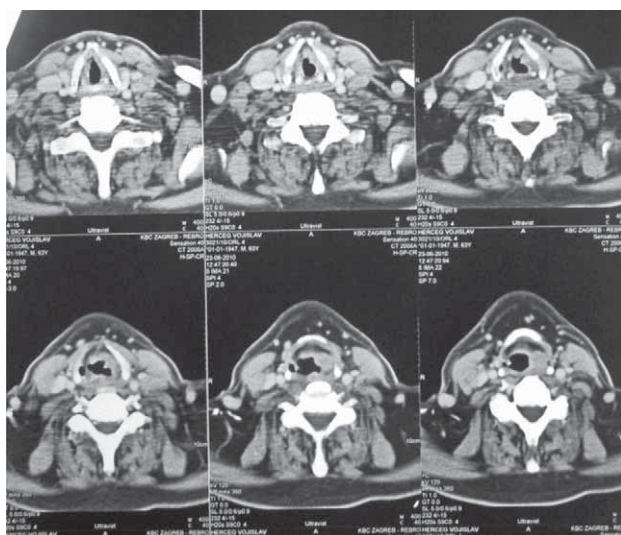


Fig. 2. A MSCT scan showing expansive mass invading left side of larynx, epiglottis, sinus piriformis, paralaryngeal space and anterior commissure.

II/III region 2 cm and VII region 14mm. Both jugular veins are compressed and carotid arteries intact. We performed laryngomicroscopy, biopsy and mapped the tumor. Pathohistologic analysis showed carcinoma neuroendocrines. A tumor is arising submucosally, but infiltrates epithelial surface focally. It is formed from monomorphic small atypical cells forming sheets with hyperchromatic nuclei and scant cytoplasm (Figure 3), showing »crushing« effect (Figure 4). Immunohistochemistry report

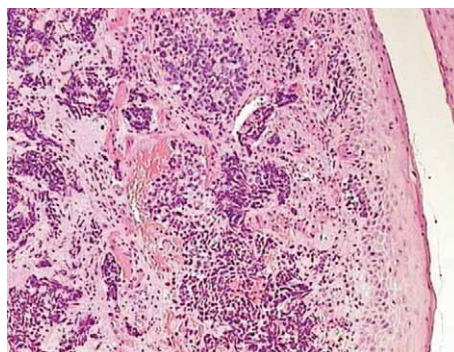


Fig.3. Small cell neuroendocrine carcinoma of the larynx. The tumor is composed of uniform small cells with hyperchromatic nuclei and scanty cytoplasm (H&E stain, original magnification, x100).

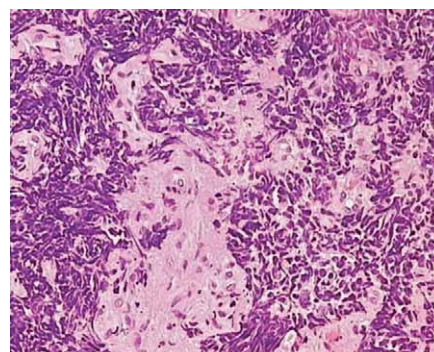


Fig. 4. Small cell neuroendocrine carcinoma of the larynx. Tumor cells with »crushing« effect (H&E stain, original magnification, x200).

showed positive reaction on synaphophysin, AE1/AE3, EMA and negative reaction on NSE and chromogranin. Tumor stage (T4aN2Mx) was determined after clinical and instrumental evaluation including CT scan. The patient subsequently underwent total laryngectomy with left radical modified neck dissection (type I) and tracheostomy formation (Figure 5). Postoperative pathohohistologic report showed SCNC (carcinoma neuroendocrines gr. III laryngis) with lymph nodes metastasis (reg. I 0, reg. II 8/7, reg. III 2/2, reg. IV 0/0, reg. V 4/2). Following such a ominous result of pathohistological analysis we decided to treat contralateral neck and after 6 weeks we performed right radical neck dissection. After the surgical treatment we performed an OctreoScan which was

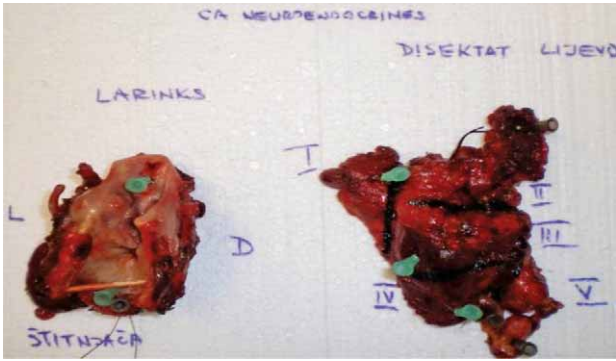

Fig. 5. Tumor involving supraglottic larynx, predominantly left side with metastatic spread to the left side of neck.

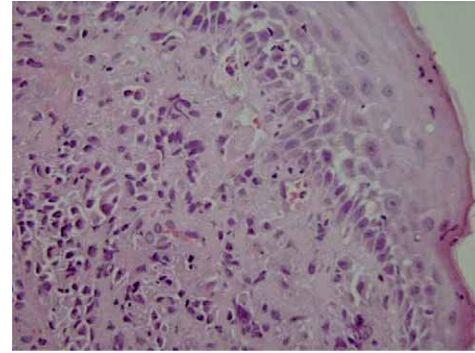


Fig. 7. Submucosal laryngeal carcinoid arranged in trabecular pattern with prominent fibrovascular stroma. (H&E stain, original magnification, x400).

negative. Patient underwent chemotherapy treatment with streptozocin and 5-FU. A patient died several months after treatment.

Case 2 presentation

A 53-yr old patient was referred to our center with a neck tumor progressing in size over a year, last few months rapidly. Preliminary diagnostics was performed in another hospital; neck and thyroid ultrasound showing hypoechoic node in right thyroid lobe 42x21x24 mm in size and 2 enlarged lymphatic nodes in right III neck region 31x20x18 mm and 32x29x15 mm. Scintigram of the thyroid gland revealed »cold« zone in right thyroid lobe. Citopunction of the reg.III node suggested metastatic node from medullary thyroid carcinoma and citopunction of the enlarged right thyroid lobe suggested follicular thyroid tumor. Clinical status showed enlarged right thyroid lobe and a neck mass in right III region. We performed fiberoendoscopy that revealed enlarged right aryepiglottic fold (Figure 6). Operative treatment included

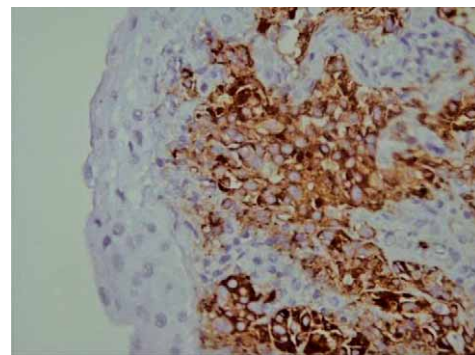


Fig. 8. Strong synaptophysin immunoreactivity in laryngeal carcinoid (original magnification, x400).

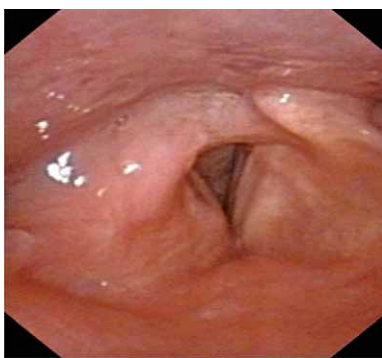

Fig. 6. Tumorous mass involving right aryepiglottic fold.

laryngomicroscopy with excisional biopsy of the enlarged right aryepiglottic fold, total thyroidectomy with selective right neck dissection (reg.II–IV) as well as pretracheal and bilateral paratracheal dissection. Pathohistologic report showed atypical carcinoid of the aryepiglottic fold (Figure 7, 8) with metastasis to the reg. III of the

neck (Figure 9) as well as follicular adenoma of the right thyroid lobe and microcarcinoma papillare of the left thyroid lobe without metastases to the paratracheal or pretracheal region. A complication occurred a month after an operation— formation of the neck abscess which warranted neck exploration with drainage. A month later additional resection of the right aryepiglottic fold from petiolus to the right arytenoid was performed by CO2 laser. Pathohistologic report showed small residual atypi-

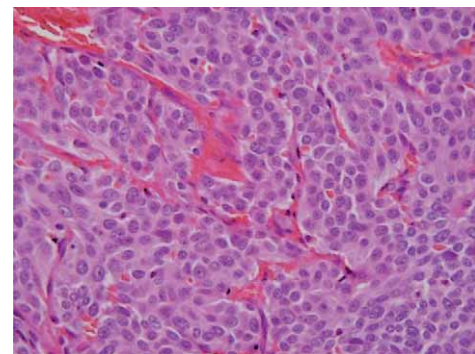


Fig. 9. Metastatic carcinoid in lymph node arranged in solid sheets and nests (H&E stain, original magnification x400).

cal carcinoid tumor tissue next to the granulation tissue and scar formed after the last excision. Residual tumor tissue was completely excised and removed with clear pathohistologic margins. Patient has no symptoms to present date and is waiting for OctreoScan to be performed.

Discussion

The identification of NET is a stepwise process. Tumor first should be recognized as neuroendocrine through neuroendocrine morphology on conventional light microscopy including peripheral palisading of tumor nests, trabeculae, glandular differentiation, rosette formation, »crush artifact« and other histological features⁵. After NET tumor consideration, it is important to distinguish between subtypes, which is done by immunohistochemistry or electron microscopy. However, SCNC is predominantly a morphologic diagnosis, as in a limited number of cases this tumor is negative for all neuroendocrine markers. In lungs absence of staining for neuroendocrine markers occurs in 10–15%²⁰. Immunohistochemistry does not serve as a substitute but as a valid adjuvant in the light evaluation of the morphologic criteria of these neoplasms²¹. Tumors of the larynx with neuroendocrine differentiation have widely varying prognosis and response to therapy – accurate histological diagnosis is essential. NET can be confused with other neoplasms such as adenocarcinoma, acinic cell carcinoma, basaloid squamous cell carcinoma, solid type of adenoid cystic carcinoma, poorly differentiated squamous cell carcinoma, undifferentiated carcinoma, amelanotic malignant melanoma, medullar thyroid carcinoma, lymphoma, hemangiopericytoma and others²². NET, or SCNC in particular, presenting initially in larynx may be metastases from distant sites. Most often primary site is the lungs, but extrapulmonary sites have been reported^{23,24}. Another specific clinical feature of SCNC of the larynx is its possible association with different paraneoplastic syndromes, and this may be a reason for presentation¹⁰. Syndrome of inappropriate secretion of antidiuretic hormone (SIADH), myastenic syndrome, ectopic adrenocorticotrophic hormone (ACTH) syndrome have all been described^{25–27}. Possible symptoms include headache, confusion, temporo-spatial disorientation, hyperreflexia, hyponatremia, reduced hematocrit, high plasma levels of antidiuretic hormone. Atypical carcinoid is the most common neuroendocrine tumor of the larynx²⁸. It is more common among older men (6th decade) with a history of heavy cigarette smoking. The vast majority of this tumor shows a supraglottic origin²⁹. The diagnosis of atypical carcinoid may be difficult, especially on the initial biopsy evaluation but it is crucial to make a proper diagnosis. In contrast with typical carcinoid mitosis, cellular pleomorphism and necrosis are the critical features for diagnosis²⁸. Immunohistochemical staining is important additional tool in diagnostic process; carcinoma cells are usually positive for markers such as chromogranin, synaptophysin, keratin, calcitonin and carcinoembryonic antigen. The final diagnosis should not be based solely on the presence or absence of a single immunohistochemical stain marker, and

a panel of immunohistochemical antibodies is utilized^{29–31}. Another important diagnostic tool is OctreoScan, which is used as help in diagnostics and follow up of the NET patients. It is an Indium-111 labeled somatostatin analog with high affinity for somatostatin receptors, which are found on most NET tumors. Its major advance is longer biological half-life, and major benefit inhibition of hormone secretion and, possible, tumor growth inhibition. Octreotide, like somatostatin, binds to receptors on the cells of carcinoid tumors and inhibits the manufacture and release of tumor hormones. Octreotide is very effective in controlling the symptoms of flushing and diarrhea that are part of the carcinoid syndrome. Octreotide has been found to reduce the excretion of 5-HIAA in some patients. Octreotide also has been found to slow the growth of carcinoid tumors, and, in a few patients, even reduce the size of the tumors and their metastases. Positive OctreoScan invokes octreotide therapy, which offers additional hope for selected NET patients.

Treatment and prognosis Typical Carcinoid

These very rare tumors are best treated with conservative surgery^{32,33}, most often partial laryngectomy. Larger tumors may require total laryngectomy, and neck dissection is not indicated in view of the usual absence of lymph node metastases³⁰. Irradiation and chemotherapy are not recommended as they are found to be ineffective¹². However, metastases from this tumor have been described, including distant and multiple liver metastases^{34–36}. Prognosis is not as favorable as we thought in the past – 5-year survival rate is 48.7% in a large series³⁷, but it is unclear and doubtful that some of the typical carcinoids have been misdiagnosed as atypical carcinoids¹².

Atypical Carcinoid Tumor

Surgical excision is the treatment of choice^{12,32}. As many tumors are supraglottic, partial supraglottic laryngectomy is often performed, but depending on the extent of the primary tumor, a total laryngectomy may be warranted. As perineural extension may exist peripheral to the tumor mass, wide resection beyond clinically detectable cancer margins is indicated³⁸. Endoscopic laser surgery is often employed instead of external approach for supraglottic atypical carcinoid tumor³⁹. Elective neck dissection is warranted in view of the high incidence of the early cervical metastases and subsequent involvement of cervical nodes^{30,40}. Although this tumor is reported to be radiotherapy and chemotherapy resistant^{38,40}, addition of radiotherapy appears to be beneficial to at least some patients as showed in a Gillenwater et al.²⁹ retrospective study. Radiation therapy is recommended for cases of local extension, multiple nodal metastases or extracapsular disease^{31,41}. Prognosis of this tumor is unfavorable with aggressive behavior and high metastatic potential. Cervical metastases are often present, and distant metastases to bone, skin, subcutaneous tissues, distant lymph nodes, lung, mediastinum, liver, heart, pancreas, diaphragm, peritoneum gastrointestinal tract, prostate, breast, brain, dura mater, pleura testicle and

muscle are also described. Death usually results from distant metastases and not from the local or regional recurrence. The survival rate is 48% at 5 years, and 30% at 10 years⁴².

Small Cell Neuroendocrine Carcinoma

Treatment is still a subject of debate, and role of a radical surgery is yet to be fully evaluated. Although radical surgical procedures such as total laryngectomy and radical neck dissection offer locoregional control of the disease long term survival depends on the extent of the disease⁴³. It is wise and recommendable to perform a full medical evaluation and systematic work-up to exclude metastatic lung or extrapulmonary disease, as well as to establish exact stage of the disease. The combination of primary radiation therapy and adjuvant chemotherapy resulted to prolonged median patient survival up to 55 months and is suggested by Baugh et al⁴⁴. A combination of cyclophosphamide, doxorubicin, vincristine, methotrexate and lomustine and a 9 to 18 month long treatment is usually recommended^{44,45}. SCNC generally has a dismal prognosis, which depends on the extent of the disease. The 2 and 5 years survival rates are 16% and 5%, respectively⁴⁶. Different paraneoplastic syndromes have been reported in cases of SCNC and reportedly all patients died⁴⁷.

Paraganglioma

Partial laryngectomy remains the mainstay of treatment of this benign lesions⁴⁸. Transoral laser microsurgery is not recommended because of vascular nature of these tumors. Preoperative angiography and embolization are often unnecessary because of the generally small size and consistent blood supply of the lesion. Ligation of the arterial blood supply at the time of surgery will mini-

mize blood loss. Conservative procedures such as supra-glottic laryngectomy or local excision via laryngofissure, with or without cricoid split in small number of trans-ventricular or infraglottic tumors are usually performed and usually successful^{49–53}. Behavior of this lesion is benign and the prognosis is excellent with just one paraganglioma in literature accepted to have metastatic spread^{54,55}.

Conclusion

NET of larynx constitute a variety of rare neoplasms. Many different names and classifications have been used in the past, adding much to the confusion. Currently NET of larynx are classified as typical carcinoid, atypical carcinoid, SCNC and paraganglioma. It is of utmost importance to make a proper diagnosis of NET subtype as the treatment and prognosis differ. Larynx is the most common extrapulmonary site of SCNC, with only 5 cases of secondary SCNC to the larynx described in literature¹⁰, and differentiation is made by imaging studies¹⁹. SCNC is also associated with different paraneoplastic syndromes, and overall prognosis is bad. It is an aggressive neoplasm often disseminated at presentation, and extent of the disease is the most significant prognostic factor for survival. Adding the concurrent chemoradiotherapy offers potential for long-term survival. Atypical carcinoid is tumor with aggressive behavior, high metastatic potential and 30% 10-yr survival rate. It is best treated by partial or total laryngectomy with elective or therapeutic neck dissection. Adjuvant chemo/radiotherapy could be beneficial, at least for some patients. Octreoscan is valid additional test in diagnosis and follow up of the NET patients, and octreotide therapy offers hope for higher and prolonged survival.

REFERENCES

1. FERLITO A., FRIEDMANN I, Neoplasms of the Larynx (Churchill Livingstone, Edinburgh, UK, 1993). — 2. FERLITO A, Unusual forms of squamous cell carcinoma. In: FERLITO A (Ed) Surgical pathology of laryngeal neoplasms (Chapman and Hall Medical, London, UK, 1996). — 3. KULKE MH, MAYER RJ, *New Eng J Med*, 340 (1999) 858. — 4. MODLIN IM, SANDOR A, *Cancer*, 79 (1997) 813. — 5. FERLITO A, SILVER CE, BRADFORD CR, RINALDO A, *Head Neck*, 10 (2009) 1637. DOI: 10.1002/hed.21162. — 6. MARCO C, BERTINO G, MORBINI P, VILLA C, ZORZI S, BENAZZO M, *Tumori*, 93 (2007) 499. — 7. BROWNE JD, *Otolaryngol Clin North Am*, 30 (1997) 667. — 8. GOLDMAN NC, HOOD CI, SINGLETON GT, *Arch Otolaryngol*, 90 (1969) 64. — 9. BRANDWEIN-GENSLER MS, MAHADEVIA P, GNEPP DR, Laryngeal pathology. In: FRIED MP, FERLITO A (Eds) *The Larynx* (Plural Publishing, San Diego, CA 2009). — 10. FERLITO A, RINALDO A, *Head Neck* 30 (2008), 518. DOI: 10.1002/hed.20797. — 11. LIN HW, BHATTACHARYYA N, *Laryngoscope* 118 (2008) 1003. — 12. FERLITO A, DEVANEY KO, RINALDO A, *Oral Oncol* 42 (2006) 770. DOI: 10.1007/978-1-4419-1707-2. — 13. KOVAC L, GJURIC M, BRANICA S, DAWIDOWSKY K, SEIWERTH S, *J Laryngol Otol* 120 (2006) 74. — 14. LIN IH, HWANG CF, HUANG HY, CHIEN CY, *Acta Otolaryngol*, 127 (2007) 206. DOI: 10.1080/00016480500401027. — 15. BAWA R, WAX MK, *Otolaryngol Head Neck Surg*, 113 (1995) 328. — 16. HULL MT, EBLE JN, WARFEL KA, *J Oral Pathol*, 13 (1984) 489. — 17. GABA A, MBAOMA R, BREINING D, SMITH RV, BEITLER JJ, HAIGENTZ M JR, *J Clin Oncol*, 23 (2005) 2094. — 18. IBRAHIM NBN, BRIGGS JC, CORBYSHLEY CM, *Cancer*, 54 (1984) 1645. — 19. BARNES L, neuroendocrine Tumors. In: BARNES L, EVESON JW, REICHAFT P, SIDRAN-

- SKY D (Eds) *Pathology and Genetics. Head and Neck tumors*. World Health Organization classification of tumours (IARC Press, Lyon, France, 2005). — 20. BEASLEY MB, *Arch Pathol Lab Med*, 132 (2008) 1062. DOI: 10.1038/modpathol.2009.30. — 21. FERLITO A, FRIEDMANN I, *ORL J Otorhinolaryngol Relat Spec*, 53 (1991) 235. — 22. MILROY CM, FERLITO A, *Ann Otol Rhinol Laryngol*, 104 (1995) 770. — 23. GRIGNON DJ, AYALA AG, RO JY, CHONG C, *Urology*, 36 (1990) 85. — 24. DANIKAS D, THEODOROU SJ, MATTHEWS WE, REINZO AA, *Am Surg*, 66 (2000) 1189. — 25. TROTOUX J, GLICKMANAS M, STERKERS O, TROUSSET M, PINEL J, *Ann Otolaryngol Chir Cervicofac*, 96 (1979) 349. — 26. MEDINA JE, MORAN M, GOEPFERT H, *Arch Otolaryngol*, 110 (1984) 123. — 27. BISHOP JW, OSAMURA RY, TSUTSUMI Y, *Acta Pathol Jpn*, 35 (1985) 915. — 28. CHUNG EJ, BAEK SK, KWON SY, WOO JS, JUNG KY, *Clin Exp Otorhinolaryngol*, 4 (2008) 217. DOI: 10.3342/ceo.2008.1.217. — 29. GILLENWATER A, LEWIN J, ROBERTS D, EL-NAGGAR A, *Laryngoscope*, 115 (2005) 1191. DOI: 10.1097/01. — 30. FERLITO A, BARNES L, RINALDO A, GNEPP DR, MILROY CM, *J Laryngol Otol*, 112(9) (1998) 827. — 31. FERLITO A, SHAHA AR, RINALDO A, *ORL J Otorhinolaryngol Relat Spec*, 64(2) (2002) 108. DOI: 10.1159/000072249. — 32. MOISA II, SILVER CE, *ORL J Otorhinolaryngol Relat Spec*, 53 (1991) 259. — 33. BAPAT U, MACKINNON NA, SPENCER MG, *Eur Arch Otolaryngol*, 262 (2005) 194. DOI: 10.1007/s00405-004-0788. — 34. SOGA J, FERLITO A, RINALDO A, *Oral Oncol*, 40 (2004) 668, DOI: 10.1007/j.oraloncology.2003.09.017. — 35. BATSAKIS JG, EL-NAGGAR AK, LUNA MA, *Ann Otol Rhinol Laryngol*, 101 (1992) 710. — 36. WENIG BM, GNEPP DR, *Semin Diagn Pathol*, 6 (1989) 329. — 37. SOGA J, *J Exp Clin Cancer*

Res, 22 (2003) 517. — 38. MILLS SE, JOHNS ME, Arch Otolaryngol, 110 (1984) 58. — 39. CHANG KP, LEE LY, YEH AR, DAI TS, HAO SP, Head Neck, 27 (2005) 1004. — 40. GOLDMAN NC, KATIBAH GM, MEDINA J, Ear Nose Throat J, 64 (1985) 130. — 41. SHEMEN L, PETRATOS P, PATEL S, HOROWITZ L, Ear Nose Throat J, 82 (2003) 205. — 42. WOODRUFF JM, SENIE RT, ORL J Otorhinolaryngol Relat Spec, 53 (1991) 194. — 43. FERLITO A, PESAVENTO G, RECHER G, Auris Nasus Larynx, 13 (1986) 113. — 44. BAUGH RF, WOLF GT, BEALS T, KRAUSE CJ, FORASTIERE A, Laryngoscope, 96 (1986) 1283. — 45. FERLITO A, Ann Otol Rhinol, 95 (1986) 590. — 46. GNEP DR, ORL J Otorhinolaryngol Relat Spec, 53 (1991) 210. — 47. FERLITO A, RINALDO A, Ann Otol Rhinol Laryngol, 116 (2007) 502. — 48. KONOWITZ PM, LAWSON W,

SOM PM, URKEN ML, Laryngoscope, 98 (1988) 40. — 49. MODLIN IM, SHAPIRO MD, KIDD M, World J Surg, 29 (2005) 92. — 50. PETERSON KL, FU Y-S, CALCATERRA T, Head Neck, 19 (1997) 54. — 51. GUPTA S, PATHAK KA, SANGHVI V, Eur Arch Otorhinolaryngol, 260 (2003) 358. DOI: 10.1007/s00405-002-0558-7. — 52. SANDERS KW, ABREO F, RIVERA E, STUCKER FJ, NATHAN CAO, Arch Otolaryngol Head Neck Surg, 127 (2001) 565. — 53. MAISEL R., SCHMIDT D, PAMBUCCIAN S, Laryngoscope, 113 (2003) 401. — 54. FERLITO A, MILROY CM, WENIG BM, BARNES L, SILVER CE, Ann Otol Rhinol Laryngol, 104 (1995) 78. — 55. RINALDO A, FERLITO A, MYSSIOREK D, DEVANEY KO, Oral Oncol, 40 (2004) 458.

T. Carić

*University of Zagreb, Dubrava University Hospital, Department of ENT, Head and Neck Surgery, Av. Gojka Šuška 6, 10 000 Zagreb, Croatia
e-mail: tcarić@gmail.com*

NEUROENDOKRINI TUMORI LARINKSA – PRIKAZ DVA SLUČAJA I PREGLED LITERATURE

SAŽETAK

Neuroendokrini tumori larinksa rijetka su i heterogena grupa neoplazmi o čijoj prirodi i podjeli je u prošlosti bilo dosta proturječja. Dijagnoza bolesti postavlja se primarno svjetlosnom mikroskopijom, a potvrđuje imunohistokemijom i elektronskom mikroskopijom. Suvremeni konsenzus je podjela neuroendokrinih tumora na 4 tipa: paragangliom, tipični karcinoid, atipični karcinoid i karcinom malih stanica. Precizna dijagnostika i klasifikacija neuroendokrinih tumora od najveće je važnosti – prognoza i način liječenja uvelike se razlikuju. Predstavljamo dva slučaja: 63-godišnjeg bolesnika sa karcinomom malih stanica i 53-godišnjeg bolesnika sa atipičnim karcinoidom larinksa. Oktreosken je važan za dijagnostiku i praćenje bolesnika te prediktivan za efikasnost terapije oktreotidom.