

Renal adenocarcinoma presenting as a spontaneous perirenal hematoma in a patient on warfarin therapy - case report and literature review

Tomić, Miroslav; Ulamec, Monika; Trnski, Davor; Dimanovski, Jordan; Spajić, Marija; Tomas, Davor; Krušlin, Božo; Spajić, Borislav

Source / Izvornik: **Collegium Antropologicum, 2013, 37, 629 - 632**

Journal article, Published version

Rad u časopisu, Objavljena verzija rada (izdavačev PDF)

Permanent link / Trajna poveznica: <https://urn.nsk.hr/urn:nbn:hr:105:107969>

Rights / Prava: [In copyright](#) / [Zaštićeno autorskim pravom.](#)

Download date / Datum preuzimanja: **2024-07-21**



Repository / Repozitorij:

[Dr Med - University of Zagreb School of Medicine Digital Repository](#)



Renal Adenocarcinoma Presenting As a Spontaneous Perirenal Hematoma in a Patient on Warfarin Therapy – Case Report and Literature Review

Miroslav Tomić¹, Monika Ulamec^{2,3}, Davor Trnski^{1,3}, Jordan Dimanovski¹, Marija Spajić⁴, Davor Tomas^{2,3}, Božo Krušlin^{2,3} and Borislav Spajić^{1,3}

¹ University of Zagreb, »Sestre milosrdnice« University Hospital Center, Clinical Department of Urology, Zagreb, Croatia

² University of Zagreb, »Sestre milosrdnice« University Hospital Center, »Ljudevit Jurak« Department of Pathology, Zagreb, Croatia

³ University of Zagreb, School of Medicine, Zagreb, Croatia

⁴ Karlovac General Hospital, Department of Pediatric Nephrology, Karlovac, Croatia

ABSTRACT

We are presenting a rare case of a spontaneous extensive perirenal hematoma caused by ruptured renal adenocarcinoma in a patient who was on warfarin therapy because she had atrial fibrillation and three myocardial infarctions. A 77-year-old woman was admitted to our department with acute right flank pain and hemorrhagic shock. The anamnestic data revealed no trauma and hematuria. Abdominal ultrasonography and computed tomography scan showed large retroperitoneal hematoma. The patient underwent urgent surgery and radical nephrectomy was performed. A large retroperitoneal hematoma was found originating from a ruptured renal neoplasm in the upper pole of the right kidney. The pathohistological diagnosis was chromophobe renal cell carcinoma. The clinical, diagnostic and therapeutic peculiarities of this rare condition are presented, along with the literature review on the topic.

Key words: chromophobe renal cell carcinoma, renal neoplasm, warfarin therapy, retroperitoneal hematoma, spontaneous rupture

Introduction

Spontaneous retroperitoneal haemorrhage may occur without any precipitating factors, specific underlying pathology or trauma¹. It may be caused by a variety of pathological conditions and it is most commonly seen in patients associated with anticoagulant therapy (warfarin), bleeding abnormalities and haemodialysis. The pathogenesis is unclear. It was assumed that diffuse occult vasculopathy and arteriosclerosis of small retroperitoneal vessels were responsible but such theories have not been substantiated on histology¹. Usually, retroperitoneal bleeding presents as a surgical emergency^{2,3} and with proper evaluation (US and CT), an accurate pre-operative diagnosis could be made. Spontaneous kidney rupture due to tumor is very rare and in most cases is caused by large angiomyolipoma. Occasional case reports

also describes cases of ruptured adenocarcinoma^{2,3}. Renal cell carcinoma represents over 90% of kidney-related malignancies and accounts for 2–3% of all adult neoplasms⁴. Chromophobe carcinoma is a histological subtype of renal cell carcinoma and has a better prognosis as compared to conventional renal cell carcinoma⁵. Here we are presenting a case of ruptured chromophobe renal cell carcinoma with consequent large retroperitoneal hematoma in a patient who was on warfarin therapy.

Case Report

A 77 year old female was sent from county hospital and admitted to our department with acute right flank

pain that lasted for 2 days. Trauma and hematuria were excluded. Anamnestic data revealed atrial fibrillation and 3 myocardial infarctions, the last one occurred three years ago and she was put on oral anticoagulant therapy (warfarin) and antihypertension medications. She was in the warfarin therapeutic range for myocardial infarction according to prothrombin time international normalized ratio (PT INR) (range 2.5–3.5)⁶ and was regularly checked her PT INR by a general practitioner. Upon admission she was in hemorrhagic shock. Physical examination revealed a palpable right flank mass. Initial laboratory findings showed a low hemoglobin 74 g/L, erythrocytes $3.21 \times 10^{12}/L$, prothrombin time (PT) 20% and PT INR 2.81. Immediately after admission, blood transfusion was given for anemia. Ultrasonography showed large inhomogeneous mass in the right upper retroperitoneal region, overlying the right kidney that could not be identified clearly. It was not possible to distinguish between solid renal mass and clotted blood. The abdominal CT scan showed irregular 14 x 9 centimeters large zone in the right perirenal space with minimal post contrast enhancement and hematoma or poorly vascularized renal

neoplasm were considered in the differential diagnosis (Figure 1a). The patient underwent urgent surgery and radical nephrectomy with evacuation of hematoma was performed. During surgery, a large retroperitoneal hematoma was found originating from a ruptured renal neoplasm located in the upper pole of the right kidney. Material was sent to the pathohistological analysis. Post-operative course was uneventful and patient was discharged on the 10th post-operative day. Clinical status of the patient 6 months after surgery is very good. She is free of the recurrence. On the pathohistology analysis kidney measured $12.5 \times 7 \times 4.5$ cm with large hematoma up to 6 cm that was visible in the upper pole. On the kidney cut surface directly beneath hematoma ruptured, relatively sharply delineated, grayish tumor up to 6.5 cm in the largest diameter was found (Figures 1b and c). On histological examination tumor was composed of solid nests and sheets of atypical cells with clear eosinophilic cytoplasm and clearly visible perinuclear halos (Figure 1d). Defect on the tumor surface was filled with fibrin and erythrocytes. In addition areas of hemorrhage within the tumor were also seen. Diagnosis of renal cell carcinoma

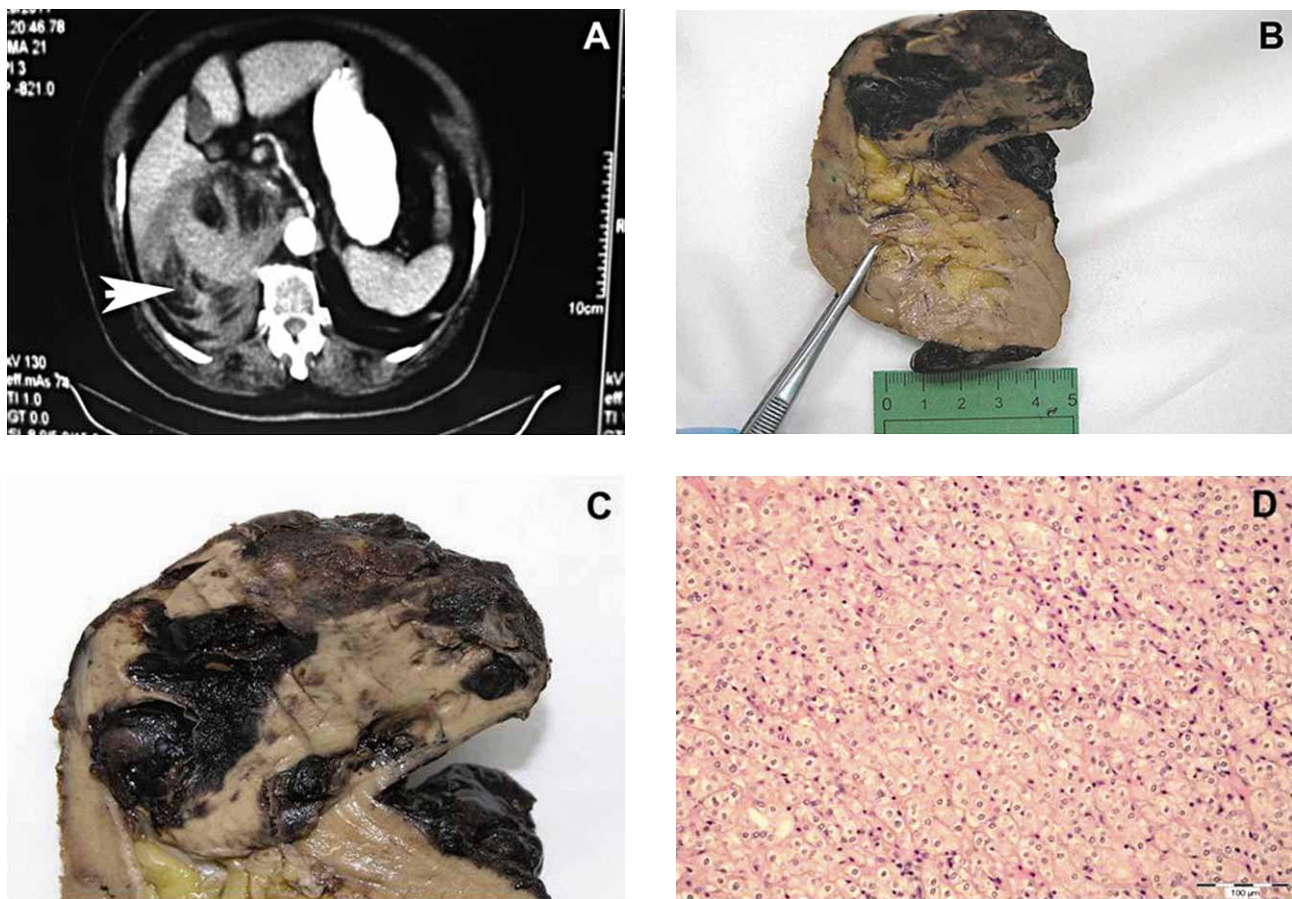


Fig. 1. a) The abdominal CT showed irregular 14 x 9 centimeters large zone in the right perirenal space with minimal post contrast enhancement (arrow). b) and c) On the kidney cut surface directly beneath hematoma, relatively sharply delineated, grayish, ruptured tumor up to 6.5 cm in the largest diameter was found. d) Pathohistological diagnosis was renal cell carcinoma, chromophobe histological subtype (H&E, x200).

noma, chromophobe histological subtype, Fuhrman nuclear grade 2, T1NxMx, was established⁷. According to new nuclear grading scheme for chromophobe renal cell carcinoma proposed by Paner et al.⁸ tumor was classified as nuclear grade 1.

Discussion

Chromophobe adenocarcinoma is classically characterized as an incidental finding and accounts for 4% of all kidney neoplasms, in patients with a mean age of 58 years⁹. Peyromaure et al.⁹ analyzed the presentation and outcomes of 61 patients with chromophobe adenocarcinoma. In their study, 68% were discovered incidentally. Of the rest of the patients, 18% had flank discomfort and 13% had gross hematuria⁹. None of them was in life threatening situation, in comparison with our patient who was in hemorrhagic shock at the time of admission. Spontaneous rupture of renal neoplasm is a rare and potentially lethal clinical condition¹⁰. Spontaneous rupture of adenocarcinoma is even less frequent. The incidence is between 0.3–0.6%¹⁰. Angiomyolipoma is the most common cause of the spontaneous rupture of the kidney¹¹. Zhang et al.¹¹, in meta analysis of etiology of spontaneous perirenal hemorrhage reported that the most common etiology was also angiomyolipoma (48%), closely followed by adenocarcinoma (43%) and vascular disease (17%) with dominant polyarteritis nodosa¹¹. Few cases of spontaneous rupture of leiomyosarcoma were also published in the literature. The patients on oral anticoagulant therapy (warfarin) are increasingly seeking for urologist care, mostly due to hematuria. The most common side effect of warfarin therapy is increased possibility of bleeding and prolonged bleeding. Recent Australian study showed that 49% of patients on oral anticoagulant therapy (warfarin, acetylsalicylic acid and clopidogrel) had no

urologic cause of hematuria¹². However, 51% of patients included 17% affected by bladder cancer, 7% by prostate cancer, 3% by upper tract malignancy, 21% by benign prostatic hyperplasia, 8% by infection and 11% with stone disease¹².

This report, to our knowledge, is the second such case reported in English literature. Brown et al.¹³ reported a case of spontaneous rupture of chromophobe adenocarcinoma treated with urgent exploratory laparotomy and radical nephrectomy. In their case it was about larger tumor, nuclear grade 2 according to Fuhrman. Their patient did not receive anticoagulant therapy unlike our patient. To our knowledge this is the first case of ruptured chromophobe renal cell carcinoma in patients on anticoagulant therapy. The treatment of a spontaneous non-traumatic renal rupture depends upon the diagnosis of hemorrhage, the determination of its cause and clinical status of the patient.

Therapeutic approaches are still controversial and variously described in the literature: radical nephrectomy, nephron sparing surgery, embolization, embolization followed by nephron sparing surgery or radical nephrectomy and conservative treatment are methods of choice. Many authors are recommending nephrectomy in terms concerning renal integrity and in the light of the prevalence of renal neoplastic lesions. In our case open surgery and radical nephrectomy was a first choice based on the patients' clinical status and a renal neoplasm found in CT scans. The most common side effect of warfarin therapy is increased possibility of bleeding. It is usually hematuria, nosebleed and bruising. Patients on warfarin anticoagulant therapy should be regularly and closely checked by their general practitioners because of that. It seems that in cases of spontaneous perirenal hematoma, renal neoplasm should be considered in differential diagnosis, especially in patients on warfarin therapy.

REFERENCES

1. CHAN YC, MORALES JP, REIDY JF, TAYLOR PJ, Int J Clin Pract, 62 (2008) 1604. DOI: 10.1111/j.1742-1241.2007.01494.x — 2. POLKEY HJ, VYNALEK WJ, Arch Surg, 26 (1933) 196. — 3. MCDUGAL WS, KURSH ED, PERSKY L, J Urol, 114 (1975) 181. — 4. CAMPBELL SC, NOVICK AC, BUKOWSKI RM, Renal tumors. In: WEIN AJ, KAVOUSSI LR, NOVICK AC, PARTIN AW, PETERS CA, Campbell-Walsh Urology (Saunders Elsevier, Philadelphia, 2007). DOI: 10.1016/B978-1-4160-6911-9.00049-9. — 5. POLASCIK TJ, BOTSWICK DG, CAIRNS P, Urology, 60 (2002) 941. DOI: 10.1016/S0090-4295(02)01825-3. — 6. ANSEL J, HIRSH J, HYLEK E, JACOBSON A, CROWTHER M, PALARETI G; AMERICAN COLLEGE OF CHEST PHYSICIAN, CHEST, 133 (6 Suppl 2008) 160S. DOI: 10.1378/chest.08-0670 — 7. LOPEZ-BELTRAN A, SCARPELLI M, MONTIRONI R, KIRKALI Z, Eur Urol, 49 (2006) 798. DOI: 10.1016/j.eururo.2005.11.035. — 8. PANER GP, AMIN MB, ALVARADO-CABRERO I, YOUNG AN, STRICKER HJ, MOCH H, LYLES RH, Am J Surg Pathol, 34 (2010) 1233. DOI: 10.1097/PAS0b013e3181e96f2a9. PEYROMAURE M, MISRAI V, THIOUNN N, ZERBIB M, FLAM T, DEBRÉ B, Cancer, 100 (2004) 1406. DOI: 10.1002/cncr.20128. — 10. PATEL NP, LAVENGOOD RW, J Urol, 119 (1978) 722. — 11. ZHANG JQ, FIELDING JR, ZOU KH, J Urol, 167 (2002) 1593. — 12. SATASIVAM P, REEVES F, LIN M, DARUWALLA J, CASAN J, LIM C, ROYCE PL, BJU Int, 110 (4 Suppl 2012) 80, DOI: 10.1111/j.1464-410X.2012.11622.x — 13. BROWN ET, PERLMUTTER AE, OLIVERIO B, WILLIAMS HJ, ZASLAU S, Can J Urol, 15 (2008) 4276.

B. Spajić

University of Zagreb, »Sestre milosrdnice« University Hospital Center, Department of Urology, Vinogradska cesta 29, 10000 Zagreb, Croatia

e-mail: borislav.spajic@kbcsm.hr

ADENOKARCINOM BUBREGA PREZENTIRAN KAO SPONTANI PERIRENALNI HEMATOM KOD PACIJENTA NA TERAPIJI WARFARINOM – PRIKAZ SLUČAJA I PREGLED LITERATURE

S A Ž E T A K

Predstavljamo rijedak slučaj spontanog i opsežnog perirealnog hematoma uzrokovanog rupturiranim kromofobnim adenokarcinomom kod pacijentice na terapiji warfarinom zbog fibrilacije atrijske i 3 preboljela infarkta miokarda. 77 godina stara žena primljena je na naš odjel s akutnim bolovima lumbalno desno i u hemoragijskom šoku. Anamneza nije otkrila traumu ili hematuriju. Abdominalni ultrazvuk i CT su pokazali veliki retroperitonealni hematoma. Pacijentica je podvrgnuta hitnom kirurškom zahvatu i učinjena je radikalna nefrektomija. Pronađen je veliki retroperitonealni hematoma koji je uzrokovan rupturiranim bubrežnom neoplazmom na gornjem polu desnog bubrega. Patohistološka dijagnoza je bila kromofobni adenokarcinom bubrega. Kliničke, dijagnostičke i terapijske osobitosti ovog rijetkog slučaja su prikazane, uz pregled literature o toj temi.