

Application of the amniotic membrane extract (AMX) for the persistent epithelial defect (PED) of the cornea

Kordić, Rajko; Popović Suić, Smiljka; Jandroković, Sonja; Kalauz, Miro; Kuzman, Tomislav; Škegro, Ivan; Jukić, Tomislav

Source / Izvornik: **Collegium Antropologicum, 2013, 37, 161 - 164**

Journal article, Published version

Rad u časopisu, Objavljena verzija rada (izdavačev PDF)

Permanent link / Trajna poveznica: <https://urn.nsk.hr/urn:nbn:hr:105:534988>

Rights / Prava: [In copyright](#) / [Zaštićeno autorskim pravom.](#)

Download date / Datum preuzimanja: **2025-01-28**



Repository / Repozitorij:

[Dr Med - University of Zagreb School of Medicine
Digital Repository](#)



Application of the Amniotic Membrane Extract (AMX) for the Persistent Epithelial Defect (PED) of the Cornea

Rajko Kordić, Smiljka Popović Suić, Sonja Jandroković, Miro Kalauz, Tomislav Kuzman, Ivan Škegro and Tomislav Jukić

University of Zagreb, Zagreb University Hospital Centre, Department of Ophthalmology, Zagreb, Croatia

ABSTRACT

A lot of pathological conditions could provoke damaging of the innervations of the cornea and lead to persistent epithelial defect (PED). AMX is lyophilized preparation of amniotic membrane (AM), which contains biological components and efficacy of AM for treatment of the corneal surface defects. In processing all the substances essential for biological effects of AM are preserved (growth factors, neutrophins, interleukins, receptors, fibronectins and different types of collagen). A patient can apply AMX as eye drops by himself in his home, thus avoiding surgical procedure. We presented two patients with PED; we treated them with eye drops of AMX, 2 drops every hour during day time. There was observed healing effect by reducing epithelial defect. Almost after a second day of application, and after 1-2 week period PED that persisted for weeks healed completely.

Key words: Amniotic membrane extract, persistent epithelial defect, neurotrophic keratopathy

Introduction

Epithelial integrity and sensitive innervations are essential factors in preserving surface of the eye in proper functional condition. A lot of pathological conditions could provoke damaging of the innervations of the cornea and lead to persistent epithelial defect (PED). As an etiological pattern, it could be found viral ulcerations, endocrine and immunological disturbance and chemical burns as well. In some cases trigeminal lesion because of brain tumors leads to PED¹⁻³. Neurotrophic keratopathy is degenerative disease characterized by decreased corneal sensitivity and poor corneal healing. This often results in corneal ulceration. For better understanding of the pathophysiological pattern of the sterile corneal ulceration, mechanisms of epithelial, stromal as well and tear film should be considered. Enzyme, cytokines and corneal innervations are important for maintaining cornea healthy^{4,5}.

Different treatment strategies are in usage consists of topical medications and surgical approach as well (occlusion of the puncta, tarsoraphy, limbal cell transplantation and amniotic membrane transplants)⁶. For PED treatment there are a great number of new substances containing different growth factors that stimulate regeneration of the corneal epithelium. Mainly, those are neu-

ropeptides (nerve growth factor, epidermal growth factor, pentadecapeptid) usually applying topically^{6,7}.

Cryopreserved amniotic membrane (AM) is applied for covering damaged corneal surface. Certain quantities of substances are released to damaged tissue and after few days all the cells of AM do not survive. It was observed that using multilayer of AM is more efficacious than one layer of AM, in stimulating healing process of stromal ulcers. It is supposed that this better action is caused by releasing more quantity of total factors promoting healing process of the tissue⁸. This observation was a rationale for preparing of lyophilized extract of AM (amniotic membrane extract, AMX) which contains biological properties and efficacy of AM, but it is applied as eye drops without surgery. AMX is newly launched preparation and is distributed by *keera.eu*.

Case Report

Case 1

We present a female patient of 27ys, with persistent epithelial defect (PED) of the cornea of the right eye. According to Mackie classification, she has stage 1–2 of the

neurotrophic keratopathy⁹. Four months before coming to Eye department, a pontocerebellar Schwannoma was operated and she suffered of hemi facial hypoesthesia on right side and PED of the right eye. She was treated in postoperative period with antibiotic eye drops and ointments, antiviral drugs and artificial tear drops. On admission BCVA was 0.1, oval epithelia corneal defect was present (about 4 mm) with slight stromal swelling, in the anterior chamber slight reaction was observed, iris was without reaction, lens was clear and vitreous body and retina were normal. Slight redness of the eye was noted. Corneal sensitivity was reduced; lacrimation was by Schirmer 15/18. Corneal smears were negative.

We began treatment with AMX eye drops on the basis two drops every hour during daytime. Figure 1, showing oval epithelial defect is well seen, a slight stromal swelling is present. On the Figure 2, defect is well stained with Fluorescein. After 12 days of treatment PED healed (Figure 3), but a mild grade of stromal haze was present (Figure 4).

Case 2

Second case is a male patient, 58ys, with persistent epithelial defect (PED) and mild sign of stromal melting of the cornea of the right eye. He had stage 2–3 neurotrophic keratopathy according to Mackie classification⁹. One year before admission to Eye clinic a pontocerebellar Schwannoma was operated on the right side. He suffers of hemi facial hypoesthesia on the right side. His right eye was red for weeks but he did not feel any discomfort. Both eyes are 5 diopters of myopia, right eye was red

with oval 3mm epithelial defect and mild sign of central stromal melting, but corneal smears were negative. BCVA was 0.1 on the right eye and 1.0 on the left eye. Descemet folding was observed on the right eye and slight reaction in the anterior chamber. Corneal sensitivity of the right eye was reduced. Lacrimation was normal. Vitreous body and retina were normal. Left eye was normal.

We began treatment with AMX eye drops on the basis two drops every hour during daytime. Figure 5, oval epithelial defect is well seen, a slight stromal swelling and melting is present in the centre. Figure 6, defect is well stained with Fluorescein. After 6 days of treatment epithelia defect healed and stromal swelling reduced (Figures 7 and 8.)

Discussion

Amniotic membrane transplants are applied for covering of the damaged surface of the cornea. It was observed promoting effect in healing process of multilayer AM transplants for deeper stromal lesions (ulcers)⁸. Lyophilized extract of the AM (AMX) contains all therapeutic features of the cryopreserved AM. Its possibility for protracted topical application as eye drops gives advantage compared to surgical approach, because of delivering more promoting substances during a longer period to the damaged cornea. For PED treatment there are a great number of new substances containing different growth factors that stimulate regeneration of the corneal epithelium. Mainly those are neuropeptides (nerve growth factor, epidermal growth factor, pentadecapeptid) usually applying topically^{6,7}.

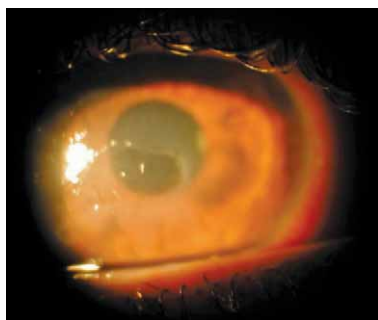


Fig. 1. Persistent epithelial defect (Case 1).

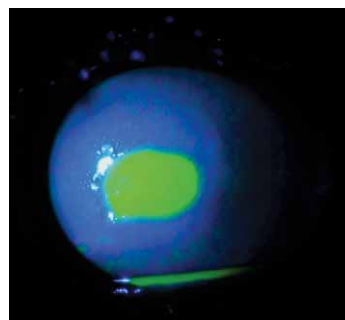


Fig. 2. Fluorescein staining of the corneal epithelial defect (Case 1).

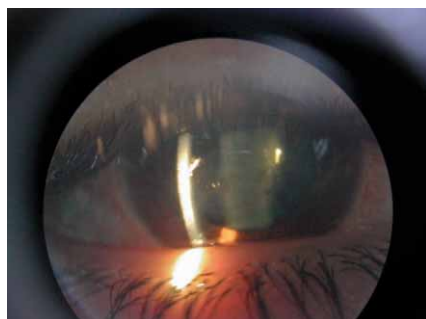


Fig. 3. Healed epithelial defect after 12 days of treatment with AMX (Case 1).

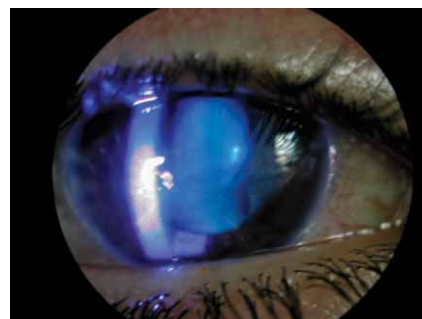

Fig. 4. After 12 days of treatment with AMX, no Fluorescein staining of the corneal surface (Case 1).

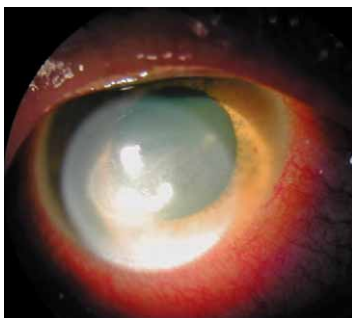


Fig. 5. Persistent epithelial defect with stromal swelling and mild sign of stromal melting (Case 2).

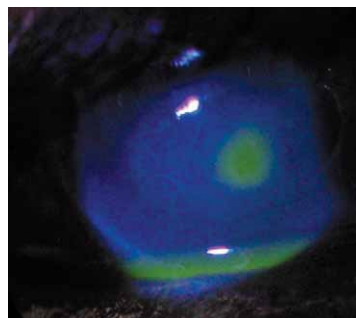


Fig. 6. Persistent epithelial defect with stromal swelling and mild sign of stromal melting stained with Fluorescein (Case 2).

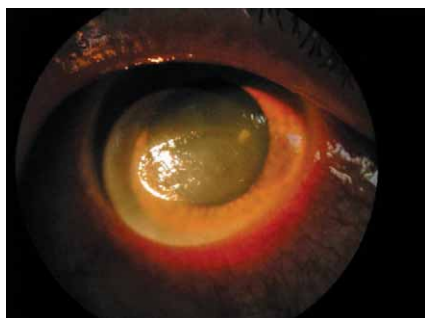


Fig. 7. After 6 days of treatment with AMX, corneal surface healed but with mild stromal haze (Case 2).

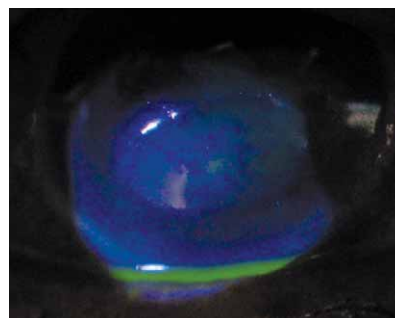


Fig. 8. After 6 days of treatment with AMX, corneal surface healed but with mild stromal haze and no Fluorescein staining of the corneal surface (Case 2).

In our patients were applied lyophilized extract of amniotic membrane (AMX), topically as eye drops, every hour during day time. There was observed healing effect by reducing epithelial defect almost after a second day of application, and after 1–2 week period PED that persisted for weeks healed completely. AMX is lyophilized preparation of AM which contains biological components and efficacy of AM for treatment of the corneal surface

defects. In processing all the substances essential for biological effects of AM are preserved (growth factors, neutrophins, interleukins, receptors, fibronectin and different types of collagen). A patient can apply AMX as eye drops by himself in his home thus avoiding surgical procedure.

REFERENCES

1. GOULD HL, Eye, Ear, Nose & Throat Monthly, 46 (1967) 1406. —
2. KENYON KR, Ophthalmology, 89 (1982) 44. — 3. LIESEGANG TJ, Ophthalmology, 92 (1985) 316. — 4. BAZAN HE, Exp Eye Res, 80 (2005) 453. — 5. BONINI S, RAMA P, OLZI D, LAMBIASE A, Eye, 17 (2003) 989. — 6. BONINI S, LAMBIASE A, RAMA P, Ophthalmology, 107 (2000) 1347. — 7. LAZIĆ R, GABRIĆ N, DEKARIS I, Coll Antropol, 29 (1) (2005) 321. — 8. PRABHASAWAT P, Br J Ophthalmol, 85 (2001) 1455. — 9. KORDIĆ R, KUZMAN T, POPOVIĆ SUIĆ S, KALAUZ M, ČURKOVIĆ T, Acta Clin Croat. 46 (Suppl) (2007) 117.

R. Kordić

University of Zagreb, Zagreb University Hospital Centre, Department of Ophthalmology, 10000 Zagreb, Kišpatičeva 12, Croatia

e-mail: kordicr@net.hr

PRIMJENA EKSTRAKTA AMNIJSKE MEMBRANE (AMX) ZA PERZISTIRAJUĆI EPITELNI DEFJEKT (PED) ROŽNICE

S A Ź E T A K

Mnoga patološka stanja mogu uzrokovati oštećenje inervacije rožnice i dovesti do perzistirajućeg epitelnog defekta (PED). AMX je liofilizirani preparat amnijske membrane (AM), koji zadržava biološke komponente i efikasnost AM-e za liječenje površinski defekata rožnice. U preradi su sačuvane sve bitne supstance za biološko djelovanje AM-e (faktori rasta, neutrofini, interleukin, receptori, fibronektin i razni tipovi kolagena). Bolesnik može primjenjivati AMX u obliku kapi za oči, sam kod kuće, izbjegavajući kirurški postupak. Prikazali smo dva bolesnika s PED-om koji su liječeni kapima AMX-a, 2 kapi svaki sat tokom dana. Opaženo je ubrzano cijeljenje smanjenjem epitelnog defekta već nakon dva dana liječenja, a nakon 1–2 tjedna, PED koji je trajao tjednima potpuno je zacijelio.