

Autonomic dysfunction in multiple sclerosis presenting with postural orthostatic tachycardia

Adamec, Ivan; Ozretić, David; Habek, Mario

Source / Izvornik: *Acta Neurologica Belgica*, 2013, 113, 337 - 339

Journal article, Accepted version

Rad u časopisu, Završna verzija rukopisa prihvaćena za objavljivanje (postprint)

<https://doi.org/10.1007/s13760-012-0158-2>

Permanent link / Trajna poveznica: <https://um.nsk.hr/um:nbn:hr:105:335854>

Rights / Prava: [In copyright](#) / [Zaštićeno autorskim pravom](#).

Download date / Datum preuzimanja: **2024-09-07**



Repository / Repozitorij:

[Dr Med - University of Zagreb School of Medicine
Digital Repository](#)





Središnja medicinska knjižnica

Adamec I., Ozretić D., Habek M. (2013) *Autonomic dysfunction in multiple sclerosis presenting with postural orthostatic tachycardia.* Acta Neurologica Belgica, 113 (3). pp. 337-9. ISSN 0300-9009

<http://www.springer.com/journal/13760>

<http://link.springer.com/journal/13760>

<http://dx.doi.org/10.1007/s13760-012-0158-2>

<http://medlib.mef.hr/2023>

University of Zagreb Medical School Repository

<http://medlib.mef.hr/>

Autonomic dysfunction in multiple sclerosis presenting with postural orthostatic tachycardia

Ivan Adamec¹, David Ozretić², Mario Habek^{1,3}

¹ University Hospital Center Zagreb, Department of Neurology, Referral Center for Demyelinating Diseases of the Central Nervous System, Zagreb, Croatia

² University Hospital Center Zagreb, Department of Radiology, Zagreb, Croatia

³ School of Medicine, University of Zagreb, Department of Neurology, Zagreb, Croatia

Corresponding author:

Mario Habek, MD, PhD
University Department of Neurology
University Hospital Center Zagreb
Kišpatićeva 12
HR-10000 Zagreb
Croatia
Phone/Fax: +38512376033; e-mail: mhabek@mef.hr

Word count: 787

Number of references: 6

Number of figures: 2

Authors' contributions

Study concept and design: Adamec and Habek. Acquisition of data: Adamec, Ozretić, Zadro and Habek. Analysis and interpretation of data: Adamec, Ozretić, Zadro and Habek. Drafting of the manuscript: Adamec. Critical revision of the manuscript for important intellectual content: Adamec, Ozretić, Zadro and Habek. Administrative, technical, and material support: Adamec, Ozretić, Zadro and Habek.

Conflict of interest statement: There is no conflict of interest.

Source of funding: None.

Key words: postural orthostatic tachycardia, multiple sclerosis, thalamus

Introduction

Postural orthostatic tachycardia syndrome (POTS) is an autonomic disorder characterized by an exaggerated increase in heart rate that occurs during standing, without orthostatic hypotension.

We report a patient with postural orthostatic tachycardia in a context of multiple sclerosis (MS).

Case report

A 37-year-old woman presented with hemiparesthesiae on the left side of the body.

Neurological examination revealed left sided hemihypoesthesia. Brain MRI revealed six T2 hyperintensive lesions, the largest one in the right thalamus with postcontrast enhancement.

CSF analysis showed positive IgG oligoclonal bands (OCB), without OCB in the serum.

Syncope occurred during the lumbar puncture so tilt-table test was performed. Immediately after the tilt, excessive heart rate rise >30 beats/minute occurred, persisting during the whole tilt phase, with no change in the blood pressure values. In the 12th minute of the tilt phase a loss of blood pressure occurred (minimal values 68,9/43,8 mmHg) with the decrease in pulse to 40,0 beats/min, which was consistent with mixed type of vasovagal syncope. Average heart rate in the lying position was 59,8 beats/min, and in the upright position 106,2 beats/min (Figure 1). These findings were consistent with postural orthostatic tachycardia. She never complained on tachycardia, exercise intolerance, lightheadedness, extreme fatigue, headache and mental clouding.

Laboratory tests including serum and CSF serology for *Borrelia burgdorferi* and *Syphilis*, and serum serology for viruses (HBV, HCV and HIV) were all negative. Immunological tests (antistreptolysin titre, rheumatoid factor, anti-DNA antibody, antinuclear antibody,

antineutrophil cytoplasmic antibody, angiotensin-converting enzyme) and thyroid function tests were all within normal range.

Treatment with 1000 mg of intravenous methylprednisolone was started, but on the third day of treatment the patient developed weakness of the left extremities. Neurological examination showed muscle strength of the left extremities 3/5 with brisk reflexes and positive Babinski sign ipsilaterally. She was not able to walk without help. Repeated brain MRI showed increased volume of the right thalamic lesion which now involved right internal capsule (Figure 2).

We repeated intravenous methylprednisolone (1000 mg through 5 days) with no improvement. We then proceeded to plasma exchange, 5 cycles. This therapy led to marked improvement, neurological examination now showed muscle strength in the left forearm and left leg 4/5, and she was able to walk without help for 100 m.

Follow up tilt table test showed increase in heart rate of <30 beats/min, with no change in blood pressure without syncope. Average heart rate in the lying position was 64.4 beats/min, and in the upright position 89.8 beats/min (Figure 1).

Three months later the patient developed right hand weakness. Repeated brain MRI showed 3 new demyelinating lesions. At this point she fulfilled the revised McDonald's criteria for multiple sclerosis [1].

Discussion

Pathological response to orthostatic provocation is frequent in MS, occurring in up to 63% of patients [2]. Despite this, POTS has rarely been reported in MS [2,3] One series described 9

MS patients with POTS, 2 patients developed MS after the diagnosis of POTS, and 7 patients developed POTS sometime after the diagnosis of MS [3]. Authors of this study did not find any correlation between MS symptoms or relapses with POTS. On the other hand we have recently reported that POTS frequently occurs MS and showed that it is associated with an MS relapse [2].

POTS can be divided into two categories: neuropathic POTS and central hyperadrenergic POTS [4]. Underlying mechanism of central hyperadrenergic POTS is excessive sympathetic nervous outflow from the brain, so it can be presumed that this type of POTS is found in MS patients, as MS is a disease of the central nervous system. Different central nervous system parts (parabrachial nucleus in the pons, thalamus, hypothalamus, amygdala, insula) are involved in the autonomic functions like heart rate. Tachycardia may be produced by either increased sympathetic activity or decreased parasympathetic activity. Tachycardic response is mediated via sympathetic outflow from the rostral ventrolateral medulla that is modulated by excitatory and inhibitory, more central inputs [5]. Specifically, a positive correlation was found in the left hypothalamus, left amygdala, right anterior hippocampus, and right dorsomedial and dorsolateral prefrontal cortex, while a negative correlation was found in the right parabrachial nucleus/locus ceruleus, left periaqueductal gray matter, right posterior hippocampus, right mediodorsal thalamus, left caudate and right septal nuclei, left posterior insula, and right medial temporal gyrus [6]. Therefore the probable mechanism of postural orthostatic tachycardia in our patient is thalamic lesion, which by inhibition of negative effect of right mediodorsal thalamic nucleus on heart rate could produce tachycardia. Another supportive finding for this association is reversal of tachycardia after MS relapse treatment. In conclusion, autonomic dysfunction in MS is not rare and should be actively searched for. Early recognition and proper management may help to improve the symptoms and patients quality of life.

References

1. Polman CH, Reingold SC, Banwell B, Clanet M, Cohen JA, Filippi M, Fujihara K, Havrdova E, Hutchinson M, Kappos L, Lublin FD, Montalban X, O'Connor P, Sandberg-Wollheim M, Thompson AJ, Waubant E, Weinshenker B, Wolinsky JS. (2011) Diagnostic criteria for multiple sclerosis: 2010 revisions to the McDonald criteria. *Ann Neurol* 69:292-302.
2. Adamec I, Bach I, Barusic AK, Mismas A, Habek M. (2012) Assessment of prevalence and pathological response to orthostatic provocation in patients with multiple sclerosis. *J Neurol Sci*, <http://dx.doi.org/10.1016/j.jns.2012.10.006>
3. Kanjwal K, Karabin B, Kanjwal Y, Grubb BP. (2010) Autonomic dysfunction presenting as postural orthostatic tachycardia syndrome in patients with multiple sclerosis. *Int J Med Sci* 7:62-7.
4. Raj SR. (2006) The Postural Tachycardia Syndrome (POTS): pathophysiology, diagnosis & management. *Indian Pacing Electrophysiol J* 6:84-99.
5. Dampney RA, Coleman MJ, Fontes MA, Hirooka Y, Horiuchi J, Li YW, Polson JW, Potts PD, Tagawa T. (2002) Central mechanisms underlying short- and long-term regulation of the cardiovascular system. *Clin Exp Pharmacol Physiol* 29:261–268.
6. Napadow V, Dhond R, Conti G, Makris N, Brown EN, Barbieri R. (2008) Brain correlates of autonomic modulation: combining heart rate variability with fMRI. *Neuroimage* 42:169-77.

Figures

Figure 1. Upper panel: Results of the initial tilt-table test, before therapy. Upper line shows continuous heart rate monitoring; lower line shows continuous blood pressure monitoring. Note the increase heart rate after the tilt (vertical red line) >30 beats/minute. Arrow shows abrupt fall in heart rate accompanied with the fall in blood pressure and syncope. Lower panel: Results of the tilt-table test, after therapy. Upper line shows continuous heart rate monitoring, lower line shows continuous blood pressure monitoring. Note the increase heart rate after the tilt (vertical red line) <30 beats/minute, without fall in the blood pressure.

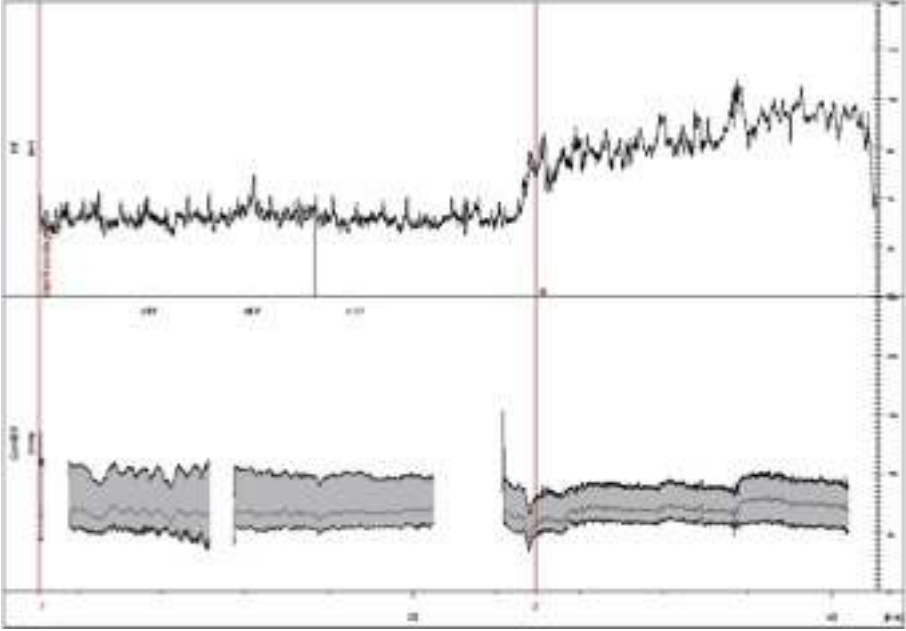
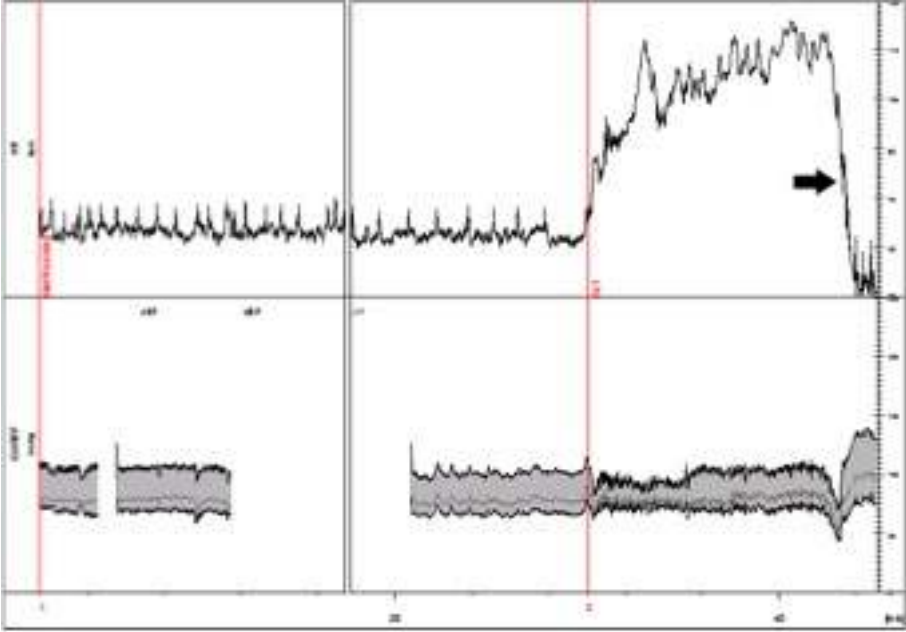


Figure 2. Brain MRI, T2 transversal image, showing right thalamic demyelinating lesion with the involvement of the right internal capsule.

