

'The lasso technique' - a simple intracorporeal two-port laparoscopic appendectomy: technical considerations and review of four other intracorporeal two-port techniques

Augustin, Goran; Matošević, Petar; Majerović, Mate

Source / Izvornik: **Hepatogastroenterology, 2013, 60, 1058 - 1062**

Journal article, Accepted version

Rad u časopisu, Završna verzija rukopisa prihvaćena za objavljivanje (postprint)

Permanent link / Trajna poveznica: <https://um.nsk.hr/um:nbn:hr:105:499054>

Rights / Prava: [In copyright](#) / [Zaštićeno autorskim pravom.](#)

Download date / Datum preuzimanja: **2024-07-13**



Repository / Repozitorij:

[Dr Med - University of Zagreb School of Medicine
Digital Repository](#)





Središnja medicinska knjižnica

Augustin G., Matošević P., Majerović M. (2013) *'The lasso technique' - a simple intracorporeal two-port laparoscopic appendectomy: technical considerations and review of four other intracorporeal two-port techniques.* Hepatogastroenterology, 60 (125). pp. 1058-62. ISSN 0172-6390

<http://medlib.mef.hr/2369>

University of Zagreb Medical School Repository

<http://medlib.mef.hr/>

Title: 'The Lasso technique' - A Simple Intracorporeal 2-port Laparoscopic Appendectomy: Technical Considerations and Review of Four Other Intracorporeal 2-port Techniques

Goran Augustin, Petar Matosevic, Mate Majerovic

Department of Surgery, University Hospital Center Zagreb and School of Medicine
University of Zagreb, Zagreb, Croatia

Short running title: Intracorporeal 2-port appendectomy

Goran Augustin, MD., PhD (*corresponding author*)

Department of Surgery, Division of Gastrointestinal Surgery
University Hospital Center Zagreb
Zagreb, Croatia
Mob: +385915252372
E-mail: augustin.goran@gmail.com

Petar Matošević, MD

Department of Surgery, Division of Gastrointestinal Surgery
University Hospital Center Zagreb
Zagreb, Croatia

Mate Majerović, MD, PhD, Prof.

Department of Surgery, Division of Gastrointestinal Surgery
University Hospital Center Zagreb
Zagreb, Croatia

ABSTRACT

Background/Aims: To decrease surgical trauma and scar formation we present intracorporeal 2-port procedure in selected patients.

Methodology: Supraumbilical 5mm port is used for the laparoscope. Suprapubic 12mm port is in the midline or left paramedian position below the underpants line. Pretied loop suture is tied around the base, 1-2 cm distally from the origin of the appendix, or below the macroscopically changed appendix. Endoclose is introduced 1-2 cm cranially from the location of appendiceal base and the endoloop is exteriorized and the appendix elevated. Harmonic scalpel is used for dissection and skeletonization and the appendix is divided with 45 mm linear cutting stapler.

Results: Two-port appendectomy was attempted in 11 consecutive patients. In 3 patients operation was converted to open procedure and in 2 patients the third port was needed. Finally 6 (54%) patients were operated with the similar operating time (36-51 min) as standard 3-port technique with the same postoperative pain and bowel function recovery. The postoperative stay ranged 2 - 4 days. There was one wound infection of 12-mm port.

Conclusions: This intracorporeal 2-port appendectomy in selected patients does not prolong operation time and further improves the minimal invasiveness and contributes to excellent cosmetic results.

KEY WORDS: Laparoscopic appendectomy; Technique; Intracorporeal; Cosmetic results; Minimally invasive surgery

INTRODUCTION

Today, it could be stated that laparoscopic appendectomy is the gold standard for experienced laparoscopic surgeons. The procedure was introduced in 1983 by gynecologist Kurt Semm (1). Since then the 'classic' laparoscopic technique with 3 (or even 4) ports was modified and improved to produce minimal tissue trauma with faster recovery and better cosmesis. Today, there are several directions established for minimizing this minimal invasive surgical procedure: 1) decreasing the number of ports – two or single port appendectomy, 2) decreasing the port diameters – needlescopic appendectomy and 3) NOTES appendectomy.

Some procedures such as single port (with various modifications and terms) or NOTES (real or hybrid) procedures require technical equipment and trained surgeons which is too expensive especially for smaller hospitals with low budget.

Thus we present one modification of 2-port intracorporeal laparoscopic appendectomy which we termed *Lasso technique* and which can be done with standard laparoscopic equipment (with addition of suture grasper used for laparoscopic hernia repair) but produces less surgical trauma and better cosmesis than „classic“ 3-port technique.

METHODOLOGY

In a prospective study, 11 consecutive patients were assigned to undergo 2-port intracorporeal laparoscopic appendectomy for presumed appendicitis at Clinical Hospital Center Zagreb in September and October of 2009. The same surgeon performed all operations.

The most important steps are described. After induction of general anesthesia and urinary catheterization, 5-mm umbilical or supraumbilical incision is created and a carbon

dioxide (12 mmHg) pneumoperitoneum is induced with a Veress needle. Next, 5-mm trocar is introduced for the placement of 0° or 30° laparoscope. A second 12-mm trocar is introduced through the midline (or left paramedian) suprapubic incision (below the pants line) and the peritoneal cavity is inspected.

In this technique appendix should be identified with only one instrument through 12-mm port. Appendix could be covered with omentum (**Figure 1**) or in any unfavorable position. After identification it is grasped for mesoappendix and elevated to the anterior abdominal wall for estimation of adequate exposure of the mesoappendix and appendiceal junction and relative mobility of the cecum (**Figure 2**). Then the appendix is directed toward 12-mm suprapubic port for easier placing of pretied loop ligature, Endoloop ligature (Ethicon, Johnson&Johnson, USA). Endoloop is introduced through suprapubic port and tied around the base, 1-2 cm distally from the origin of the appendix, or below the macroscopically changed appendix to minimize the possibility of appendiceal rupture and spillage of its contents (**Figure 3**). If the appendix cannot be directed toward 12-mm port or there is technical difficulty in seizing the appendix (*Lasso technique*) then the bowel clamp or forceps is introduced through the same port for assistance. The instrument is pulled through endoloop, the appendix is grasped and the endoloop tied down over the instrument. Then the Suture Passer (Gore Medical, USA) or Endo Close (Autosuture, Covidien, USA) is introduced above the appendiceal origin or 1-2 cm cranially to its base. The free end of the pretied loop suture is placed in the suture grasper (**Figure 4**). This is important because when pretied loop suture near appendix is seized one cannot pull it through abdominal wall because it sticks. Suture passer is sharp and can be passed through abdominal wall directly, but if Endo Close is used the skin should be punctured with wider needle. Then the appendix is elevated by pulling the endoloop through the skin until the mesoappendix and the base of the appendix are exposed adequately (**Figure 5**). Ultracision harmonic scalpel (Ethicon, Johnson&Johnson, USA) is

introduced and fired as much times as needed to divide the mesoappendix. Periodically one can check surrounding structures and adequate exposure with the instrument thus eliminating the possibility to damage important surrounding structures inadvertently. The length of this part of the operation depends on (1) the adequate exposure because elevated appendix cannot be relocated then (2) on width of the mesoappendix and (3) on the location of the surrounding structures which can complicate dissection and division. The ultrasonic scalpel could be used for dissection to eliminate the loss of time during changing of the instruments. After complete skeletization of the appendix the 45 mm linear stapler-cutter is introduced and fired at the junction of appendix with the cecum (**Figure 6**). After division the appendix is hanging on the endoloop. In this part of the operation control of the hemorrhage and the suction/irrigation could be used if needed. If not bulky the appendix can be exteriorized with the grasper through the 12 mm port. If bulky, Endocatch Gold (Covidien, Autosuture, USA) is introduced. This model is the most suitable because it does not require the use of other instrument (and another laparoscopic port) for pulling the stripe for closing the bag (**Figure 7**). In this part of the operation it is important to bring down the appendix so the bag could enclose it completely. After the appendix is put in the bag and closed the instrument and the bag are exteriorized through the suprapubic 12-mm port.

RESULTS

Five of 11 operations in the study were not completed as 2-port appendectomy. In three male patients (27, 41, and 49 years old) operation was converted to open procedure (two inferior midline incisions due to perforated appendicitis with abscess in Douglas pouch and one gridiron incision due to gangrenous base which was closed atypically) and in 2 patients (56 year old male and 70 year old female) the third port was needed because of difficulties due to

subserosal retrocoecal/retroperitoneal localization. Finally 6 (54%) patients were operated with intracorporeal 2-port technique (2 males: 20 and 27 years old; 4 females: 13, 14, 20 and 24 years old). The operative time range for 2-port technique was 37-54 min. The postoperative stay ranged from 2 to 4 days for patients operated by 2- or 3-port technique. Differences between patients who were operated with 2- and 3-port appendectomy in terms of length of hospital stay and operating time was not statistically significant. Patient with conversion to gridiron incision was hospitalized for 4 days and patients with Douglas pouch abscesses 9 days. All histologically analyzed specimens confirmed appendicitis.

Postoperative median follow-up period was 3 months. There was one early postoperative complication in patients with 2-port technique. It included wound infection of suprapubic 12-mm port where gangrenous appendix was extracted. The wound was left open and treated with regular wound and dressing changes. One patient had pain in the lower right quadrant one month after the operation and visited ER but there was no pathology found and the pain subsided after 2 days. There was no specific postoperative analgesic protocol, and this was led by patient need. All patients were managed with nonsteroidal antiinflammatory drugs (NSAIDs). Patients with 2- or 3-port technique required 3-4 doses while patient with gridiron incision required analgesia up to third postoperative day. Both patients with midline incision did not require analgesia after 4th postoperative night. Cosmetic results of the port and needle insertion sites were excellent also confirmed by patients after one and three months. Only supraumbilical was slightly visible because 12 mm incision was below pants line (**Figure 8A and 8B**).

DISCUSSION

First laparoscopic appendectomy was performed by Kurt Semm and published in 1983 (1). The first report in children was in 1991, when Ure et al presented a prospective series of 43 patients (2). Today most surgeons offer laparoscopic appendectomy as first line treatment of acute appendicitis because of its clear advantages including decreased pain, fewer postoperative complications, decreased length of hospitalization, better intra-abdominal visualization, and better cosmesis (3). The 'classic' laparoscopic technique requires 3 ports (trocars): the first for visualization; the second for dissection and subsequent transection; and the third for retraction of the appendix. With the current tendency toward minimizing minimally invasive surgery, new techniques have been developed and are still further developing and improving.

There are several directions for minimizing this minimally invasive surgical procedure: 1) decreasing the number of ports, 2) decreasing the port diameters - needlescopic appendectomy and 3) NOTES appendectomy. In this paper we will discuss only the development and modifications of 2-port laparoscopic techniques. We must stress that the terms of techniques with the number of ports should be used cautiously. In a single port techniques a 'system' includes one port but with 2, 3 or even 4 working channels. Thus technically it could be debated is it a one or several port technique. The cumulative length of (skin and abdominal wall) incisions or inflammatory response should be measured to compare invasiveness. Another direction was to hide the incisions below the bikini (pants) line despite of number of ports (4).

The initial report of a 2-port appendectomy was described by Schier in 1998 in children (5). Schier used the first port for a rigid endoscope with a working channel for dissection and transection of the appendix and the second port was for retraction. A similar technique were described in adults (6). These techniques are termed *extracorporeal* laparoscopic appendectomies which are performed with exteriorization of the appendix

through the largest port. The procedure is then completed in traditional open technique extracorporeally. Thus these procedures should be termed 'laparoscopically *assisted* appendectomies'. These methods eliminate the need for the third trocar because skeletization and division of appendix are made extracorporeally. These procedures are mostly done in children because of cecal mobility and smaller distance between base of the appendix and (mostly umbilical) exteriorizing port (7,8). Another group of techniques are „true“ 2-port laparoscopic appendectomies. These operations include complete performance of appendectomy intracorporeally thus are termed *intracorporeal*.

There are several technical modifications for *intracorporeal* 2-port technique. All these techniques are modifications of one basic principle used during modifications of laparoscopic cholecystectomies (9, 10). One modification included the „pulley system“ (11). To allow retraction of the appendix without an instrument through a trocar, a „pulley system“ within the abdominal cavity is created with a suture mounted as a loop tied as an air knot to the anterior abdominal wall, just cephalad and lateral of the base of the appendix. This loop is subsequently used as an axle. Then, a pretied suture placed on the appendix is passed through the previously created loop and then through the 12-mm port to the outside of the abdomen.

The second technique, similar to ours, was published by Sato et al. but with slightly larger and more visible scar (12). In this needle loop retractor, a stainless steel wire is placed within a needle having a diameter of 2 mm, and the appendix is grasped by tightening this loop. It is a „virtual“ third port which does not leave any scar.

Yeung et al. made the third modification (13). Intravenous cannula is inserted through abdominal wall; the needle is removed, leaving the plastic cannula *in situ* as the future knot pusher. Air leak is negligible or the cannula can be capped if needed. One end of a ligature is introduced via the catheter into the peritoneum. The intraperitoneal end is grasped and pulled

out through one of ports. A sliding knot is constructed extracorporeally to fashion a suture loop. Pulling gently at the other end will return the loop back into the peritoneum.

In the forth (transabdominal sling suture) technique which is a single port but with 2 channels (one for laparoscope), the appendix is grasped and dissected from the surrounding tissues with a single dissector or grasper and elevated. With a percutaneously inserted suture (with needle) from the right lower quadrant into the peritoneal cavity, the appendix was pulled toward the abdominal wall after passing the suture through the mesoappendix (14). The problem was with obese patients when larger needles are needed. Probably the problem would be in morbidly obese. In one patient sling suture cut the mesoappendix which was solved with another suture. The problem could be if the suture cut the appendicular artery what fortunately did not happen.

The first technique described is somewhat technically difficult and the fourth is by our opinion somewhat hardly controllable thus we modified and combined the second and the third technique. We used suture passer (in first 3 patients) which is 2 mm or even better endoclose which is 1 mm in diameter as the (third) „virtual“ port for retraction of the appendix. There was no air leakage through the virtual port but if it was needed that the grasper and endoloop are placed simultaneously through 12-mm port there was an air leakage. After extraction of the loop there is no visible scar on the abdominal skin because of small puncture site. Use of linear stapler requires a 12-mm port. The appendix is extracted through 12-mm port (umbilical or suprapubic depending on the position of ports). If 12-mm suprapubic port is used it is below the pants line which is also invisible. The advantage of 2-port intracorporeal over extracorporeal technique is lower percentage of wound infections which could be explained by the avoidance of drawing the inflamed appendix through the umbilical wound (15). The advantage of extracorporeal technique is that it is significantly faster at lower cost (no endoloops, endoclips, or endo-linear cutting stapler).

In our small series we completed the technique in every other patient (54%). All patients in this group were less than 27 years old. Probably younger people (or their parents) seek medical attention earlier and that could partly explain the possibility of completion of this 2-port technique. There was no difference of length of hospitalization and operation time between 2- and 3-port technique. These results cannot be compared statistically because of small number of patients but it is clear that the third port is not responsible for longer hospitalization and duration of operation is not different because manipulation is easier with 3 ports thus even technically more demanding operations are made in the same time. It must be stressed that short operating time for 2-port technique is due to technically and anatomically „easier“ operations. Our opinion is that this modified intracorporeal 2-port technique is a safe and feasible procedure, cosmetically very satisfactory to the patient. This procedure is not one of the cutting edge procedures but in hospitals with classic laparoscopic equipment some patients with anatomically 'easier“ variants of appendicitis and/or earlier presentation could benefit from the procedure.

Conflict of Interest: None

REFERENCES

- 1 Semm K:** Endoscopic appendectomy. *Endoscopy* 1983; 15:59.
- 2 Ure BM, Spangenburg D, Hebebrand E, et al:** Laparoscopic surgery in children and adolescents with suspected appendicitis: Results of medical technology assessment. *Eur J Pediatr Surg* 1992; 2:336-340.
- 3 Towfigh S, Chen F, Mason R, et al:** Laparoscopic appendectomy significantly reduces length of stay for perforated appendicitis. *Surg Endosc* 2006; 20:495.
- 4 Kollmar O, Z'graggen K, Schilling MK, et al:** The suprapubic approach for laparoscopic appendectomy. *Surg Endosc* 2002; 17:166.
- 5 Schier F:** Laparoscopic appendectomy with 1.7-mm instruments. *Pediatr Surg Int* 1998; 14:142.
- 6 Rao MM, Rao RK:** Two-port and single port laparoscopic appendectomy. *J Indian Med Assoc* 2004; 102:360,362,364.
- 7 Konstadoulakis MM, Gomatos IP, Antonakis PT, et al:** Two-trocar laparoscopic-assisted appendectomy versus conventional laparoscopic appendectomy in patients with acute appendicitis. *J Laparoend Adv Surg Techn* 2006; 16:27.
- 8 Valioulis I, Hameury F, Dahmani L, Levard G:** Laparoscope-assisted appendectomy in children: The two-trocar technique. *Eur J Pediatr Surg* 2001; 11:391.
- 9 Crawford DL:** Inexpensive retraction technique for advanced laparoscopic procedures. *Surg Laparosc Endosc* 2000; 10:258.
- 10 Russo M Jr:** The 'LAP-LOOP'. A substitute for the fourth trocar in laparoscopic cholecystectomy. *Surg. Endosc* 1999; 13:1247.
- 11 Panait L, Bell RL, Duffy AJ, Roberts KE:** Two-port laparoscopic appendectomy: minimizing the minimally invasive approach. *J Surg Res* 2009; 153:167.

12 Sato N, Kojika M, Yaegashi Y, et al: Mini-laparoscopic appendectomy using a needle loop retractor offers optimal cosmetic results. *Surg Endosc* 2004; 18:1578.

13 Yeung GH, Leung SL, Tse S: Intravenous cannula: an instrument and a port in laparoscopic surgery. *ANZ J Surg* 2001; 71:238.

14 Ateş O, Hakgüder G, Olguner M, Akgür FM: Single-port laparoscopic appendectomy conducted intracorporeally with the aid of a transabdominal sling suture. *J Pediatr Surg* 2007; 42:1071.

15 Suttie SA, Seth S, Driver CP, Mahomed AA: Outcome after intra- and extra-corporeal laparoscopic appendectomy techniques. *Surg Endosc* 2004; 18:1123.

Figure legends

FIGURE 1 Appendix should be identified with only one instrument through 12-mm port. It could be covered with omentum or in any unfavorable position.

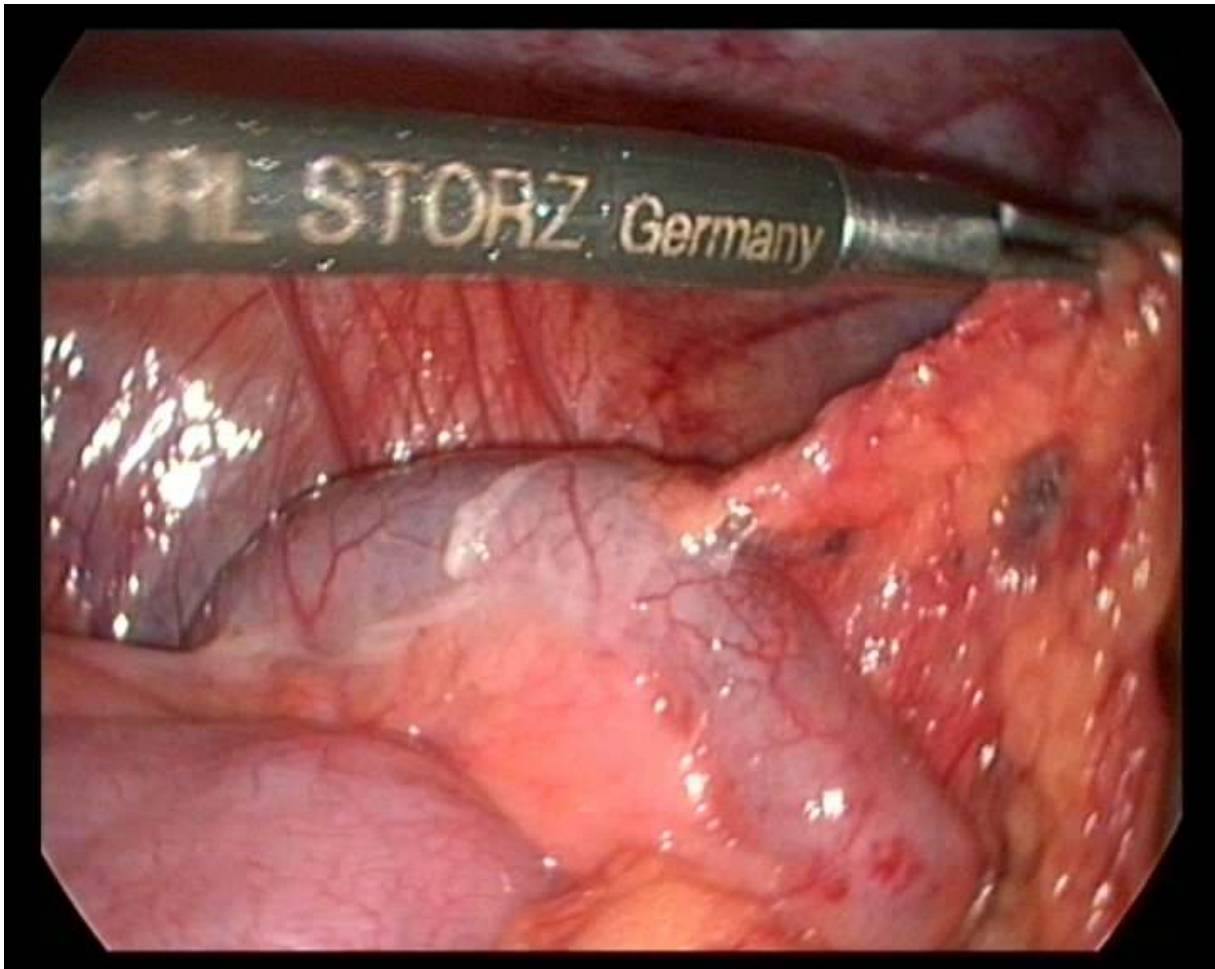


FIGURE 2 After identification it is grasped for mesoappendix and elevated to the anterior abdominal wall for estimation of adequate exposure of the mesoappendix and appendicocolic junction and relative mobility of the cecum.

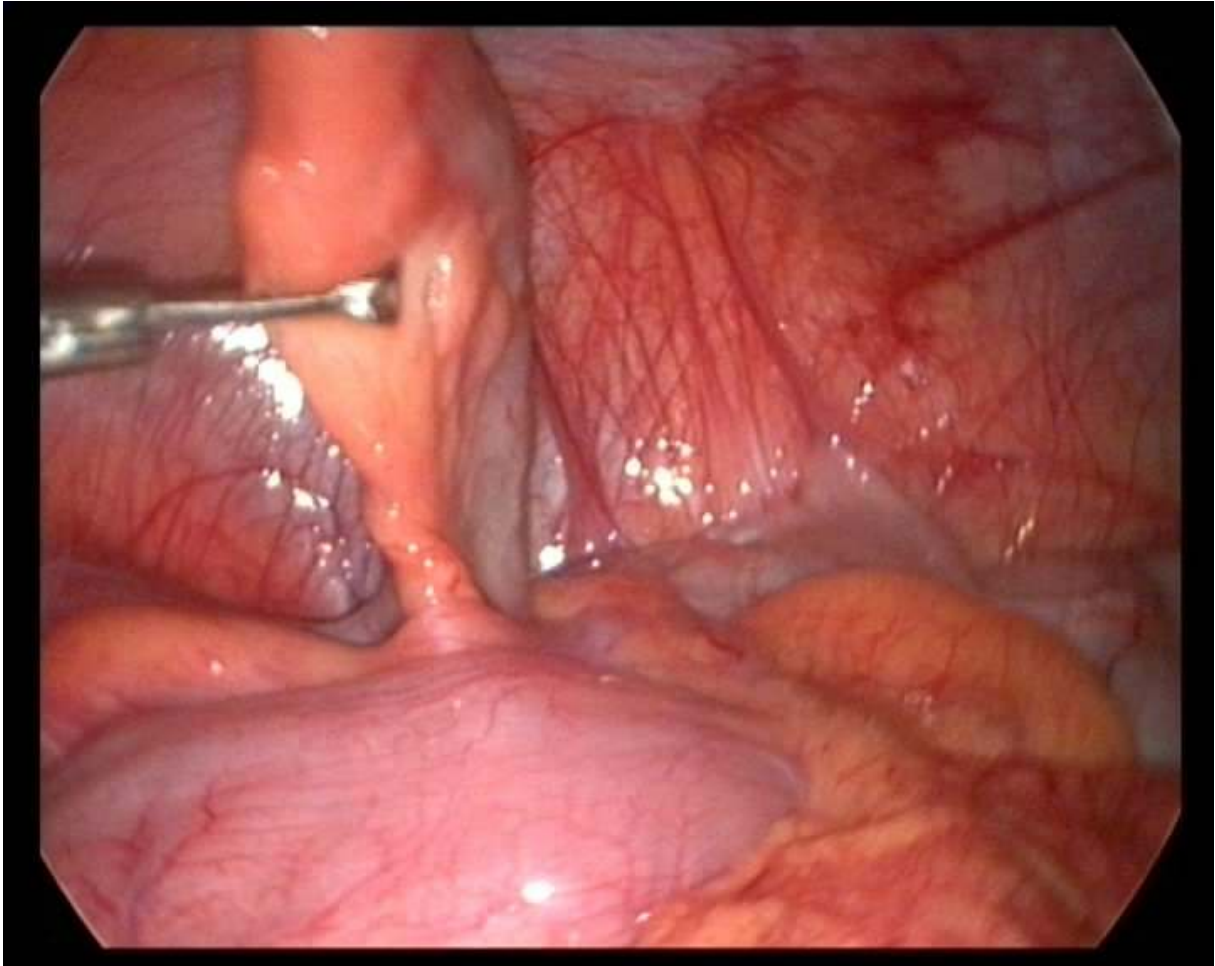


FIGURE 3 Appendix is directed toward 12-mm port for easier placing of Endoloop ligature (Ethicon, Johnson&Johnson, USA) which is tied around the base, 1-2 cm distally from the origin of the appendix, or below the macroscopically changed appendix to minimize the possibility of appendiceal rupture and spillage of its contents. If there is technical difficulty in seizing the appendix then the bowel clamp or forceps is introduced through the same port for assistance.

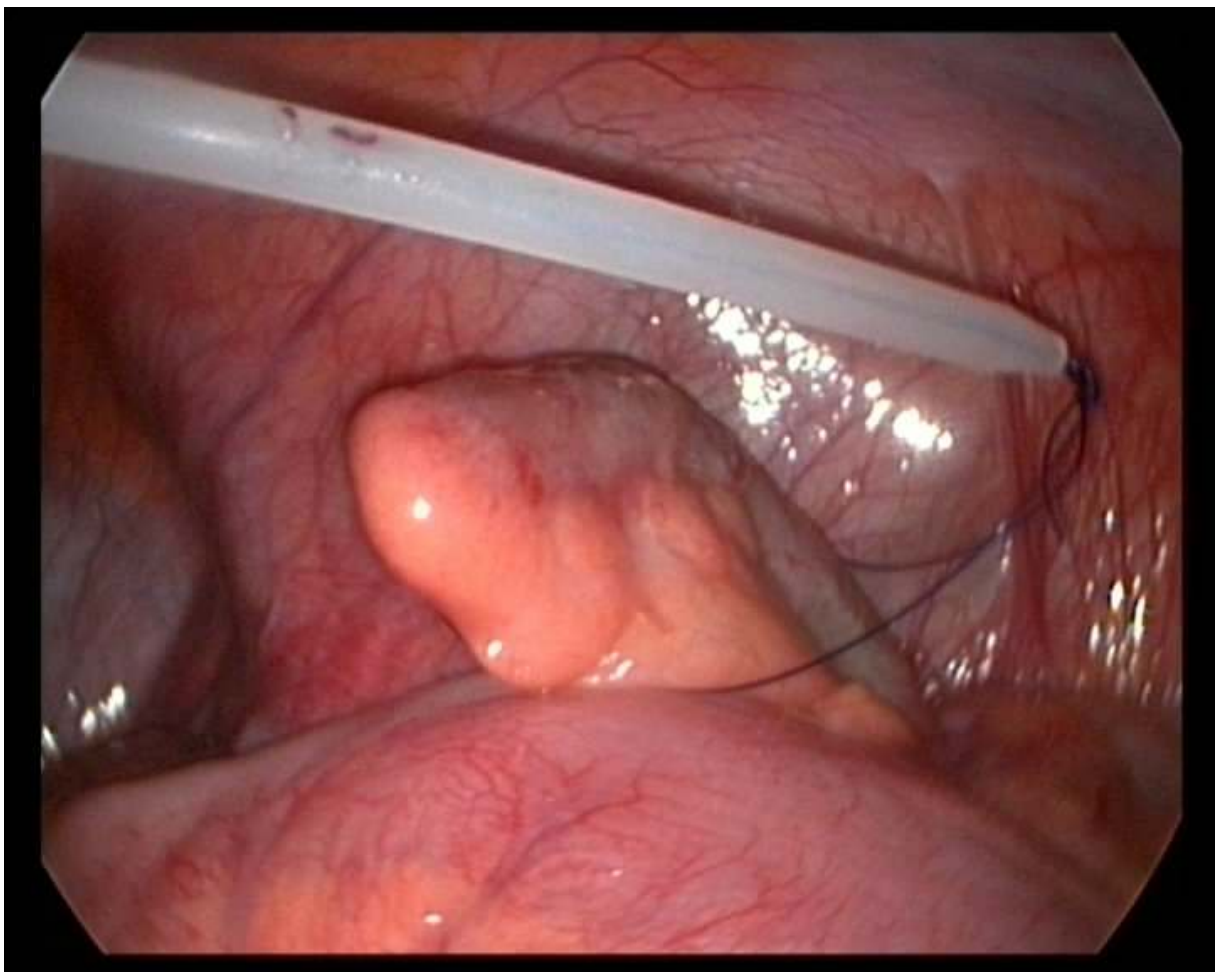


FIGURE 4 Suture Passer (Gore Medical, USA) or Endo Close (Autosuture, Covidien, USA) is introduced above the appendiceal origin or 1-2 cm cranially to its base. The free end of the pretied loop suture is placed in the suture grasper.

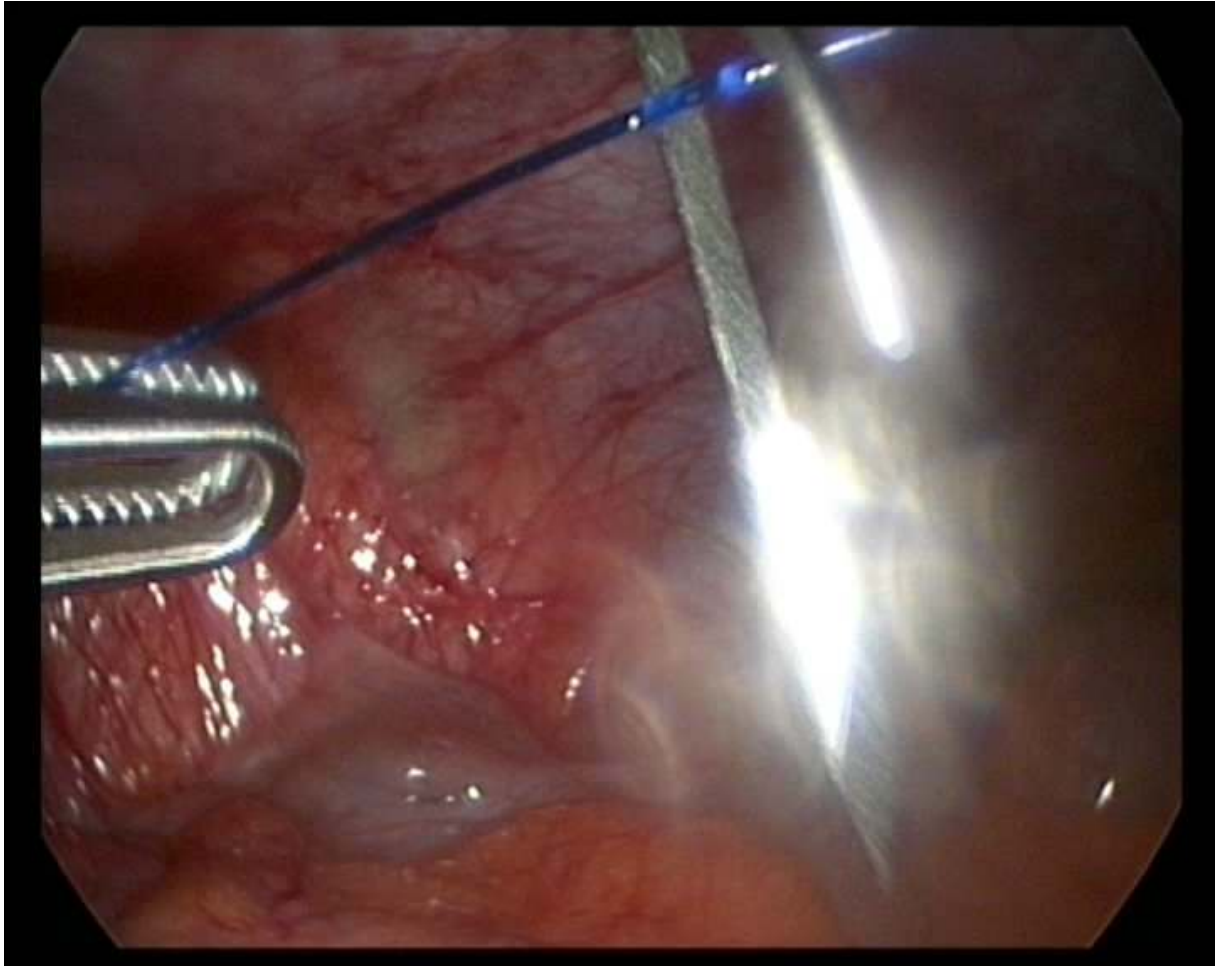


FIGURE 5 Appendix is elevated by pulling the endoloop through the skin until the mesoappendix and the base of the appendix are exposed adequately.

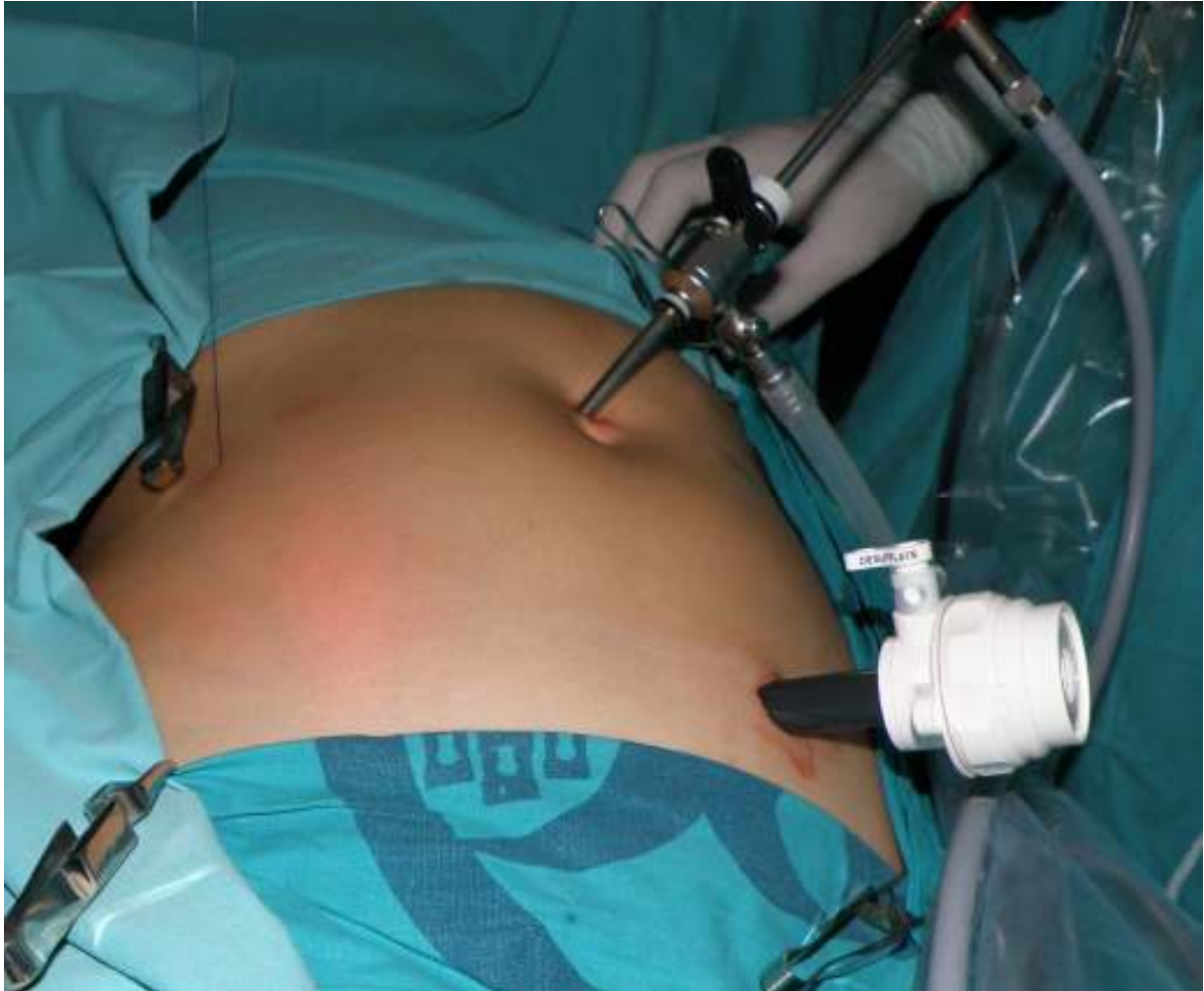

FIGURE 6 After complete skeletization of the appendix with harmonic scalpel the 45 mm linear stapler-cutter is introduced and fired at the junction of appendix with the cecum.

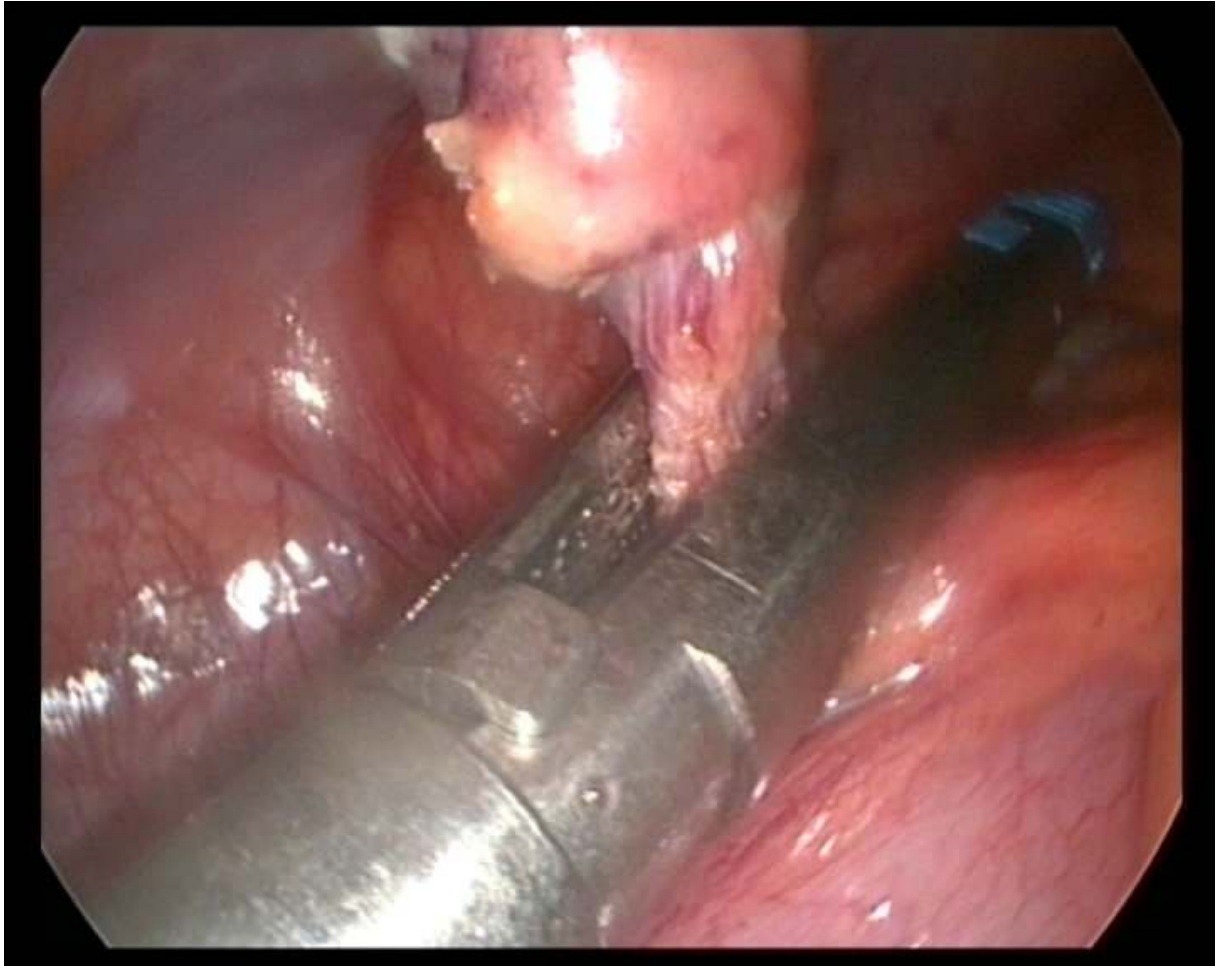


FIGURE 7 After division the appendix is hanging on the endoloop. The appendix is put in the Endocatch Gold (Covidien, Autosuture, USA) and exteriorized through the suprapubic 12-mm port.

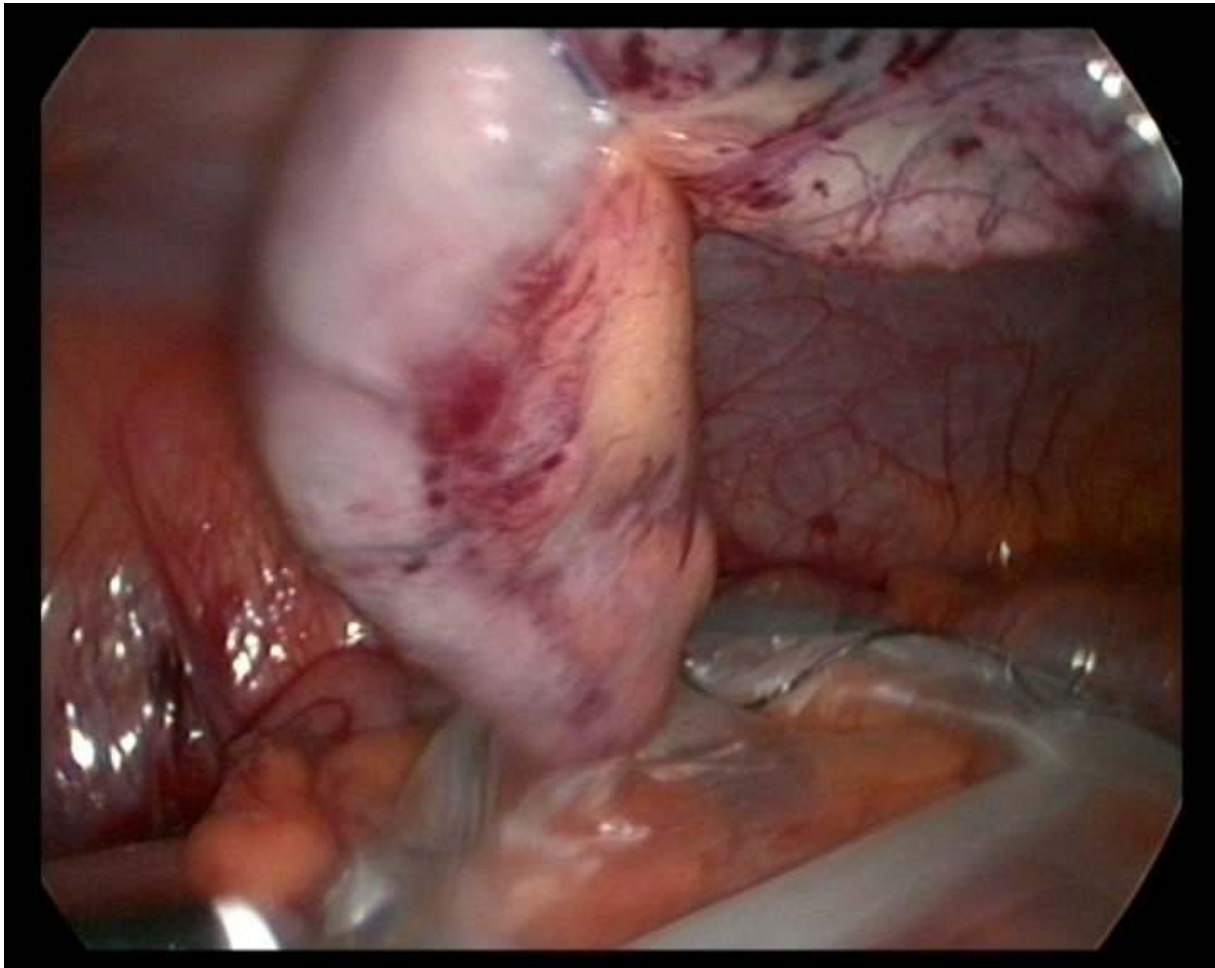


FIGURE 8 A) Incision on second postoperative day after 2-port appendectomy. B) When the patient puts her pants in normal position, lower incision (future scar) is not visible.



