

Inflammatory myofibroblastic tumors of the duodenum

Petrović, Igor; Augustin, Goran; Hlupić, Ljiljana; Nedić, Ana; Romić, Ivan; Škegro, Mate

Source / Izvornik: **Asian Journal of Surgery, 2013, 39, 247 - 252**

Journal article, Published version

Rad u časopisu, Objavljena verzija rada (izdavačev PDF)

<https://doi.org/10.1016/j.asjsur.2013.09.015>

Permanent link / Trajna poveznica: <https://urn.nsk.hr/urn:nbn:hr:105:620345>

Rights / Prava: [In copyright](#) / [Zaštićeno autorskim pravom.](#)

Download date / Datum preuzimanja: **2024-07-28**



Repository / Repozitorij:

[Dr Med - University of Zagreb School of Medicine
Digital Repository](#)



Available online at www.sciencedirect.com

ScienceDirect

journal homepage: www.e-asianjournalsurgery.com

CASE REPORT

Inflammatory myofibroblastic tumors of the duodenum

Igor Petrovic^a, Goran Augustin^a, Ljiljana Hlupic^b, Ana Nedic^{c,*},
Ivan Romc^a, Mate Skegro^a

^a Division of Abdominal Surgery, Clinical University Hospital Centre "Zagreb", Zagreb, Croatia

^b Department of Pathology, Clinical University Hospital Centre "Zagreb", Zagreb, Croatia

^c Department of Internal Medicine, General Hospital "Virovitica", Virovitica, Croatia

Received 5 January 2013; received in revised form 26 July 2013; accepted 23 September 2013

KEYWORDS

duodenal neoplasms;
inflammatory
pseudotumor;
neoplasm;
soft tissue

Summary Inflammatory myofibroblastic tumors (IMTs) are rare soft-tissue tumors that can occur at virtually any anatomical site. We report the case of a 58-year-old male with an IMT of the fourth part of the duodenum who presented with signs and symptoms of high intestinal obstruction and bilious vomiting. The patient underwent a surgical resection of the fourth part of the duodenum with end-to-end duodenojejunal anastomosis. The follow-up period of 6 months was uneventful with no evidence of recurrence. According to our knowledge, only six cases of duodenal IMTs have been reported in the literature thus far, and this is the first report of a duodenal IMT sited at the fourth part of the duodenum. The duodenum is among the rarest sites of IMTs. Signs and symptoms resulting from diagnostic imaging investigations are nonspecific and inadequate to obtain diagnosis accurately. In most cases, surgical treatment is considered a cure for IMTs. There is no evidence of deaths caused by duodenal IMT. IMT of the duodenum is a possible diagnosis in differential diagnosis of tumor-like lesions of the duodenum.

Copyright © 2013, Asian Surgical Association. Published by Elsevier Taiwan LLC. All rights reserved.

1. Introduction

Inflammatory myofibroblastic tumors (IMTs) are rare tumors histologically composed of spindle myofibroblasts and an

inflammatory infiltrate dominated by plasma cells, lymphocytes, and eosinophils.¹ According to the World Health Organization, IMTs belong to a group of soft-tissue tumors, a subset of fibroblastic/myofibroblastic tumors.² These principally occur in soft tissues and visceral organs at possibly any anatomical location. Nevertheless, duodenal IMTs remain an extremely rare condition. We report a case of IMT of the fourth part of the duodenum. Only six cases of

* Corresponding author. Department of Internal Medicine, General Hospital "Virovitica", Gajeva 21, Virovitica 33000, Croatia.
E-mail address: ana.nedic25@gmail.com (A. Nedic).

duodenal IMTs have been reported in literature thus far. We present a review of these cases.^{3–8}

2. Case report

A 58-year-old male who presented with a 1-week history of an intermittent epigastric pain, bilious vomiting, and unintentional weight loss of 10 kg in 4 weeks was admitted to the Department of Surgery of Clinical University Hospital Center. His medical history was significant for gastroesophageal reflux disease (GERD), *Helicobacter pylori* gastritis, Gilbert's syndrome, and acute pancreatitis of unknown exact cause 2 months ago, which was successfully treated conservatively. Multiple abdominal ultrasonographies (USs) and multislice computed tomography (MSCT) scans excluded cholelithiasis and there was no evidence of alcohol abuse in the patient's history (gamma glutamyl transferase: 17 U/L). Other causes of acute pancreatitis could neither be proven with certainty nor excluded.

A physical examination demonstrated abdominal bloating and visible distension with pain on palpation of the epigastric area of the abdomen. There was no jaundice, fever, or anemia. Laboratory tests revealed slightly elevated levels of aspartate transaminase (46 U/L), alanine transaminase (72 U/L), total bilirubin (58 $\mu\text{mol/L}$), and direct bilirubin (10 $\mu\text{mol/L}$). Other laboratory examinations analyzing the levels of C-reactive protein, erythrocyte sedimentation rate, complete blood count, coagulation factors, urea, creatinine, lipidogram, serum amylase, electrolytes including calcium, phosphorus, and magnesium were all within normal limits. Tumor markers such as cancer antigen 19-9, alpha-fetoprotein, and cancer antigen 125 were all negative.

Abdominal X-ray, abdominal US, and esophagogastroduodenoscopy showed no significant findings. Contrast imaging of the small intestine displayed a severe stricture of the ascending duodenal portion (D4) measuring 0.8 cm in diameter with normal duodenal mucosal folds and normal morphology of the horizontal and descending portions of the duodenum (Fig. 1).

The MSCT scan of the abdomen revealed a filling defect in the fourth part of the duodenum measuring $4.3 \times 3.6 \text{ cm}^2$ and dilatation of the second and third part of the duodenum. Triangle-shaped infiltration area of the adipose tissue measuring $2.1 \times 1.9 \text{ cm}^2$ was identified cranial to the fourth part of the duodenum (Fig. 2). No regional lymphadenopathy or focal lesions of parenchymatous organs of the abdomen suggestive of metastatic lesions were identified.

Because imaging findings could not exclude malignancy and the mass appeared to be resectable, a surgical exploration was performed through an upper midline laparotomy. A firm, elastic tumor measuring 4 cm was found in the fourth part of the duodenum, adjacent to the paraduodenal adipose tissue and peritoneum surrounding the duodenojejunal flexure. The head of the pancreas and the hepatoduodenal ligament were intact. After the right colon and the mesenteric root mobilization, superior mesenteric artery 5 cm in length was exposed, and resection of the duodenojejunal flexure measuring 15 cm in length with 2-cm surgical resection margin and clearance of loco-regional

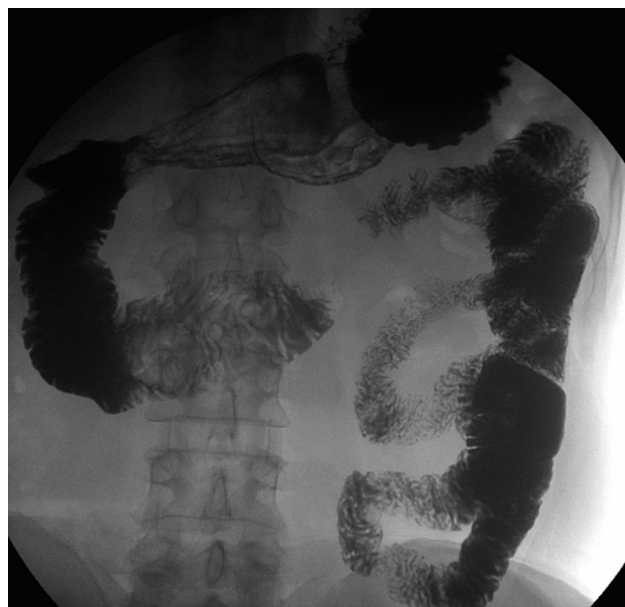

Figure 1 Contrast imaging of the small intestine displays the narrowing of the ascending duodenum.

lymph nodes were performed (Fig. 3). End-to-end duodenojejunal anastomosis with single-layer continuous suture was made for reconstruction. Macroscopic pathology demonstrated a segment of the duodenum 15.5 cm in length and 3.2 cm in diameter with exophytic polypoid tumor measuring $2.1 \times 1.6 \text{ cm}^2$ arising from the duodenal wall (Fig. 4). Histologically, the tumor was composed of spindle-shaped interspersed myofibroblasts separated with fibrous stroma infiltrated by predominantly mononuclear inflammatory cells (Figs. 5 and 6). The tumor cells were immunohistochemically positive for actin, vimentin, AE1/AE3, and negative for nonspecific esterase, CD34, CD117, S-100, and DOG1. The resection margins were clear of malignancy. In the surrounding adipose tissue, seven lymph nodes were found, which had a diameter from 0.4 to 1.2 cm, uninvolved with tumor tissue. A postoperative

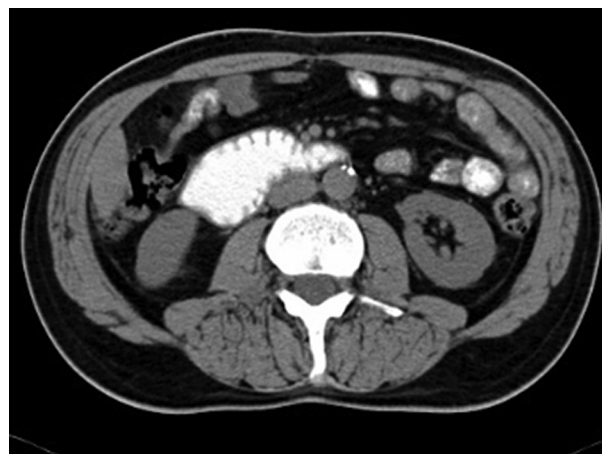

Figure 2 Multislice computed tomography demonstrates a filling defect in the fourth part of the duodenum.

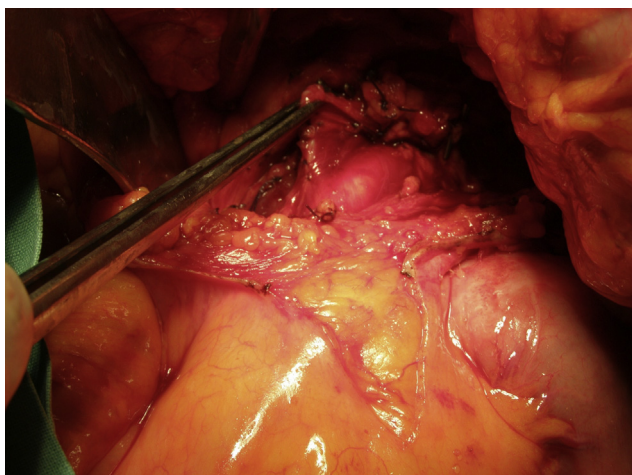


Figure 3 Surgical exploration of the tumor and the demonstration of the superior mesenteric artery.

course was uneventful with complete resolution of patient's symptoms. Six months after the surgery the patient remained asymptomatic with no evidence of recurrence detected by the MSCT scans.

3. Discussion

Different terms for IMT have been used—inflammatory pseudotumor,⁹ fibrous xanthoma, plasma cell granuloma,¹⁰ pseudosarcoma, lymphoid hamartoma, myxoid hamartoma,¹¹ inflammatory myofibrohistiocytic proliferation, pseudosarcomatous myofibroblastic proliferation.¹² The term "inflammatory pseudotumor" has for many years been used for any clinically, macroscopic, or microscopic tumor-like lesion caused by inflammatory or reactive process.¹³ Later, the term has been applied only to neoplastic lesions microscopically characterized by the proliferation of spindle cells of mesenchymal origin with morphological characteristics of myofibroblasts and large inflammatory

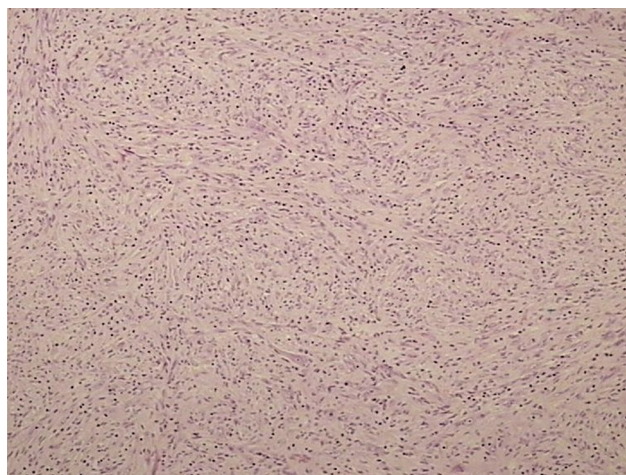


Figure 5 Photomicrograph demonstrating an admixture of spindle-shaped and ovoid cells with a prominent inflammatory infiltrate (hematoxylin–eosin; low-power view; magnification 10 \times).

infiltration of different types of cells, usually with predominance of mature lymphocytes and plasma cells, regardless of etiology. However, during the last two decades, due to a greater understanding of the importance of myofibroblastic component in relation to inflammatory component^{1,14} and additional electron microscopic and immunohistochemical findings, this term has entirely replaced other terms.¹⁵

IMTs occur mainly in children and young adults, with more reports published on IMTs in adults recently.^{16,17} However, their etiology is unknown. Two basic hypotheses, reactive and neoplastic, are complemented with presumably infectious and autoimmune hypotheses. However, the exact infectious agents are not known. Some relate IMTs to Epstein–Barr virus, human herpesvirus-8, the bacterium *Eikenella corrodens*, and schistosomiasis.^{18–21} Others claim that previous surgical manipulation and

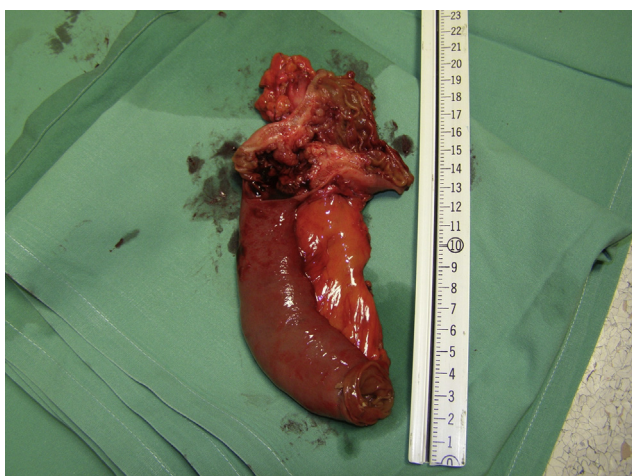


Figure 4 Segment of the duodenum 15.5 cm in length and 3.2 cm in diameter with exophytic polypoid tumor measuring 2.1 \times 1.6 cm arising from the duodenal wall.

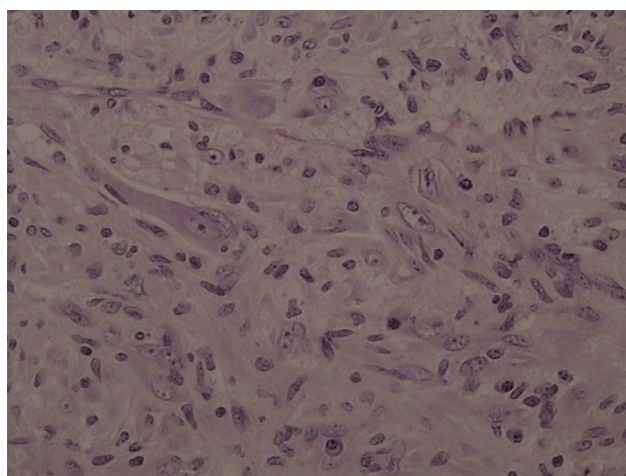


Figure 6 Photomicrograph showing a conspicuous admixture of lymphocytes and plasma cells (high-power view; magnification 40 \times).

chemotherapy or radiotherapy are potential causes.^{22–24} Some studies suggest the possible autoimmune origin of IMTs.²⁵ According to these hypotheses, a medical history of acute pancreatitis, GERD, and *H. pylori* gastritis could be contributing factors in our case.

Based on the anatomical site, IMTs can be pulmonary and extrapulmonary.¹⁷ Extrapulmonary IMTs are most frequent in the abdomen including the mesentery and omentum.¹⁶ Other sites of the gastrointestinal tract are all visceral organs such as the appendix, Meckel's diverticulum, and Vater's papilla.^{3,22,24,26,27} Duodenal IMTs are among the rarest. To our knowledge, only six cases of duodenal IMTs have been reported, five of which had anatomical sites at the first and second parts of the duodenum, and one, particularly interesting, multiple IMT arising from the first part of the duodenum and extending up to the first part of the jejunum.^{3–8} According to the available literature, our patient is the first with IMT localization in the fourth part of the duodenum (Table 1^{3–8}). Specific risk factors are not defined and potential risk factors of duodenal IMT are provided in Table 1. Considering these cases, there seems

to be no gender or age predilection (Table 1). Signs and symptoms of abdominal IMTs often mimic malignant tumors.^{22,28} Duodenal IMTs mostly present with upper gastrointestinal-tract obstructive symptoms, nausea, vomiting, pain in the epigastric area, anorexia, weight loss, malaise and fatigue, while in one of the cases night sweats were referred to as one of the significant symptoms. None of the cases presented with jaundice.^{3–8} Bilious vomiting, present in our patient, was not described previously (Table 1).

Diagnostic imaging techniques demonstrate tumor mass with its extent without specific features necessary for obtaining accurate diagnosis. Stricture of the duodenum, impossible passage, and irregular masses arising from different parts of the duodenum are most usual findings on radiological examination. It can be difficult to distinguish duodenal IMT from other groups of soft-tissue tumors or even pure (post)inflammatory strictures due to long-standing ulcer or diverticulitis. Stenosis due to duodenal ulcer can be divided into acute/active and chronic ulceration. Acute ulceration results in inflammatory edema and

Table 1 Review of duodenal IMT case reports and potential risk factors.

Author	Segment of duodenum	Age (y)/sex	Symptoms and signs	Treatment	Recurrence (treatment)	Potential risk factors
Fong et al ³	Second/third	57/F	Gastric outlet obstruction	Whipple operation	None	No report
Stringer et al ⁴	Second	5/F	Nonbilious vomiting; significant weight loss	Whipple operation with standard reconstruction	None	None
Mattei and Barnaby ⁵	First/second	13/M	Asymptomatic (incidentally diagnosed IMT)	Intravenous NSAID application (ketorolac); laparotomy (tumor mass regression)—Roux-en-Y gastrojejunostomy	None	Paratesticular rhabdomyosarcoma
Wynn et al ⁶	First	16/M	Abdominal pain; night sweats; malaise	En-bloc excision with primary closure of the duodenum	Yes (perioral corticosteroids; azathioprine)	No report
Mirshemirani et al ⁷	First	13/M	Abdominal pain; weight loss; epigastric mass	Surgical resection of the tumor; duodeno—duodenostomy	None	No report
Xiang et al ⁸	Multiple IMT (from the first part of the duodenum to starting part of the jejunum)	20/M	Intermittent right epigastric pain; nausea; vomiting	Whipple operation	None	Calculous colecystitis
Current study	Fourth	58/M	Bilious vomiting; epigastric pain; significant weight loss	Resection of the duodenojejunal flexure with termino-terminal anastomosis	None	Acute pancreatitis; GERD; <i>H. pylori</i> gastritis

GERD = gastroesophageal reflux disease; IMT = inflammatory myofibroblastic tumor; NSAID = nonsteroidal anti-inflammatory drug.

pylorospasm. Signs and symptoms of stenosis may regress if the ulcer heals under medical treatment, which is not noticed in IMT cases. Long-standing ulceration can present with radiological demonstration of scarring and deformities of the duodenum. In most cases, there are no signs of tumorous mass. Past medical history of peptic ulcer-type pain for 10 or more years strongly suggests the precise diagnosis^{29,30} contrary to duodenal diverticula, which are the uncommon site of inflammation due to their large size and mostly sterile content of the duodenum. The incidence of duodenal diverticula is approximately 22% with the incidence of complicated duodenal diverticulum estimated from 0.03% to 5%. Inflammation of the diverticulum can be distinguished before surgery by meticulous CT scan analysis. The CT findings vary between saccular and tubular configuration, diverticular content (homogenous liquid, liquid debris, and hydroaeric levels), wall (thickened, enhanced, and thin), retroperitoneal infiltration, free air, and signs of common bile duct dilatation.^{31,32}

Definitive diagnosis of IMTs is confirmed by histopathological analysis and immunohistochemical tests of surgically removed specimen. Some histopathological IMT patterns such as compact fascicular spindle cells with myxoid or collagenized regions intermingled with inflammatory cells may resemble fibromatoses. Fibromatosis colli, juvenile hyaline fibromatosis, superficial fibromatosis, desmoid-type fibromatosis, and lipofibromatosis are well-defined soft-tissue tumors histopathologically differentiated from IMT. These benign neoplasms can extend into adjacent tissues, and sometimes have a tendency toward local recurrence, but do not metastasize. Except superficial fibromatosis and desmoid-type fibromatosis, other entities of this group occur mostly in infants or early childhood with no sex predilection. Superficial and desmoid-type fibromatosis occur mostly in adults with slight predominance in men of first entity and in women of second entity. To the best of our knowledge and according to available literature, no cases of fibromatoses of duodenum were reported so far.²

The basic principle for IMTs treatment is complete surgical resection.¹⁶ In nonresectable tumors, a palliative treatment regimen with radiotherapy and nonsteroidal anti-inflammatory drugs (NSAIDs) can be applied. However, guidelines for this treatment approach do not exist. Some studies recommend the use of NSAIDs, corticosteroids, and immunosuppressive drugs after the surgery. One case of the duodenal IMT recurrence was successfully treated by the application of NSAIDs and immunosuppressive drugs.^{5,6,33} IMTs are among the increasing number of diseases in which aberrant anaplastic lymphoma kinase gene (ALK) has been implicated in their pathogenesis.³⁴ Considering ALK expression in approximately 50% of IMTs, abrogation of ALK signaling through direct kinase inhibition has become an attractive therapeutic intervention point. So far, IMTs are among particularly promising tumors for targeted therapy using crizotinib, a small-molecule inhibitor.³⁵

Surgical excision of the tumor is considered to cure IMTs; however, due to its potential recurrence capability, a long-term follow-up is recommended. Relapse predictors are not known. Combination of atypia, ganglion-like cells, ALK positivity, and aneuploidy suggests more aggressive potential. The main prognostic indicator is the adequacy of the

primary excision.² According to available literature, there are no general IMT survival statistics. These previous studies are mainly related to low mortality rate due to IMT, rare distant metastases, and rare recurrence of the disease. In Coffin's review of 84 cases of extrapulmonary IMTs after clinical follow-up in 53 cases, 44 had no evidence of disease, four had IMT, and five died due to complications related to the location of the lesion or the treatment of the disease.¹⁷ Moreover, Coffin et al define IMT as a non-metastasizing proliferation of myofibroblasts. Only a few cases described in the literature specify IMT as a cause of death, mostly due to the localization of the tumor (e.g., heart).³⁶

A review of the treatment methods for duodenal IMTs is provided in Table 1. There were no complications reported during postoperative recovery. One patient developed a recurrence 6 months after the surgery, which was successfully treated by immunosuppressive drugs (Table 1). During the follow-up of 2 months to 2 years, all patients including ours, were alive with no evidence of recurrence. According to these reports, IMT of the duodenum can be considered as a tumor with good prognosis, low mortality rate, and low recurrence potential.

In conclusion, the duodenum is among the rarest sites of IMTs. Signs and symptoms as results of diagnostic imaging investigations are nonspecific and inadequate to accurately obtain diagnosis. The diagnosis can be confirmed only by a histopathological analysis and immunohistochemical tests of the surgically removed specimens. In most cases of duodenal IMTs, surgical treatment is considered to cure the disease. There is no evidence of deaths caused by duodenal IMTs. All reported patients with duodenal IMTs had an uneventful recovery. Duodenal IMT should be considered in differential diagnosis of tumor-like lesions of the duodenum.

References

1. Pettinato G, Manivel JC, De Rosa N, Dehner LP. Inflammatory myofibroblastic tumor (plasma cell granuloma). Clinicopathologic study of 20 cases with immunohistochemical and ultrastructural observations. *Am J Clin Pathol.* 1990;94: 538–546.
2. Fletcher CDM, Unni K, Mertens F, eds. *World Health Organization Classification of Tumours. Pathology and Genetics of Tumours of Soft Tissue and Bone* vol. 2. Lyon: IARC Press; 2002: 91–93.
3. Fong SS, Zhao C, Yap WM, Loke SC, Lim KH. Inflammatory myofibroblastic tumour of the duodenum. *Singapore Med J.* 2012;53:e28–e31.
4. Stringer MD, Ramani P, Yeung CK, Capps SN, Kiely EM, Spitz L. Abdominal inflammatory myofibroblastic tumours in children. *Br J Surg.* 1992;79:1357–1360.
5. Mattei P, Barnaby K. Rapid regression of duodenal inflammatory myofibroblastic tumor after intravenous ketorolac: case report and review of the literature. *J Pediatr Surg.* 2008;43: 1196–1199.
6. Wynn GR, Giles A, Steger AS, Wilkinson ML. Case report: inflammatory myofibroblastic tumor of the duodenum. *J Gastrointest Cancer.* 2008;39:79–81.
7. Mirshemirani A, Tabari AK, Sadeghian N, Shariat-Torbaghan S, Pourafkari M, Mohajerzadeh L. Abdominal inflammatory myofibroblastic tumor: report on four cases and review of literature. *Iran J Pediatr.* 2011;21:543–548.

8. Xiang J, Liu X, Wu S, Lv Y, Wang H. Multiple inflammatory myofibroblastic tumor of the duodenum: case report and literature review. *J Gastrointest Surg.* 2012;16:1442–1445.
9. Wu JP, Yunis EJ, Fetterman G, Jaeschke WF, Gilbert EF. Inflammatory pseudo-tumours of the abdomen: plasma cell granulomas. *J Clin Pathol.* 1973;26:943–948.
10. Spencer H. The pulmonary plasma cell/histiocytoma complex. *Histopathology.* 1984;8:903–916.
11. Gonzalez-Crussi F, deMello DE, Sotelo-Avila C. Omental-mesenteric myxoid hamartomas. Infantile lesions simulating malignant tumors. *Am J Surg Pathol.* 1983;7:567–784.
12. Tang TT, Segura AD, Oechler HW, et al. Inflammatory myofibrohistiocytic proliferation simulating sarcoma in children. *Cancer.* 1990;65:1626–1634.
13. Umiker WO, Iverson L. Postinflammatory tumors of the lung; report of four cases simulating xanthoma, fibroma, or plasma cell tumor. *J Thorac Surg.* 1954;28:55–63.
14. Gleason BC, Hornick JL. Inflammatory myofibroblastic tumors: where are we now? *J Clin Pathol.* 2008;61:428–437.
15. Czauderna P, Schaarschmidt K, Komasa L, et al. Abdominal inflammatory masses mimicking neoplasia in children—experience of two centers. *Pediatr Surg Int.* 2005;21:346–350.
16. Coffin CM, Humphrey PA, Dehner LP. Extrapulmonary inflammatory myofibroblastic tumor: a clinical and pathological survey. *Semin Diagn Pathol.* 1998;15:85–101.
17. Coffin CM, Watterson J, Priest JR, Dehner LP. Extrapulmonary inflammatory myofibroblastic tumor (inflammatory pseudotumor). A clinicopathologic and immunohistochemical study of 84 cases. *Am J Surg Pathol.* 1995;19:859–872.
18. Neuhauser TS, Derringer GA, Thompson LD, et al. Splenic inflammatory myofibroblastic tumor (inflammatory pseudotumor): a clinicopathologic and immunophenotypic study of 12 cases. *Arch Pathol Lab Med.* 2001;125:379–385.
19. Lee SH, Fang YC, Luo JP, Kuo HI, Chen HC. Inflammatory pseudotumour associated with chronic persistent *Eikenella corrodens* infection: a case report and brief review. *J Clin Pathol.* 2003;56:868–870.
20. Gómez-Román JJ, Ocejo-Vinyals G, Sánchez-Velasco P, Nieto EH, Leyva-Cobián F, Val-Bernal JF. Presence of human herpesvirus-8 DNA sequences and overexpression of human IL-6 and cyclin D1 in inflammatory myofibroblastic tumor (inflammatory pseudotumor). *Lab Invest.* 2000;80:1121–1126.
21. Pannain VL, Passos JV, Rocha Filho A, Villela-Nogueira C, Caroli-Bottino A. Aggressive inflammatory myofibroblastic tumor of the liver with underlying schistosomiasis: a case report. *World J Gastroenterol.* 2010;16:4233–4236.
22. Kim SJ, Kim WS, Cheon JE, et al. Inflammatory myofibroblastic tumors of the abdomen as mimickers of malignancy: imaging features in nine children. *AJR Am J Roentgenol.* 2009;193:1419–1424.
23. Vujančić GM, Milovanović D, Aleksandrović S. Aggressive inflammatory pseudotumor of the abdomen 9 years after therapy for Wilms tumor. A complication, coincidence, or association? *Cancer.* 1992;70:2362–2366.
24. Leon CJ, Castillo J, Mebold J, Cortez L, Felmer R. Inflammatory myofibroblastic tumor of the stomach: an unusual complication after gastrectomy. *Gastrointest Endosc.* 2006;63:347–349.
25. Klöppel G, Sipos B, Zamboni G, Kojima M, Morohoshi T. Auto-immune pancreatitis: histo- and immunopathological features. *J Gastroenterol.* 2007;42:28–31.
26. Lopez-Tomassetti Fernandez EM, Luis HD, Malagon AM, Gonzalez IA, Pallares AC. Recurrence of inflammatory pseudotumor in the distal bile duct: lessons learned from a single case and reported cases. *World J Gastroenterol.* 2006;12:3938–3943.
27. Pungpapong S, Geiger XJ, Raimondo M. Inflammatory myofibroblastic tumor presenting as a pancreatic mass: a case report and review of the literature. *JOP.* 2004;5:360–367.
28. Sambhaji CJ, Chauhan A, Kakkar C. Inflammatory myofibroblastic tumor mimics an abdominal neoplasm. *Gastrointest Cancer Res.* 2009;3:254–255.
29. Ellis H. Stenosis due to duodenal ulceration. *Postgrad Med J.* 1966;42:778–782.
30. Low VH, Heyneman LE, Hough DM. Inflammatory pseudotumour of the post-bulbar duodenum. *Australas Radiol.* 1998;42:370–373.
31. de Perrot T, Poletti PA, Becker CD, Platon A. The complicated duodenal diverticulum: retrospective analysis of 11 cases. *Clin Imaging.* 2012;36:287–294.
32. Ming TY, Feng HK, Cherng YJ, Chuan CD, Pai LT, Chi LY. Clinical challenge: diverticulitis of third and fourth portion of the duodenum with perforation. *Rev Esp Enferm Dig.* 2012;104:156–157.
33. Su W, Ko A, O'Connell T, Applebaum H. Treatment of pseudotumors with nonsteroidal antiinflammatory drugs. *J Pediatr Surg.* 2000;35:1635–1637.
34. Coffin CM, Patel A, Perkins S, Elenitoba-Johnson KS, Perlman E, Griffin CA. ALK1 and p80 expression and chromosomal rearrangements involving 2p23 in inflammatory myofibroblastic tumor. *Mod Pathol.* 2001;14:569–576.
35. Butrynski JE, D'Adamo DR, Hornick JL, et al. Crizotinib in ALK-rearranged inflammatory myofibroblastic tumor. *N Engl J Med.* 2010;363:1727–1733.
36. Li L, Burke A, He J, Chang L, Zielke HR, Fowler DR. Sudden unexpected death due to inflammatory myofibroblastic tumor of the heart: a case report and review of the literature. *Int J Legal Med.* 2011;125:81–85.