

Effect of unilateral ureteral obstruction and anti-angiotensin II treatment on renal tubule cell apoptosis and interstitial fibrosis in rats

Radović, Nikola; Aralica, Gorana; Galešić Ljubanović, Danica; Jeleč, Vjekoslav; Kontek, Mladen

Source / Izvornik: **Collegium Antropologicum, 2014, 38, 583 - 588**

Journal article, Published version

Rad u časopisu, Objavljena verzija rada (izdavačev PDF)

Permanent link / Trajna poveznica: <https://urn.nsk.hr/urn:nbn:hr:105:108834>

Rights / Prava: [In copyright](#) / [Zaštićeno autorskim pravom.](#)

Download date / Datum preuzimanja: **2024-05-31**



Repository / Repozitorij:

[Dr Med - University of Zagreb School of Medicine
Digital Repository](#)



Effect of Unilateral Ureteral Obstruction and Anti-Angiotensin II Treatment on Renal Tubule Cell Apoptosis and Interstitial Fibrosis in Rats

Nikola Radović¹, Gorana Aralica², Danica Galešić Ljubanović², Vjekoslav Jeleč³ and Mladen Kontek⁴

¹ University of Zagreb, University Hospital Dubrava, Department of Urology, Zagreb, Croatia

² University of Zagreb, School of Medicine, University Hospital Dubrava, Department of Pathology, Institute of Pathology, Zagreb, Croatia

³ University of Zagreb, University Hospital Dubrava, Department of Neurosurgery, Zagreb, Croatia

⁴ University of Zagreb, University Hospital Merkur, Department of Nephrology, Zagreb, Croatia

ABSTRACT

Unilateral ureteral obstruction (UUO) results in a number of pathophysiological and morphological changes in the renal parenchyma, including interstitial inflammation and fibrosis, apoptotic changes of tubular and interstitial cells. Recent studies have indicated an association between renin-angiotensin system and apoptotic alterations in the kidney after unilateral obstructive nephropathy. In this study, the effect of ACE inhibitors and AT1 receptor antagonists on tubular cell apoptosis and interstitial fibrosis in obstructive nephropathy after UUO in rats was investigated. The study was conducted on Wistar rats with unilaterally ligated ureter and sham operated animals (control group). The rats with UUO were treated with ACE inhibitor (cilazapril) or AT1 receptor antagonists (losartan) and control group was treated with H₂O. Sham-operated animals were treated in the same way. Tubular and interstitial cell apoptosis was detected morphologically by hematoxylin and eosin (HE) staining and terminal deoxynucleotidyl transferase-mediated nick end-labeling (TUNEL). The area of interstitial fibrosis was determined using computer-assisted image processing after Gomory silver impregnation of paraffin sections. All experimental animal groups with unilateral ureter ligation showed a significantly increased number of apoptotic tubular and interstitial cells in the obstructed kidney compared with the contralateral, unobstructed kidney. Histomorphometric analysis of renal interstitial fibrotic changes in the groups of rats treated with losartan or water showed a statistically significant difference ($p < 0.05$) between the operated and sham-operated animals. In conclusion, following UUO there is a significantly increased number of apoptotic tubular cells and interstitial fibrosis in the ipsilateral kidney compared with the contralateral kidney. ACE inhibitors and AT1 receptor antagonists could not decrease the extent of renal cells apoptosis and interstitial fibrosis after UUO.

Key words: obstructive nephropathy, apoptosis, angiotensin II, interstitial fibrosis, ACE inhibitors, AT1 receptor antagonist

Introduction

Unilateral ureteral obstruction (UUO) leads to progressive and eventually permanent changes, infiltration of the kidney by macrophages, induction of α -smooth muscle actin, cytokine production, interstitial inflammation and fibrosis, apoptosis and renal parenchymal damage all of which entities are generally termed chronic obstructive nephropathy¹. Tubulointerstitial fibrosis is considered to be the common endpoint result of many forms of chronic renal diseases irrespectively of the basic pa-

thogenesis^{2,3}. Except for renal replacement, chronic renal fibrosis is presently incurable. The pathologic mechanism underlying chronic obstructive nephropathy is not completely elucidated, although the fibrogenic process clearly plays a critical role in ultimately leading to permanent loss of the normal structural and functional integrity of the kidney⁴. About 80% of total kidney volume is composed of tubular epithelial cells and cells within the interstitial space. There are also a small number of

resident mononuclear cells and fibroblasts. There are many readily quantifiable cellular and molecular events during the initiation and progression of renal fibrosis that make UUO an increasingly good experimental model for study⁵. A number of kidney diseases and their progression to end-stage renal failure are driven by the effects of angiotensin II (Ang II). Compelling evidence from Shin and co-workers demonstrates that the suppression of intrarenal RAS prevents the formation of renal cortical TGF- β 1 and of related fibrogenic factors in early UUO^{6,7}. Angiotensin II upregulates the expression of TGF- β 1 in UUO, whereas ACE inhibitors or angiotensin receptor blockers diminish TGF- β 1 expression. Angiotensin II exerts its biological effect through both AT1 and AT2 receptors, although in adult mammals the AT1 receptors predominate and account for most of the known effects of the peptide⁸. Ang II is produced both systemically and locally in various tissues, including the heart and blood vessel walls. Ang II binds to two high-affinity receptors, designated AT1 and AT2. Signaling through the AT1 receptor results in vasoconstriction, stimulation of growth and activation of fibroblasts and myocytes. Signaling through AT2 receptor results in vasodilatation and antiproliferative responses, as well as an increase in apoptosis. Therefore, it appears that most of the damaging effects of Ang II are mediated by the AT1 receptor. Increasing levels of Ang II may, in turn, upregulate the expression of other factors, such as TGF- β 1, TNF- α , osteopontin, VCAM-1 and NF- κ B. Ang II increases the expression of several proliferative factors, including PDGF and basic growth factor⁴. The objective of this study is to quantify the degree of interstitial fibrosis in rat kidney after experimental UUO and administration of an angiotensin converting enzyme (ACE) inhibitor – cilazapril and AT1 receptor blocker – losartan. We hypothesized that limiting tubular cell death in response to early stress stimuli would influence the generation of fibrosis.

Material and Methods

The investigation was conducted on 2–3 month old male Wistar rats, weighing 210–300 g (Department of Physiology, Zagreb University, School of Medicine). In the first part of the study, a preliminary investigation was performed with the animals divided into 6 groups according to the time of sacrifice: 3, 4, 7, 10, 14 and 16 days after surgery. After the animals were sacrificed, the kidneys were removed and sections were processed for histopathological analysis. Following hemalaun eosin (HE) staining, the number of apoptotically changed renal tubular and interstitial cells, renal interstitial collagen deposition, macrophage infiltration, and tubular dilatation, were analyzed. In the first part of the study the time sequence of the occurrence of the histological alterations mentioned above showed that first apoptotic changes of the tubular cells were recognized 3 days after the obstruction and most marked at day 10 after obstruction,

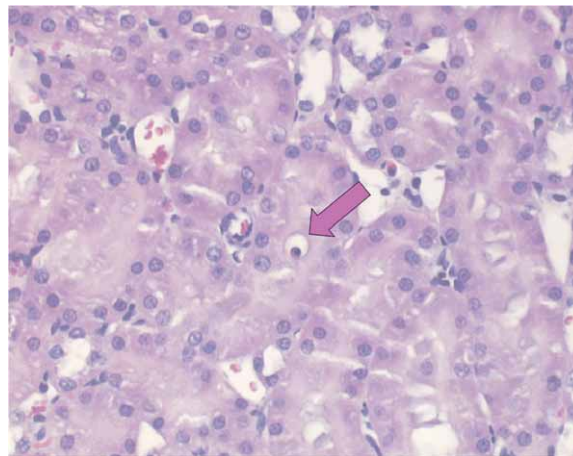


Fig. 1. Renal cell apoptosis after 3 days of unilateral obstruction. Red arrow shows apoptotic tubular cell (HEEx400).

with no significant further alterations until day 16 (Figure 1).

First collagen deposition in the interstitial space of the kidney was recognized at 7th day with continual progression until 16th day. The second part of the investigation included 6 groups of animals, 4 experimental and 2 control groups with 8 animals in each group. According to the results of the preliminary investigation, all experimental animals treated with cilazapril, losartan and vehicle were sacrificed 10 days after surgery.

The rats of the four experimental groups were subdivided into:

- 1) Animals with unilateral ureter ligation treated by:
 - a) ACE inhibitor (cilazapril) at the dose of 10 mg/kg b.w. in 5 mL H₂O p.o. per day for 10 days
 - b) AT1 receptor antagonists (losartan) at the dose of 30 mg/kg b.w. in 5 mL H₂O p.o. per day for 10 days
- 2) Sham-operated animals treated in the same manner as above.

The control groups with unilateral ureter ligation and sham ligation were treated with 5 mL H₂O p.o. per day for 10 days. Based on the results of the preliminary investigation, the animals of all 6 groups were sacrificed 10 days after the procedure, and both kidneys of each animal were stored for histopathological analysis. In each group of animals both kidneys were analyzed.

Establishing unilateral obstructive uropathy

With the animals under ether anesthesia, each rat's abdominal wall was shaved first. Through a midline abdominal incision the left ureter was exposed and ligated using Prolen 4-0 at the transition of the proximal to distal ureter. In the sham-operated animals, the procedure was the same as above except that after preparation and visualization of the left ureter no ligature was placed.

Treatment of rats by ACE inhibitor and AT₁ receptor antagonist

In 5 mL of water 10 mg of ACE inhibitor, i.e. 30 mg AT₁ receptor antagonist was dissolved. The animals were injected with the solution using a modified gastric tube. The control group was treated in the same fashion as above except that 5 mL of water was infused alone.

Collection and preparation of samples

Consistently following the protocol, all animals included in the first part of the investigation were sacrificed on days 3, 4, 7, 10, 14 and 16 after the procedure. Both kidneys were removed, fixed in 4% buffered formalin and subsequently embedded in paraffin wax. In the second part of the investigation, the animals were sacrificed 10 days following the procedure. After both kidneys were removed and cut in the sagittal plane, one half was fixed in 4% buffered formalin. Following fixation, parts of the formalin-fixed kidneys were embedded in paraffin wax, and subsequently 3–5 µm microtome sections were cut. Tissue sections obtained in this way were stained by HE and terminal deoxynucleotidyl transferase-mediated nick end-labeling method (TUNEL) method (TACS XL kit R&D Systems Inc. USA.). Processing of tissue samples was done at the Pliva Research Institute, Zagreb, Croatia (Figure 2).

Histologic analysis

Histologic examination of the kidney samples was performed by a pathologist unaware of the investigation protocol with a Zeiss microscope in 10 visual fields at a magnification of 400 times.

The histologic samples were analyzed as follows:

The area affected by interstitial fibrosis on the paraffin sections was assessed using computer assisted image processing after preparation of samples by Gomory impregnation silver staining. The values obtained in this way are adequate for statistical analysis. The rat kidneys stained with Gomory's silver impregnation method were

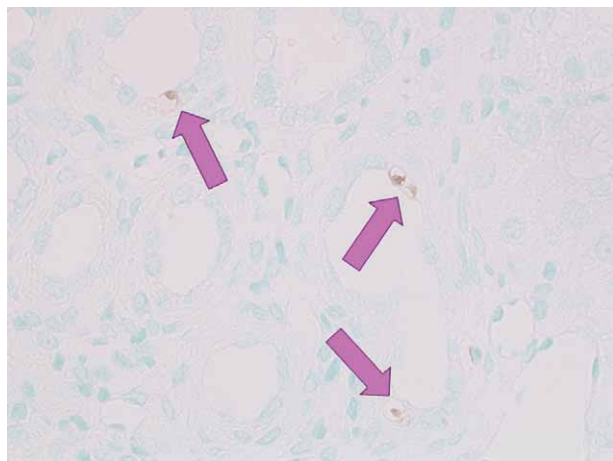


Fig. 2. Renal cell apoptosis after 10 days of unilateral obstruction. Red arrows show apoptotic tubular cell (TUNELx400).

used for sampling. Semiquantitative and morphometric analysis of the preparations was done. The interstitial kidney fibrosis quantification was performed on Gomory stain slides using semiquantitative scale (0 – no reticulin increase; 1 – rare foci of reticulin multiplication; 2 – fine reticulin net around tubules; 3 – dense reticulin net around tubules; 4 – reticulin foci in more than 50% of HPF; 5 – diffuse fibrosis).

Morphometry: 5 visual fields of each kidney's cortex and medulla at x400 magnification were respectively selected at random for analysis. A computer mesh covering the entire field was placed over each visual field (13x10 fields) using the ISSA image processing program (Vamstec, Zagreb, Croatia). Measurement involved the counting of interstitial fibrotic fields per mesh (Figure 3).

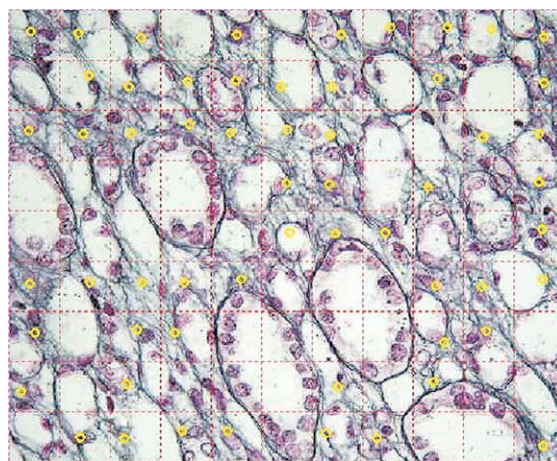


Fig. 3. Histomorphological changes of the rat kidney 10 days after obstruction. Yellow checkmarks refer the fields with fibrotic changes of interstitial space (Gomory, x400).

Fibrosis level obtained by semiquantitative analysis did not showed statistically significant difference between operated experimental groups treated with cizapril, losartan and H₂O. However, there was significant correlation between semiquantitative and morphometric method (Pearson's coefficient $r=0.71$, $p<0.0001$).

The number of apoptoses in renal tubular cell types was analyzed on the basis of the morphological changes in the preparation stained with HE and TUNEL. In each tissue sample a total number of apoptoses was counted and used for comparison and statistical analysis. In analysis, the total number of cells per visual field was presumed to be about equal in all tissue sections regardless of the preparation method.

The results obtained were presented as an arithmetic mean \pm standard error of the mean. Statistical significance of the difference between groups was tested by one-way analysis of variance (ANOVA) with post-hoc Newman-Keuls test for multiple comparisons. For comparison of the results between two independent samples the t-test was used. A value of $p<0.05$ between individual groups was considered to be statistically significant.

Results

Interstitial fibrosis

Interstitial fibrosis developed in all animals after UUO. Histomorphometric analysis of fibrotic changes was performed in medulla and cortex of obstructed and control kidneys.

Experimental animals with obstructed left ureter and treated with losartan and cilazapril had no significant increase in interstitial fibrosis of cortex and medulla compared to the sham ligated kidney (Figure 4).

Number of grid field containing fibrosis per hpf of medulla and cortex of the obstructed kidneys in groups treated with H₂O was significantly higher than in contralateral (unobstructed) kidney ($p < 0.05$) (Figure 4.).

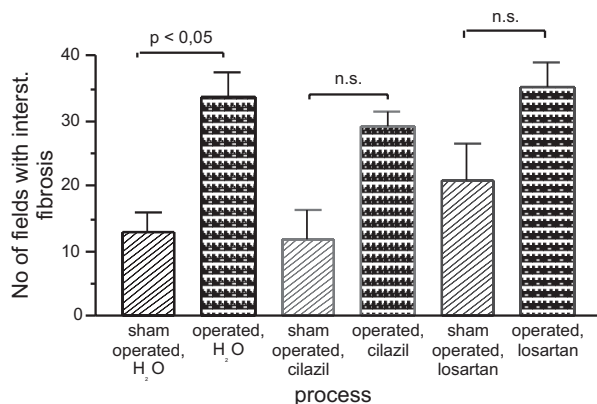


Fig. 4. Histomorphometric analysis of fibrotic changes was performed in medulla and cortex of obstructed and control kidneys in animals treated with cilazil, losartan and H₂O.

We have demonstrated significant correlation between tubular apoptosis and interstitial fibrosis of medulla in operated animals treated with H₂O (Figure 5).

No statistical correlation was proved between tubular apoptosis and interstitial fibrosis of renal cortex in experimental animals treated with cilazapril, losartan or H₂O.

In rats treated with an ACE inhibitor or AT1 receptor antagonist the development of interstitial fibrosis of the kidney medulla has a tendency of correlation with enhanced apoptosis of the tubular cells but there is no statistical significance (Figures 6 and 7).

Discussion and Conclusion

Tubular cell apoptosis is an early event that occurs before the onset of frank fibrosis and thus it can be hypothesized that reducing initial cell death may prevent progression to fibrosis. The time sequence of the occurrence of the histological alterations apoptotic changes of the tubular cells in the first part of the study, were recognized at 3th day after obstruction.

According to histomorphometric analysis first fibrotic changes were recognized 7th day after obstruction. This causal link in our study suggests that apoptotic changes

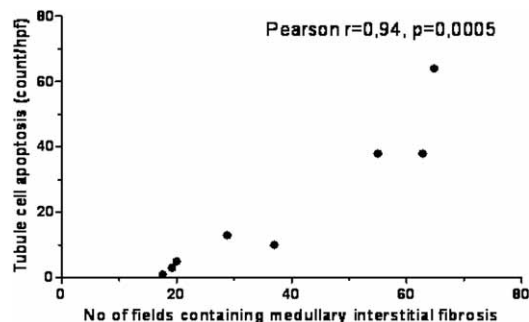


Fig. 5. In this kidney model we have demonstrated significant correlation between tubular apoptosis and interstitial fibrosis of medulla in operated animals treated with H₂O.

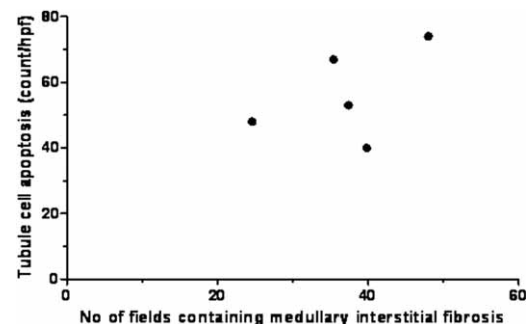


Fig. 6. There is a tendency of correlation between tubular apoptosis and interstitial fibrosis of medulla in animals treated with cilazapril but there is no significant statistical correlation.

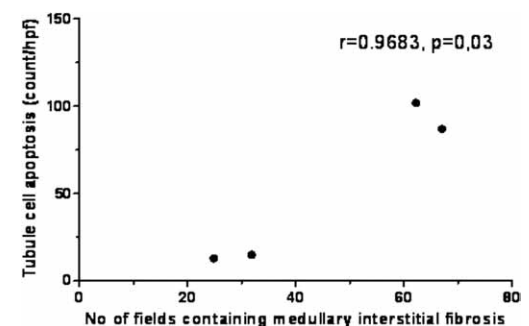


Fig. 7. There is a tendency of correlation between tubular apoptosis and interstitial fibrosis of medulla in animals treated with losartan but there is no significant statistical correlation.

of medullary tubular cells antecede interstitial fibrosis of obstructed kidney.

Studies conducted by various authors investigating the effect of inhibition of type 1 and type 2 Ang II receptors on apoptosis and renal cell proliferation in unilateral ureteral obstruction (UUO) in rats obtained contradictory results⁹.

Tubular cell apoptosis is an important mechanism in renal parenchymal damage in chronic obstructive nephropathy¹⁰.

On the other hand, apoptosis of interstitial fibroblasts and inflammatory cells, which are largely increased in

number in the renal interstitium in obstructive nephropathy may be a mechanism for slowing the progression of chronic obstructive nephropathy¹¹. The discovery of selective mechanisms inducing the apoptosis of renal tubular and interstitial cells would, therefore, allow a novel pharmacotherapeutic approach by halting the progression of chronic obstructive nephropathy.

In this investigation, I tried to influence not only interstitial and tubular cell apoptosis, but also renal interstitial fibrosis by administering angiotensin II inhibitors in unilateral ureteral obstruction in rats. As mentioned above, several cytokines and growth factors have been identified as major contributors to obstruction-induced renal fibrosis and apoptotic cell death, most notably TGF β -1, angiotensin II, NF- κ B and TNF- α .

The role of Ang II, a key factor in the RAS, in inducing and maintaining renal fibrosis in various disorders is definite¹². Bascands and Grande in their studies using classical knockout mice on the RAS system confirmed the role for the AT1 receptor as an important mediator of extracellular matrix accumulation during UUO. Some authors have shown, long before the use of genetically engineered animals that ACE inhibition could be efficient in reducing tubulointerstitial fibrosis in experimental UUO. Besides blocking the conversion of AI into AII, ACE inhibitors also act on the kinin-kalikrein system by inhibiting the degradation of bradykinin which suggests a role for bradykinin in the reduction of UUO induced fibrosis^{13,14}.

Studies by Junwei et al. indicate that there are pathogenic pathways other than RAS which play a role in the development of chronic renal fibrosis. These authors have demonstrated that separate Ang II and HGF blockade is partially effective in slowing the progression of renal interstitial fibrosis in obstructive nephropathy, and that the combination of these two factors gives synergistic benefits which result in a considerably better therapeutic outcome. In this way, particularly targeting RAS by pharmacological ACE or AT1 receptor inhibition may

exceed other potential therapeutic goals for treatment of chronic renal fibrosis¹⁵.

Apoptosis of interstitial fibroblasts and inflammatory cells in the kidneys may be a mechanism which could slow the progression of chronic obstructive nephropathy. The finding of selective mechanisms leading to apoptosis of the renal tubular and interstitial cells would, therefore, allow a novel pharmacotherapeutic approach due to slowing the progression of chronic obstructive nephropathy. Hochberg et al. in their studies of iNOS gene-deficient rats confirmed the possible effect of NO on interstitial fibrosis¹⁶. There have been interesting results of investigations which show that hepatocyte growth factor (HGF), the protein with a multiple function with potent renotrophic properties, may have therapeutic effect in prevention of chronic renal fibrosis^{17,18}. The level of interstitial fibrosis can be determined using several methods, such as semiquantitative scale and morphometric quantification. The morphometric quantification is more sensitive method than semiquantitative scale.

The results of this study indicate that in the group of experimental animals with UUO, there is a correlation between tubular cells apoptosis and interstitial fibrosis of kidney medulla. There was a tendency of correlation between interstitial fibrosis of the kidney medulla with enhanced apoptosis of the tubular cells in rats treated with an ACE inhibitor and AT1 receptor antagonist, but there was no statistical significance.

Acknowledgements

The authors wish to express gratitude to Snježana Čužić, PhD MD for her support and valuable help in detection of apoptotic tubular cells by hematoxylin and eosin (HE) as well as terminal deoxynucleotidyl transferase-mediated nick end-labeling (TUNEL) staining methods.

REFERENCES

1. THORNHILL B A, BURT LE, CHEN C, FORBES MS, CHEVALIER RL, *Kidney Int*, 67(1) (2005) 42. DOI: 10.1111/j.1523-1755.2005.00052.x. — 2. RODRIGUEZ-ITURBE B, JOHNSON RJ, HERRA-ACOSTA J, *Kidney Int*, 68 (2005) 582. DOI: 10.1111/j.1523-1755.2005.09915.x. — 3. KLAHR S, *Sem Nephrol*, 21 (2001) 133. — 4. MANUCHA W, OLOVEROS L, CARRIZO L, SELTZER A, VALLES P, *Kidney Int*, 65 (2004) 2091. DOI: 10.1111/j.1523-1755.2004.00643.x. — 5. KLAHR S, MORRISSEY J, *Am J Physiol Renal Physiol*, 283 (2002) 861. DOI: 10.1152/ajprenal.00362.2001. — 6. SHIN GT, KIM WH, YIM H, KIM MS, KIM H, *Kid Int*, 63 (2005) 897. DOI: 10.1111/j.1523-1755.2005.00154.x. — 7. MISSERI R, MELDRUM KK, *Curr Urol Rep*, 6 (2005) 140. DOI: 10.1007/s11934-005-0083-5. — 8. MISSERI R, RINK RC, MELDRUM DR, MELDRUM KK, *J Surg Res*, 119 (2004) 149. DOI: 10.1016/j.jss.2004.02.016. — 9. JONES EA, SHADED A, SHOSKES DA, *Urology*, 56 (2000) 346. DOI: 10.1016/S0090-4295(00)00608-7. — 10. TRUONG LD, CHOI YJ, TSAO CC, AYALA G, SHEIKH-HAMAD D, NASSAR G., SUKIS WN, *Kidney Int*, 60 (2001) 924. DOI: 10.1046/j.1523-1755.2001.060003924.x. — 11. DOCHERTY NGO, SULLIVAN OE, HEALY DA, FITZPATRICK JM, WATSON RW, *Am J Physiol Renal Physiol*, 290 (2006) 4. DOI: 10.1152/ajprenal.00045.2005. — 12. KIM S, IWAO H, *Pharmacol Rev*, 52 (2000) 11. DOI: 0031-6997/11/5201-0011\$03.00/0. — 13. BASCANDS JL, SCHANSTRA JP, *Kidney Int*, 68 (2005) 925. DOI: 10.1111/j.1523-1755.2005.00486.x. — 14. GRANDE MT, LOPEZ-NOVOA JM, *Nat Rev Nephrol*, 5 (2009) 319. DOI: 10.1038/nrneph.2009.74. — 15. JUNWEI Y, CHUNSUN D, YOUHUA L, YANG S, DAI C, LIU Y, *J Am Soc Nephrol*, 13 (2002) 2464. DOI: 10.1097/01.ASN.0000031827.16102. — 16. HOCHBERG D, JOHNSON CW, CHEN J, COHEN D, STERN S, VAUGHAN ED, POPAS D, FELSEN D, *Lab Invest*, 80 (2000) 1721. DOI: 11092532. — 17. LIU Y, *Curr Opin Nephrol Hypertens*, 11 (2002) 23. DOI: 11753083. — 18. MATSUMOTO K, NAKAMURA T, *Kidney Int*, 59 (2001) 2023. DOI: 10.1046/j.1523-1755.2001.00717.x.

N. Radović

*University of Zagreb, University Hospital Dubrava, Department of Urology, Av. Gojka Šuška 6, 10000 Zagreb, Croatia
e-mail: nikola.radovic@zg.htnet.hr*

UČINAK JEDNOSTRANE OPSTRUKCIJE URETERA I PRIMJENE ANTI-ANGIOTENZINA II NA APOPTOZU I INTERSTICIJALNU FIBROZU BUBREŽNIH TUBULARNIH STANICA U ŠTAKORA

S A Ž E T A K

Rezultat jednostrane opstrukcije uretera (JOU) je gubitak parenhima u bubregu zbog atrofije kanalića, upalnih i fibroznih promjena u intersticiju i apoptoze stanica bubrežnih kanalića i intersticija. Dokazana je povezanost sustava renin-angiotenzin i apoptotskih promjena u bubregu nakon jednostrane opstrukcijske nefropatije. U ovoj studiji je istraživana učinkovitost inhibitora ACE i antagonista receptora AT1 na apoptozu stanica tubula i na intersticijsku fibrozu kod opstrukcijske nefropatije nakon JOU u štakora. Istraživanje je provedeno na štakorima soja Wistar kojima je jednostrano podvezan ureter ili su bili lažno operirani (kontrola). Životinje s podvezanim ureterom obrađene su inhibitorima ACE (cilazapril) ili antagonistima receptora AT1 (lozartan), a kontrolna skupina životinja obrađena je s H₂O. Lažno operirane životinje obrađene su na isti način. Apoptoza stanica u kanalićima i intersticiju je morfološki analizirana nakon bojenja hemalaun-eozinom (HE) i bojanjem terminalne deoksinukleotidil transferaze na 3',-OH krajevima DNA (TUNEL). Površinu intersticijske fibroze na parafinskim prerezima odredili smo pomoću računalne obrade slike nakon impregnacije uzoraka srebrom po Gomoriu. U svim eksperimentalnim skupinama životinja s podvezanim ureterom značajno je povećan broj apoptotskih stanica u kanalićima bubrega u odnosu na suprotni, neopstruirani bubreg. Histo-morfometrijska analiza fibroznih promjena intersticija bubrega u skupinama životinja obrađenih lozartanom ili vodom, pokazala je statistički značajnu razliku ($p < 0,05$) između operiranih i lažno operiranih životinja. Nakon podvezanja jednog uretera dolazi do značajno povećanog broja apoptotskih stanica u kanalićima te fibroze istostranog bubrega u odnosu na suprotni bubreg. Inhibitori ACE i antagonisti receptora AT1 ne mogu smanjiti oštećenja stanica bubrega koja su nastala u tijeku JOU.