

# Amyloidosis of the aortic root in a patient with polyarteritis nodosa

---

Gašparović, Hrvoje; Petričević, Mate; Đurić, Željko; Brida, Vojtjeh; Jelašić, Dražen; Biočina, Bojan

Source / Izvornik: **Collegium Antropologicum, 2014, 38, 1051 - 1053**

Journal article, Published version

Rad u časopisu, Objavljena verzija rada (izdavačev PDF)

Permanent link / Trajna poveznica: <https://um.nsk.hr/um:nbn:hr:105:675710>

Rights / Prava: [In copyright](#)/[Zaštićeno autorskim pravom.](#)

Download date / Datum preuzimanja: **2024-07-24**



Repository / Repozitorij:

[Dr Med - University of Zagreb School of Medicine Digital Repository](#)



# Amyloidosis of the Aortic Root in a Patient with Polyarteritis Nodosa

Hrvoje Gašparović<sup>1</sup>, Mate Petričević<sup>1</sup>, Željko Đurić<sup>1</sup>, Vojtjeh Brida<sup>2</sup>, Dražen Jelašić<sup>3</sup> and Bojan Biočina<sup>1</sup>

<sup>1</sup> University of Zagreb, University Hospital Center Zagreb, Department of Cardiac Surgery, Zagreb, Croatia

<sup>2</sup> University of Zagreb, University Hospital Center Zagreb, Department of Cardiology, Zagreb, Croatia

<sup>3</sup> University of Zagreb, University Hospital Center Zagreb, Department of Pathology, Zagreb, Croatia

## ABSTRACT

*Amyloidosis results from the deposition of insoluble fibrillar proteins in various tissues. Cardiac symptoms, when present, are usually related to congestive heart failure or arrhythmias. Amyloid involvement of the aortic root is exceedingly rare. We describe a case of aortic root amyloidosis in a patient with a long-standing history of polyarteritis nodosa.*

**Key words:** amyloidosis, cardiac, aorta, vasculitis

## Introduction

Reactive amyloidosis occurs secondary to a chronic inflammatory process characterized by fibrillogenesis<sup>1</sup>. While its sequelae may prove to be lethal, a recovery of organ function is possible indicating potential reversibility of the condition<sup>1</sup>. The most common presentations in cardiovascular amyloidosis are restrictive cardiomyopathy and conduction abnormalities<sup>2</sup>. Polyarteritis nodosa is a multisystem necrotizing vasculitis, which most commonly affects the renal and visceral arteries<sup>3</sup>. Hepatitis B antigenemia coupled with the presence of immune complexes may suggest an autoimmune etiology of this type of vasculitis<sup>3</sup>.

## Case Report

We present a 47-year-old woman with a history of polyarteritis nodosa who was referred for surgery due to severe symptomatic aortic regurgitation (AR). In addition to her cardiac condition she also suffered from right subclavian artery occlusion and anacusis. Her hepatitis B serology was negative. Of note, she also had paroxysmal atrial fibrillation (AF). Transthoracic echocardiography (TTE) demonstrated severe AR due to failure of cusp coaptation (Figure 1a). Her left ventricular function was preserved, and the function of the mitral and tricuspid valves was normal. She was found to have pulmonary ar-

tery pressures ranging from 75/60 to 95/70 mmHg. This amplitude of pulmonary hypertension seemed disproportionately high to the setting of isolated aortic valve disease. The ascending aortic diameter was normal. A layer of calcium was seen encircling the aortic lumen. No other echocardiographic signs suggestive of major aortic pathology were observed. The dominant morphologic feature of the aortic valve on intraoperative examination was profound retraction of all three cusps with a resultant lack of central coaptation (Figure 1b). The noncoronary cusp was most severely dysmorphic. Interestingly, the aortic wall intima was uniformly and circumferentially covered with a thin layer of calcium in a fashion that was very dissimilar to the segmental nature of atherosclerotic calcifications. This mandated an extensive aortic root and proximal ascending aortic endarterectomy. The endarterectomized aorta was firm and noncompliant to the touch. The macroscopically abnormal appearance of the aorta prompted us to sample a full thickness segment of the aorta for histologic evaluation. She underwent an aortic valve replacement (AVR) with a mechanical prosthesis. Anchoring of the aortic valve prosthesis proved challenging due to the rigidity of the aortic root. Her AVR was complemented by adjuvant bilateral pulmonary vein isolation, left atrial appendage isolation and ligation coupled with ablation of ganglionic plexi around the ligament of Marshall. Both an intraope-

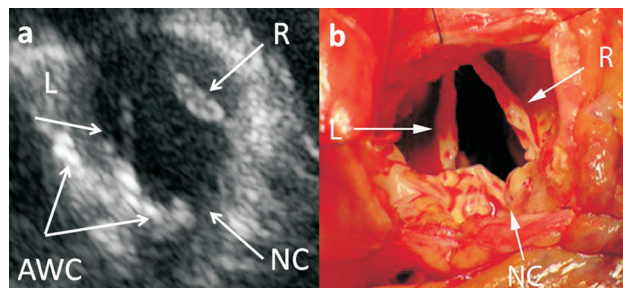


Fig. 1. (a) Short axis view of the aortic valve showing failure of cusp apposition. A circumferential layer of calcium is also noted in the aortic wall. (b) Intraoperative photograph of the retracted aortic valve cusps with a resultant deficiency in central coaptation. The noncoronary cusp was most severely affected. (NC – noncoronary cusp, L – left coronary cusp, R – right coronary cusp, AWC – aortic wall calcification).

rative transesophageal echocardiogram and a follow-up TTE demonstrated a well functioning mechanical valve with no signs of a paravalvular leak.

Histology of the aortic valve showed extensive hyaline degeneration, while the nature of the aortic wall pathology was consistent with reactive amyloidosis on Congo-red staining (Figure 2). Postprocedural systolic pulmonary artery pressures ranged from 45 to 55 mmHg. The




Fig. 2. Histologic examination of the aortal wall stained by Congo red demonstrating green birefringence under polarized light (Congo red, objective x2).

## REFERENCES

1. GILLMORE JD, LOVAT LB, PERSEY MR, PEPYS MB, HAWKINS PN, Lancet, 358 (2001) 24. DOI: 10.1016/S0140-6736(00)05252-1. — 2. HASSAN W, AL-SERGANI H, MOURAD W, TABBAA R, Tex Heart Inst J, (32) 2005 178. — 3. LANGFORD CA, FAUCI AS, The Vasculitis Syndromes. In: FAUCI AS, KASPER DL, LONGO DL, BRAUNWALD E, HAUSER SL, JAMESON JL, LOSCALZO J Harrison's Principles of Internal Medicine (17th ed. New York, NY: McGraw-Hill; 2008). — 4. OBICI

patient enjoyed an uneventful recovery from her surgery, and remains to do well on her most recent follow-up examination 6 months after surgery. Her pulmonary hypertension was alleviated but not completely resolved.

## Discussion

Amyloidosis occurs as an aftermath of the deposition of insoluble fibrillar proteins within different tissues<sup>4</sup>. This leads to structural organ disruption and a wide spectrum of clinical sequelae<sup>1</sup>. Reactive amyloidosis follows a variety of chronic inflammatory processes<sup>1</sup>. Its clinical sequelae parallel the activity of the underlying condition, which in the present case was PAN.

PAN is a rare form of necrotizing vasculitis involving small and medium sized arteries. It is characterized by segmental and transmural involvement of muscular arteries. It affects multiple organ systems. The kidneys, skin, joints, gastrointestinal tract and peripheral nerves are most commonly involved<sup>5</sup>. The initial presentation is one of a non-specific systemic illness, with such symptoms as fever, fatigue and weight loss. Except previously mentioned, no other systemic manifestations of PAN in our patients were documented. The treatment strategy in amyloidosis consists of reduction in the supply of amyloid fibrils, coupled with supportive care<sup>6</sup>.

The definitive diagnosis of amyloidosis in our patient was made on histologic evaluation of aortic tissue. The innocuous appearance of the aorta on preoperative echocardiographic examination was in contrast to its grossly abnormal structure visualized intraoperatively. The described case represents an unusual scenario of aortic insufficiency caused by cusp retraction due to chronic vasculitis coupled with amyloidosis of the surrounding aorta. Since the diagnosis of amyloidosis was unknown at the time of surgery a more radical surgical approach such as replacing the whole aortic root and the ascending aorta was not considered. The technical challenges involving aortic valve replacement in a patient with an inflammatory involvement of the aorta stem from increased tissue fragility. The optimal management strategy of ascending aortic amyloidosis remains to be elucidated, but a lower threshold for replacing the aorta might be considered. The inherent risk of delayed prosthetic valvular detachment must also be recognized<sup>7</sup>. The unpredictable nature of aortic root amyloidosis warrants stringent follow-up and a high index of suspicion for late postoperative complications.

L, PERFETTI V, PALLADINI G, MORATTI R, MERLINI G, Biochim Biophys Acta, 1753 (2005) 11. — 5. OOMURA M, YAMAWAKI T, NARITOMI H, TERAJI T, SHIGENO K, Intern Med, 45 (2006) 655. — 6. SELVANAYAGAM JB, HAWKINS PN, PAUL B, MYERSON SG, NEUBAUER S, J Am Coll Cardiol, 50 (2007) 2101. DOI: 10.1016/j.jacc.2007.08.028. — 7. AOYAGI S, FUKUNAGA S, TAYAMA E, HAYASHIDA N, AKASHI H, KAWARA T, Jpn Circ J, 63 (1999) 885. DOI: 10.1253/jcj.63.885.

*H. Gašparović*

*University of Zagreb, Zagreb University Hospital Center, Department of Cardiac Surgery, Kišpatićeva 12,  
10 000 Zagreb, Croatia  
e-mail: hgasparovic@gmail.com*

## **AMILOIDOZA KORIJENA AORTE U BOLESNIKA S NODOZNYM POLIARTERITISOM**

### **S A Ž E T A K**

Amiloidoza nastaje zbog odlaganja netopljivih fibrilarni bjelančevina u različitim tkivima. Kardijalna simptomatologija, kad je prisutna, obično je vezana za kongestivno zatajenje srca ili poremećaje ritma. Nakupljanje amiloida u korijenu aorte je izuzetno rijetko. Opisujemo klinički slučaj amiloidoze korijena aorte u bolesnika s anamnezom dugogodišnjeg nodoznog poliarteritisa.