

The role of standard echocardiographic parameters in endomyocardial biopsy proven cardiac amyloidosis

Biočić, Stanko; Jakšić Jurinjak, Sandra; Vincelj, Josip; Barić, Davor; Manojlović, Spomenka; Delić Brkljačić, Diana

Source / Izvornik: **Collegium Antropologicum, 2015, 39, 441 - 445**

Journal article, Published version

Rad u časopisu, Objavljena verzija rada (izdavačev PDF)

Permanent link / Trajna poveznica: <https://um.nsk.hr/um:nbn:hr:105:540244>

Rights / Prava: [In copyright](#)/[Zaštićeno autorskim pravom.](#)

Download date / Datum preuzimanja: **2024-07-14**



Repository / Repozitorij:

[Dr Med - University of Zagreb School of Medicine
Digital Repository](#)



The Role of Standard Echocardiographic Parameters in Endomyocardial Biopsy Proven Cardiac Amyloidosis

Stanko Biočić¹, Sandra Jakšić Jurinjak¹, Josip Vincelj^{1,4}, Davor Barić², Spomenka Manojlović³ and Diana Delić Brkljačić^{4,5}

¹ University Hospital Dubrava, Department of Cardiology, Zagreb, Croatia

² University Hospital Dubrava, Department of Cardiac Surgery, Zagreb, Croatia

³ University Hospital Dubrava, Department of Pathology, Zagreb, Croatia

⁴ »J. J. Strossmayer« University, School of Medicine, Osijek, Croatia

⁵ »Sestre milosrdnice« University Hospital Centre, Zagreb, Croatia

ABSTRACT

Primary light-chain (AL) amyloidosis is a plasma cell dyscrasia associated with the deposition of immunoglobulin-derived amyloid in multiple organs. In the heart, this results in an infiltrative cardiomyopathy, with increased left ventricular wall thickness, normal or decreased left ventricular (LV) cavity size and congestive heart failure. Cardiac involvement is a major determinant of prognosis of AL amyloidosis. We report a patient with cardiac amyloidosis proven by cardiac biopsy, and aim to point out at transthoracic echocardiography as the hallmark of diagnostics. Echocardiography revealed increased LV thickness at 20mm, impaired LV ejection fraction (EF) at 35%, enlarged atria, transmitral deceleration time at 156 ms and increased E/A ratio at 4.25. Early diagnosis and intervention can have a significant impact on the patient's response to treatment, especially when the underlying condition involves a malignancy or infiltrative disorder. Standard transthoracic echocardiography as a noninvasive diagnostic tool is valuable and has a significant role in diagnosis and prognosis.

Key words: cardiac amyloidosis, echocardiography, endomyocardial biopsy, infiltrative cardiomyopathy, diagnosis

Introduction

Primary light-chain (AL) amyloidosis is a plasma cell dyscrasia associated with the deposition of immunoglobulin-derived amyloid in multiple organs. In the heart, this results in an infiltrative cardiomyopathy, with increased left ventricular wall thickness, normal or decreased LV cavity size and congestive heart failure. Cardiac involvement is a major determinant of prognosis of AL amyloidosis^{1,2}. In vast majority of cases, the excess production of this protein results from a monoclonal expansion of plasma cells in multiple myeloma, and rarely, a patient with a plasma cell dyscrasia may develop restrictive cardiomyopathy due to deposition of light chains in a nonamyloid manner which seems may be reversible. Three types of amyloidosis that can affect the heart are primary amyloidosis (also known as immunoglobulin light chain amyloidosis), senile systemic amyloidosis, and familial amyloidosis. Secondary amyloidosis may result from chronic

infectious or inflammatory states, where deposits are smaller and are less likely to produce myocardial dysfunction. Familial amyloidosis is an autosomal dominant form, which results from deposition of form of prealbumin, transthyretin, and approximately one quarter of patients with transthyretin-induced familial amyloidosis have cardiac involvement, marked often by conduction system involvement. Primary amyloidosis affects 4.5 of 100,000 individuals^{7,8}. It often occurs in patients over the age of 40, and the median survival of individuals with primary amyloidosis who present with heart failure is six months⁷.

Case report

A 52-year-old woman presented to her physician with a history of fatigue. The diagnosis was hypothyroidism because patient had a total thyroidectomy two years prior,

and was taking substitute hormonal therapy. A year after, because of mild elevated blood pressure she was given ACE inhibitor and beta-blocker in small doses (cilazapril and bisoprolol). After a year she presented to her family physician with a few month history of progressive shortness of breath. At the time of this visit she was able to perform her daily activities, however, she said that her exercise tolerance was affected mainly by fatigue. The patient was referred to cardiologist. An echocardiogram revealed impaired left ventricular systolic function, severe diastolic dysfunction, ventricular wall thickness with small intracavitary chambers, enlarged atria and mild mitral and tricuspid regurgitation. The wall of ventricle was sparkling and granular texture (Figure 1). Echocardiography showed an increased mean left ventricular wall

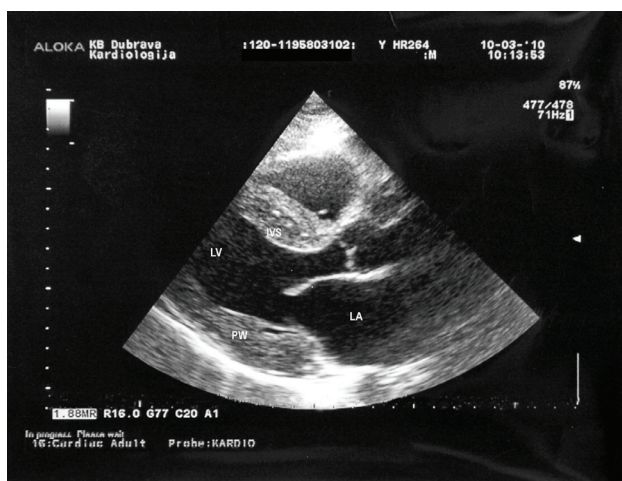

Fig. 1. Non-dilated cardiomyopathy with thickening of the wall of ventricle, sparkling and granular texture, LV left ventricle, LA left atria, IVS interventricular septum, PW LV posterior wall

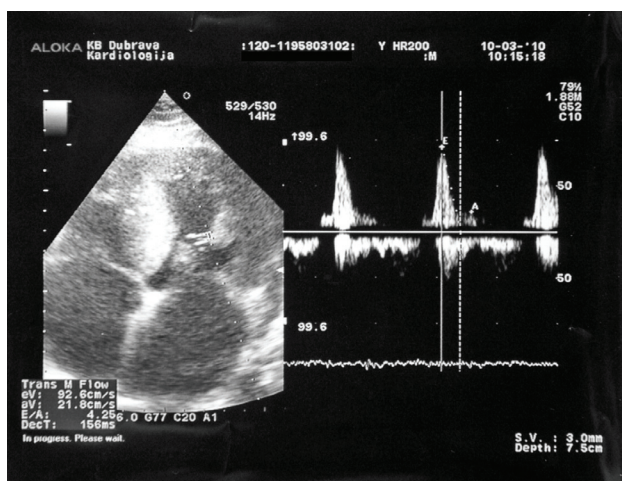


Fig. 2. The deceleration time (DT) of 156 ms and increased early diastolic filling velocity-to-atrial filling velocity (E/A) ratio of 4.25, E early diastolic transmitral velocity, A late diastolic transmitral velocity

thickness (MVT) of 20 mm and an impaired ejection fraction (EF) of 35% on two-dimensional echocardiography. The deceleration time (DT) of 156 ms and increased early diastolic filling velocity-to-atrial filling velocity transmitral (E/A) ratio of 4.25 (Figure 2).

The echocardiographic appearance of thickened ventricle accompanied with low QRS voltage in EKG was characteristic (Figure 3).

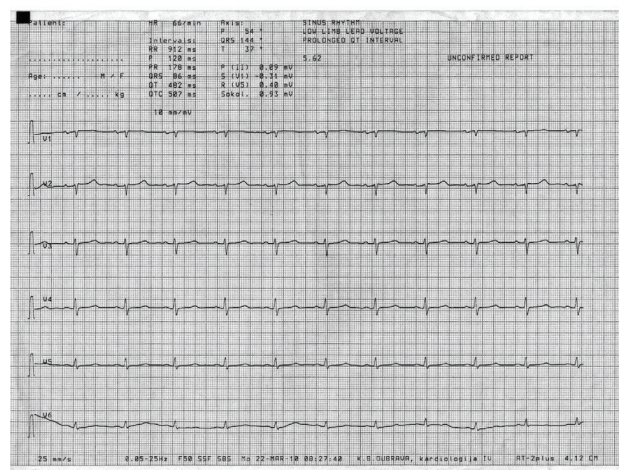
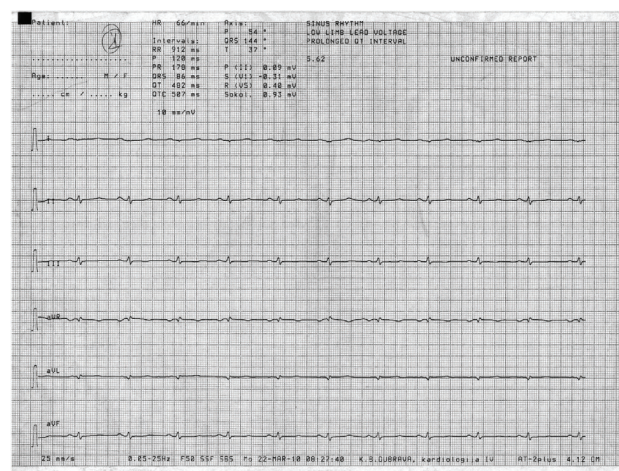


Fig. 3. Low voltage on the ECG

Clinically, the patient was normotensive, had a mild systolic murmur (caused by mitral regurgitation), had no hepatomegaly or pedal edema, chest x-ray showed enlarged heart, and she reported no paroxysmal nocturnal dyspnea and orthopnea.

As there was a marked change in her condition, patient was admitted to our Clinic for further testing. After admittance, a series of investigations were performed, including transthoracic echocardiography, catheterization of the heart, and an endomyocardial biopsy. The pathology findings from the endomyocardial biopsy (EMB) demonstrated features of cardiac amyloidosis, interstitial positiv-

ity for amyloid. Biopsy showed patchy widespread accumulation of material in the interstitium that showed apple green birefringence in polarized light and stained positively with Congo red (Figure 4). These findings are consistent with amyloid protein deposits. Free immunoglobulin kappa light chains in the urine were detected and none were found in serum. The patient was diagnosed with restrictive infiltrative cardiomyopathy, cardiac amyloidosis, NYHA II–III functional class. Patient was treated with low doses of diuretics and had symptomatic benefit and is currently in follow-up. Duration of follow-up in this patient is one year.

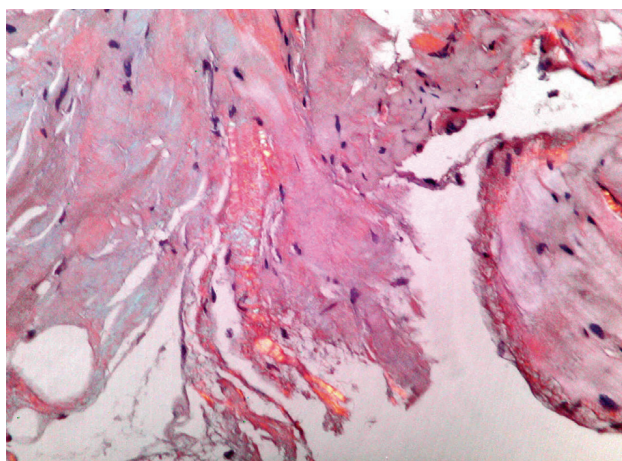


Fig. 4. With Congo red stain, amyloid appears salmon-coloured in ordinary light but shows apple green birefringence in polarized light.

Discussion

Cardiac amyloidosis is characterized as a »stiff heart« syndrome with impairment of diastolic function secondary to amyloid infiltration of the myocardium. Early recognition may improve the poor prognosis of these individuals. Cardiac amyloidosis should be considered when the patient presents with rapidly progressing dyspnea, a non-dilated cardiomyopathy with thickening of the LV wall on echocardiogram, and low voltage ECG with or without a pattern that resembles a myocardial infarction.

Primary amyloidosis results from an accumulation of immunoglobulin light chains due to a clonal B cell disorder such as multiple myeloma. Patients with primary amyloidosis, with heart involvement, progress rapidly and have a median survival of six months once heart failure develops. For senile amyloidosis, the median survival is five years once heart failure develops⁹. The signs and symptoms of congestive heart failure can be recognized easily. However, establishing the underlying cause can be more difficult.

We report a patient with cardiac amyloidosis, and aim to point out at transthoracic echocardiography as the hallmark of diagnostics. Cardiac amyloidosis is characterized

with impairment of diastolic function secondary to amyloid infiltration of the myocardium². Filling patterns are closely related to the degree of amyloid infiltration, as measured by mean left ventricular wall thickness^{2,4,8}. Early cardiac amyloidosis (with a mildly increased mean wall thickness of more than 12 but less than 15 mm) shows an abnormal relaxation pattern characterized by a decreased early filling velocity-to-atrial filling velocity ratio (E/A ratio), a normal-to-prolonged deceleration time, and a prolonged isovolumic relaxation time. Advanced cardiac amyloidosis (markedly increased mean wall thickness of 15 mm or more) shows a short deceleration time and an increasing E/A ratio, which are consistent with restrictive type of diastolic dysfunction⁴.

The combination of the doppler variables of shortened deceleration time and increased early diastolic filling velocity to atrial filling velocity ratio and NYHA functional class are stronger predictors of cardiac death than are the two-dimensional echocardiographic variables of mean left ventricular wall thickness and fractional shortening⁴. This emphasizes that an increased transmitral E/A ratio and a short deceleration time, which are markers of restrictive physiology, are associated with poor outcome in patients with cardiac amyloidosis, because the Doppler factors are more direct measures of hemodynamic function than mean left ventricular wall thickness, which is an indirect measure of impaired diastolic function. Our patient has advanced cardiac amyloidosis with echocardiographic findings of short deceleration time and an increasing transmitral E/A ratio, which are consistent with restrictive type of diastolic dysfunction.

The use of doppler variables adds independent value to the estimation of prognosis in patients with cardiac amyloidosis. Patients with mildly increased wall thickness may still have restrictive type of diastolic dysfunction, which suggests a poorer outcome than that predicted by the measurement of the wall thickness alone. Multiple factors can influence left ventricular diastolic filling variables, including the aging process, loading conditions, heart rate, and valvular regurgitation. Patients with restrictive type of diastolic dysfunction have worse cardiac prognosis, they may be earlier candidates for transplantation.

Multivariate survival analysis identified independent predictors of clinical outcome in patients with AL amyloidosis, New York Heart Association class III or IV, presence of pleural effusion, brain natriuretic peptide level >493 pg/mL, ejection time <273 ms, and peak longitudinal systolic basal antero-septal strain less negative than or equal to -7.5% defined a high-risk group of patients⁵. In patients with endomyocardial biopsy (EMB)-documented cardiac amyloidosis, longer-term survival is more strongly associated with New York Heart Association functional class compared with electrocardiographic and echocardiographic variables⁶. Our patient, who was at the time of diagnosis in NYHA II–III functional class, although she had markedly increased mean wall thickness and restrictive type of diastolic dysfunction is in follow up of one year doing well.

In contrast to standard echocardiography, strain and strain rate are able to demonstrate that significant differences in systolic function occur as cardiac amyloid infiltration progresses to congestive heart failure. Tissue velocity, although a little better than standard 2D echocardiography for the detection of functional abnormalities, was not as good as strain/SR. Standard doppler echocardiography measures velocities of blood flow and is well established for the assessment of hemodynamics and for detecting global abnormalities of diastolic function⁷.

The treatment of AL amyloidosis with high-dose intravenous melphalan and autologous stem cell transplant is a new and effective therapy for AL amyloidosis, although it is best tolerated in patients without severe heart disease. If effective, as defined by a hematologic response, cardiac function assessed by standard echocardiography usually stabilizes, but regression of echocardiographic evidence of heart disease is not usually apparent despite clinical improvement in congestive heart failure. Strain and strain rate are sensitive methods for assessing cardiac function and may possibly detect changes in cardiac function after chemotherapy. Evaluation of patients with these modalities at the time of presentation may help to determine selection of patients for aggressive chemotherapy⁷.

Primary amyloidosis with cardiac symptoms is a devastating disease where symptoms progress rapidly, and patients often only live for months. While the prognosis remains poor, early recognition of the underlying cause of heart failure of unknown origin will facilitate management of a patient with cardiac amyloidosis and aid in attempts to improve the outcome of the patient⁸. Thus, many patients were diagnosed as having cardiac amyloidosis without endomyocardial biopsy. Endomyocardial biopsy is a safe and reliable procedure for diagnosing cardiac amyloidosis, and immunohistochemical staining of routinely

processed biopsy specimens can be performed to classify the type of amyloid present. However, on the basis of autopsy studies, it generally is accepted that the finding of LV thickening by echocardiography in the absence of diseases associated with LV hypertrophy is highly specific for the finding of cardiac amyloid deposition at biopsy or autopsy⁸. A low voltage on the ECG and increased septal and posterior LV wall thickness on the echocardiogram are highly specific for cardiac amyloidosis in the setting of biopsy-proven systemic amyloidosis¹⁰. In older patients without serum or urinary light chains, immunohistochemical staining is recommended to distinguish AL from AS types of amyloid in cardiac biopsy tissues¹⁰. Determination of the underlying cause of heart failure is essential as it will influence the management of the patient.

Conclusion

Standard echocardiography as a noninvasive diagnostic tool is valuable and has a significant role in diagnosis and prognosis of cardiac amyloidosis. Cardiac amyloidosis is characterized by increased left ventricular wall thickness, normal or decreased LV cavity size, and congestive heart failure with normal or near-normal fractional shortening, a marked increase in wall thickness, reduced LV systolic function, shortened deceleration time, and increased early diastolic filling velocity to atrial filling ratio as restrictive type of diastolic dysfunction, wall of ventricle is sparkling and granular texture. Myocardial biopsies must be performed for a definitive diagnosis to be made. Early intervention can have a significant impact on the patient's response to treatment, especially when the underlying condition involves a malignancy or infiltrative disorder therefore transthoracic echocardiography as a noninvasive diagnostic tool is valuable, and has a significant role in diagnosis and prognosis.

REFERENCES

1. KOYAMA J, FALK RH, J Am Coll Cardiol Img, 3 (2010) 333. — 2. KLEIN AL, HATLE LK, TALIERCIO CP, OH JK, KYLE RA, GERTZ MA, BAILEY KR, SEWARD JB, TAJIK AJ, Circulation, 83 (1991) 808. — 3. JARVIE AL, WAECHTER J, MATZKE L, ALLARD M, COURNEYA C, UBCMJ, 2 (2011) 38. — 4. SOKOL I, VINCELJ J, ŠARIĆ M, MEDARH, 59 (2005) 388. — 5. BELLAVIA D, PELLIKKA PA, ALZAHIRANI GB, ABRAHAM TP, DISPENZIERI A, MIYAZAKI C, LACY M, SCOTT CG, OH JK, MILLER FA Jr., J Am Soc Echocardiogr, 23 (2010) 643. — 6. DUFFY B, TAN C, RODRIGEZ ER, STARLING RC, DESAI MY, Am J Cardiol, (2009) 103. — 7. KOYAMA J, RAY-SEQUIN PA, FALK RH, Circulation, 107 (2003) 2446. — 8. KOYAMA J, RAY-SEQUIN PA, FALK RH, Circulation, 106 (2002) 556. — 9. CACOUB P, AXLER O, DE ZUTTERE D, HAUSFATER P, AMOURA Z, WALTER S, WECHSLER B, GODEAU P, PIETTE JC, Ann Med Interne, 151 (2000) 611. — 10. HAMER JP, JANSSEN S, VAN RIJSWIJK MH, LIE KI, Eur Heart J, 13 (1992) 6237.

S. Jakšić Jurinjak

Univesity Hospital Dubrava, Department of Cardiology, Av. Gojka Šuška 6, 10000 Zagreb, Croatia
e-mail: sjaksicj@gmail.com

ULOGA STANDARDNE EHOKARDIOGRAFIJE U AMILOIDOZI SRCA DOKAZANOJ BIOPSIJOM MIOKARDA

SAŽETAK

Primarna amiloidoza je diskrazija plazma stanica sa depozitima amiloida u multiplim organima. U srcu, to rezultira infiltrativnom kardiomiopatijom, zadebljelih stijenki ventrikla, normalnim ili smanjenim šupljinama srca te zatajenjem srca. Zahvaćenost srca je najvažniji prognostički faktor amiloidoze. Prikazujemo pacijenticu u dobi od 52 godine sa biopsijom miokarda dokazanom amiloidozom srca, u cilju prepoznavanja važnosti i naglašavanja ehokardiografskih karakteristika amiloidoze srca te ehokardiografije kao temeljnog dijagnostičkog postupka. Amiloidozu srca karakterizira dijastolička disfunkcija zbog infiltracije miokarda amiloidom. Rano prepoznavanje može poboljšati prognozu bolesnika. Na amiloidozu srca treba posumnjati kod bolesnika sa progresivnom dispnejom, uz nedilatativnu kardiomiopatiju sa zadebljalim stijenkama ventrikla u ehokardiogramu te zabilježenom mikrovoltažom u EKG-u. Pravovremena dijagnoza ima odraza na bolesnikov odgovor na liječenje, osobito ako osnovno stanje uključuju malignitet ili infiltrativni poremećaj, stoga standardna transtorakalna ehokardiografija kao neinvaziva dijagnostička metoda ima značajnu ulogu u dijagnostičkom postupku i prognozi bolesti.