

FOXP1 expression in normal and neoplastic erythroid and myeloid cells

Lovrić, Eva; Horvat Pavlov, Katarina; Korać, Petra; Dominis, Mara

Source / Izvornik: *Collegium Antropologicum*, 2015, 39, 755 - 759

Journal article, Published version

Rad u časopisu, Objavljena verzija rada (izdavačev PDF)

Permanent link / Trajna poveznica: <https://um.nsk.hr/um:nbn:hr:105:475296>

Rights / Prava: [In copyright](#) / [Zaštićeno autorskim pravom](#).

Download date / Datum preuzimanja: **2024-07-16**



Repository / Repozitorij:

[Dr Med - University of Zagreb School of Medicine
Digital Repository](#)



FOXP1 Expression in Normal and Neoplastic Erythroid and Myeloid Cells

Eva Lovrić¹, Katarina Horvat Pavlov¹, Petra Korac² and Mara Dominis³

¹»Mercur« University Hospital, Institute of Clinical Pathology and Cytology, Zagreb, Croatia

²University of Zagreb, Faculty of Science, Department of Biology, Division of Molecular Biology, Zagreb, Croatia

³University of Zagreb, Medical School, Croatia

ABSTRACT

FOXP1 protein was firstly analyzed in normal tissues, and afterwards in different tumor tissues, mainly carcinoma and lymphoma. In B-cell malignancies, its role was well explored; its expression was shown to be connected with disease prognosis in certain B-non Hodgkin lymphomas. In this study, 16 bone marrow trephine samples from patients with no hematopoietic malignancies and 10 samples from peripheral blood of healthy individuals were immunostained with anti-FOXP1 antibody. Positive cells in bone marrows were not only lymphocytes, but also cells that are immunohistochemically positive for glycophorin C or myeloperoxidase. Peripheral blood samples showed no other positive cells, but small round lymphocytes. Additionally 60 samples from patients with myeloid lineage neoplasms were analyzed. 25 samples from patients with myelodysplastic syndrome (MDS) and 35 patients with myeloproliferative disease (MPD) were double immunostained with anti-FOXP1/anti-glycophorin C and anti-FOXP1/anti-myeloperoxidase antibodies. FOXP1 was found to be expressed in 22 cases of MDS and in none of MPD cases. Its expression in MDS was observed mostly in myeloperoxidase positive cells in contrast to glycophorin C positive cells. Only two cases revealed both myeloperoxidase positive cells and glycophorin C positive cells expressing FOXP1 transcription factor. Our results show that FOXP1 is present in normal cells of erythroid and myeloid lineages and thus suggest its possible role in development of all hematopoietic cells as well as possible involvement in neoplasm development of myeloid disorders.

Key words: FOXP1 expression, erythroid lineage, myeloid lineage, haematopoiesis, myeloproliferative disease, myelodysplastic syndromes, CML

Introduction

FOXP1 gene belongs to numerous genes from Forkhead-box gene family, known to be involved in development, organogenesis, and congenital disorders and, as well, carcinogenesis. They code for transcription factors recognizable by characteristic »winged-helix« domain¹. The *FOXP1* gene is located on 3p14.1. Loss of heterozygosity of this region, known to harbor tumor suppressor genes, is frequent event in a wide range of human tumors. In order to investigate expression of the *FOXP1* mRNA in human tissues, Banham et al. in 2001 used hybridization of the *FOXP1* cDNA to a human MTE (micro tissue expression) array. They have found *FOXP1* mRNA in almost all normal tissues, especially lymphoid and gastrointestinal tissues. *FOXP1* mRNA was at that point detected in fetal and adult tissues. The same group also compared *FOXP1* mRNA expression in normal and tumor tissues and found decreased mRNA levels in most tumor counterparts. For

identification of FOXP1 protein expression, they have used JC12, anti-FOXP1 antibody. After immunohistochemical staining FOXP1 was detected in majority of normal tissues as well as in different tumor tissues. In reactive tonsil FOXP1 was present in nuclei of mantle zone B cells, and in nucleus of scattered B cells of germinal centers².

In 2006 Hui Hu et al. published a paper that confirms essential role of Foxp1 in early B cell development and in B lymphopoiesis. The experimental mouse model showed that Foxp1 protein binds to the Erag enhancer and thus impact in specific way VDJ recombination of immunoglobulin heavy chain gene in B-cells³.

In the same year Savarese and Grosschedl showed that Foxp1 has an important role in B-cell development through influence on the expression of RAG genes⁴.

In B-cell malignancies deregulation of FOXP1 expression may play an important role in disease development, but it is still not clear if it acts as an oncogene or has a tumor suppressor function⁵⁻⁹.

While FOXP1 is thoroughly explored in lymphoproliferative diseases and even became one of the key factors for diffuse large B-cell lymphoma prognostic immunohistochemical algorithm¹⁰, its presence and role in non-lymphoid hematopoiesis as well as in myeloproliferative disorders remains unknown.

There are two distinct groups of myeloproliferative disorders: myelodysplastic syndrome (MDS) and myeloproliferative disease (MPD). MDS is a neoplasm that originates from the bone marrow stem cell and is characterized by ineffective hematopoiesis in one or more cell lines. It is considered to be a clonal hematopoietic disorder characterized by cytopenia and bone marrow dysplasia that eventually leads to acute myeloid leukemia. Functional abnormalities of erythroid, megakaryocytic and granulocytic lineages are often seen, while abnormal eosinophils, basophils and mast cells are quite rare. The classification of myelodysplastic syndromes, based on the clinical data and biologic characteristics (morphology, immunophenotype, cytogenetic and molecular biology) given by the French-American-British (FAB) group and later by the World Health Organization (WHO), reveals five main types: refractory anaemia (RA), refractory anaemia with ring sideroblasts (RARS), refractory anaemia with excess blasts (RAEB), refractory anaemia with excess blasts in transformation, (RAEB-t) and chronic myelomonocytic leukaemia (CMML)¹¹⁻¹⁵. Among MDS patients there is one specific group: patients that have neoplastic cells harboring a non-random aberration of deletion between bands q31 and q33 on chromosome 5. »5q- syndrome« group lacks many genes encoding growth factors located on the long arm of chromosome 5. Their clinical behavior is different from other MDS patients – they less frequently show progression to acute myeloid leukemia¹⁶.

On the other hand, MPD is a clonal disorder of multipotent hematopoietic progenitors that includes 3 Philadelphia chromosome negative (Ph-), phenotypically related diseases, and chronic myelogenous leukemia (CML), which is mostly Ph⁺¹⁷⁻²⁰. Polycythemia vera (PV), essential thrombocytosis (ET), and chronic idiopathic myelofibrosis (CIMF) are all believed to be »closely interrelated« disorders characterized by great numbers of nucleated red cells and granulocytes in all stages of maturation with marked hyperplasia and clustering of enlarged mature megakaryocytes. Described and investigated in 1950. by Dameshek W, MPD was suspected to be induced by stimulation of unknown factors or lack of the normal inhibitory factors²¹. In 2005 James C et al. confirmed this hypothesis with finding of loss of inhibitory activity caused by V617F mutation of JAK2 that leads to trilinear myeloproliferation²². Although those findings lead to a possibility of developing targeted therapy, better understanding of this entity development and signaling pathways of the diseases still remain needful.

CML is associated with a characteristic chromosomal translocation t(9;22)(q34;q11), called the Philadelphia chromosome. This clonal bone marrow stem cell disorder represents proliferation of mainly mature myeloid cells. In some cases, it can progress through blastic transformation to acute myeloblastic leukemia and in those cases it

is associated with an extremely high mortality²³⁻²⁵. For CML targeted therapy already exists: few different drugs that inhibit tyrosine kinase (abnormal BCR-ABL protein which is a result of t(9;22)(q34;q11)) are constructed, i.e. imatinib. Such drugs are well-tolerated, but there are some patient groups in which they are toxic and therefore any new insight in factors that contribute to CML course is still notable^{26,27}.

In this study, based on FOXP1 relevance for different tissues development and its regulatory function in lymphocytes, we sought to determine whether it is also expressed in non-lymphoid hematopoietic cells of bone marrow as well as in their neoplastic myeloid counterparts.

Material And Methods

Bone marrow FFPE trephine samples from 16 patients with no hematopoietic malignancies and 10 peripheral blood smears from healthy individuals were morphologically reviewed and immunostained with anti-FOXP1 antibody (JC12 antibody, acquired from Dr Alison Banham, Oxford, UK).

Additionally FFPE bone marrow trephine samples from 60 patients with myeloid disorders were also immunostained with anti-FOXP1 antibody: 25 patients with MDS (6 refractory anemia with excess blasts, 8 refractory anemia, 8 refractory cytopenia with multilineage dysplasia, 3 5q deletion syndrome MDS), 29 with MPD Ph (10 essential thrombocythemia, 8 polycythemia vera and 11 chronic idiopathic myelofibrosis) and 6 with CML.

All cases were, after the examination of immunostaining of FOXP1 protein by pathologists (EL, KH, MD), double stained. Anti-glycophorin C (Dako, Glostrup, Denmark) and anti-myeloperoxidase antibodies (Dako) were used for double labeling along with JC12 antibody for detection of erythropoietic and myelopoietic cells, respectively. Reactive tonsil sections were used as controls in each round of staining. Small, round B-lymphocytes present in all bone marrow samples were considered internal positive controls.

Immunohistochemical double staining was performed on 4 µm thick, formalin fixed paraffin embedded bone marrow trephine sections according to the protocol provided by the manufacturer of the visualization LSAB/HRP kit (Dako) using two different chromogens: DAB chromogen (Dako) for nuclear staining and Vector SG chromogen (Vector Laboratories Inc., Burlingame, CA) for membrane staining.

Triple blind reading was performed for all samples.

This study is a part of a research project approved by the Ethics Committee of the Zagreb University School of Medicine.

Results

Bone marrow trephine samples from all 16 patients with no hematopoietic malignancies showed nuclear positivity after staining with JC12 antibody in 60-80% of small to middle sized cells that occur in islands. Those

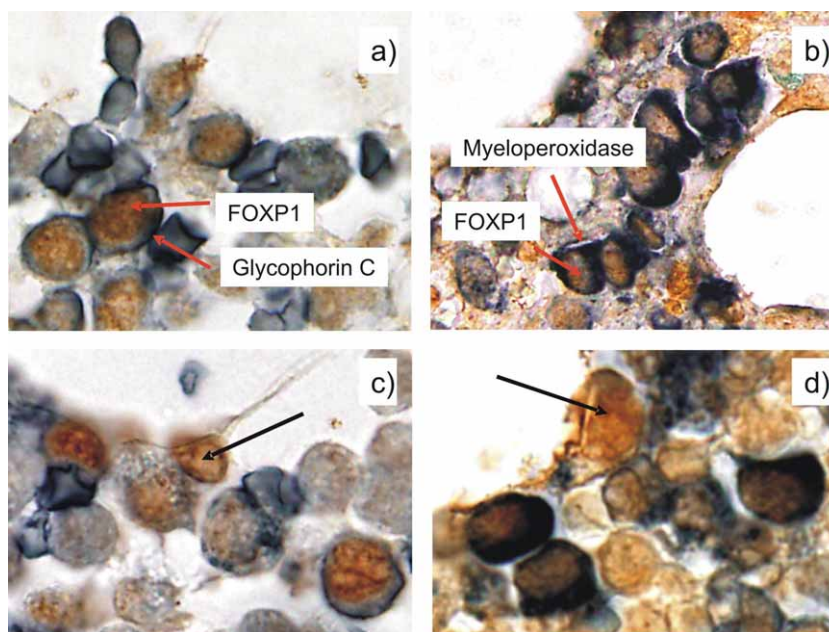


Fig. 1. Immunohistochemical staining in cells of non-tumor bone marrow trephine sections a) cells that express both glycophorin C and FOXP1 b) cells that express both myeloperoxidase and FOXP1 c) cells that express FOXP1 but lack glycophorin C expression and d) cells that express FOXP1 but lack myeloperoxidase expression.




Fig. 2. Immunohistochemical staining in cells of 5q- syndrome MDS bone marrow trephine sections a) cells that express both glycophorin C and FOXP1 b) cells that express both myeloperoxidase and FOXP1.

cells were also immunohistochemically positive for anti-glycophorin C antibody. (Figure 1a)

Same samples showed nuclear positivity after staining with JC12 antibody in 79-85% of large cells with regular nuclei, abundant cytoplasm which were immunohistochemically also positive after staining with anti-myeloperoxidase antibody. (Figure 1b)

Small, round cells with dark large nucleus and small amount of cytoplasm that are diffusely scattered through the interstitium of the bone marrows were, according to their morphology, considered B-lymphocytes. Those cells showed JC12 staining, but were negative for anti-glycophorin C and anti-myeloperoxidase antibodies. (Figures 1c and d).

All peripheral blood smears from healthy individuals showed JC12 staining in nucleus of small, round cells that

correspond to lymphocytes. Morphologically recognizable erythrocytes, granulocytes and agranulocytes were negative after immunostaining with JC12 antibody.

Bone marrow samples from patients with MDS showed versatile FOXP1 positivity. Half cases (3/6) of refractory anemia with excess blasts showed JC12 staining in myeloperoxidase positive cells and the other half had no myeloperoxidase or glycophorin C positive cells with expression of FOXP1. All refractory anemia cases showed FOXP1 positivity in cells also positive for myeloperoxidase. All 8 cases of refractory cytopenia with multilineage dysplasia showed FOXP1 expression in myeloperoxidase positive cells. Only one of those cases showed FOXP1 expression not only in myeloperoxidase, but as well in glycophorin C positive cells. Only one of 5q- syndrome MDS cases had confirmed deletion of 5q region, while for the

other two clinical data were not available and therefore their diagnosis was based only on morphology suspicion. One of those unconfirmed 5q- cases showed FOXP1 expression in myeloperoxidase positive cells, while the other showed FOXP1 expression in glycophorine C positive cells. The only confirmed 5q- syndrome MDS case showed JC12 staining in both glycophorine C and myeloperoxidase positive cells. (Figures 2a and b).

Bone marrow samples from all patients with MPD and CML showed no FOXP1 staining in myeloperoxidase or glycophorine C positive cells.

Discussion

FOXP1 expression was detected by immunohistochemical staining in 16 non-lymphoid haematopoietic bone marrow trephines. Positive staining was detected not only in small, round cells with compact large nucleus and little cytoplasm – cells believed to represent lymphocytes, but also in middle sized cells that occur in islands and large cells with regular nuclei and abundant cytoplasm. Those cells that were unexpectedly immunohistochemically positive for JC12 antibody were also positive for glycophorin C and myeloperoxidase, respectively, suggesting that they might represent developmental stages of erythroid and myeloid lineages. JC12 immunostaining of peripheral blood smears from healthy individuals served as a control of FOXP1 expression in final developmental stages of erythroid and myeloid lineages: erythrocytes, granulocytes and agranulocytes. They all lack FOXP1 expression.

As FOXP1 is a transcription factor known to be expressed in different fetal and adult tissues, thus possibly involved in development of different types of cells², this finding might suggest that FOXP1 is needed for hematopoiesis in developmental stages of all lineages.

We have used bone marrow trephine sections of samples taken from patients without hematopoietic malignancies. Question remains if those cells are representative and if they can be regarded as »normal« or »healthy«. Still, JC12 immunohistochemically positive cells stained with anti-glycophorin C and anti-myeloperoxidase antibodies can not be disregarded.

FOXP1 is also known to be present in different tumors. Depending on type of tumor cells it shows overexpression, lack of expression or cytoplasmic expression². Its role in B-cell non Hodgkin lymphoma development and prognosis is well explored. Not only that its expression is associated

with prognosis in diffuse large B-cell lymphoma, but *FOXP1* gene aberrations were found in cells of mucosa associated lymphoma as well as in diffuse large B-cell lymphoma^{5-7,9,28-30}.

Our results show presence of FOXP1 protein in MDS, but not MPD cells. Based on their cells of origin, this data could imply that neoplasms derived from earlier developmental stages of myeloid lineages need FOXP1 for their progression. This finding also suggests that FOXP1 remains important in myeloid cells even after the initial oncogenic events of these disorders. Interestingly, only two cases showed FOXP1 in both myeloperoxidase and glycophorin C positive cells. 5q- syndrome MDS case and refractory cytopenia with multilineage dysplasia case showed two different types of tumor cells that express FOXP1 transcription factor. As both disorders are derived from bone marrow stem cell, retained FOXP1 expression in two lineages is not unexpected, although it could suggest that those entities are not so distinct as it is believed. In case of refractory cytopenia with multilineage dysplasia expression of same transcription factor in more than one lineage can be hypothesized. 7 other cases of refractory cytopenia with multilineage dysplasia show uniform lack of FOXP1 expression indicating similar oncogenic pathways in all affected cell types. 5q- syndrome MDS case, being the only one with cytogenetic confirmation of the diagnosis in the study, suggests that chromosome 5 in this case lacks genes responsible for differentiation of common myeloid progenitor to proerythroblast and myeloblasts.

Conclusion

Taken together our results demonstrate that FOXP1 is not only present in normal development stages of erythroid and myeloid lineages but that it could also have maintained role in tumors that arise from their earlier stages. Tumors derived from later developmental stages of myeloid lineage show lack of FOXP1 expression thus revealing oncogenic events that do not include this transcription factor.

Acknowledgement

This study was funded by the Croatian Ministry of Science Education, and Sports, research grant no. 108-1081873-1891 and 108-1081873-1893 and T-Hrvatski Telekom grant from competition »Together We Are Stronger«.

REFERENCES

1. KATO M, KATO M, *Int J Oncol*, 25 (2004) 1495. — 2. BANHAM AH, BEASLEY N, CAMPO E, FERNANDEZ PL, FIDLER C, GATTER K, JONES M, MASON DY, PRIME JE, TROUGOUBOFF P, WOOD K, CORDELL JL, *Cancer Res*, 61 (2001) 8820. — 3. HU H, WANG B, BORDE M, NARDONE J, MAIKA S, ALLRED L, TUCKER PW, RAO A, *Nat Immunol*, 8 (2006) 819. — 4. SAVARESE F, GROSSCHEDL R, *Nat Immunol*, 8 (2006) 793. — 5. BARRANS SL, FENTON JA, BANHAM A, OWEN RG, JACK AS, *Blood*, 104 (2004) 2933. — 6. BANHAM AH, CONNORS JM, BROWN PJ, CORDELL JL, OTT G, SREENIVA-

- SAN G, FARINHA P, HORSMAN DE, GASCOYNE RD, *Clin Cancer Res*, 11 (2005) 1065. — 7. SAGAERT X, DE PAEPE P, LIBBRECHT L, VANHENTENRIJK V, VERHOEF G, THOMAS J, WLODARSKA I, DE WOLF-PEETERS C, *J Clin Oncol*, 24 (2006) 2490. — 8. KOON HB, IPOLITO GC, BANHAM AH, TUCKER PW, *Expert Opin Ther Targets*, 11 (2007) 955. — 9. GOATLY A, BACON CM, NAKAMURA S, YE H, KIM I, BROWN PJ, RUSKONÉ-FOURMESTRAUX A, CERVERA P, STREUBEL B, BANHAM AH, DU MQ, *Mod Pathol*, 21 (2008) 902. — 10. CHOI WW, WEISENBURGER DD, GREINER TC, PIRIS MA, BANHAM AH,

DELABIE J, BRAZIEL RM, GENG H, IQBAL J, LENZ G, VOSE JM, HANS CP, FU K, SMITH LM, LI M, LIU Z, GASCOYNE RD, ROSENWALD A, OTT G, RIMSZA LM, CAMPO E, JAFFE ES, JAYE DL, STAUDT LM, CHAN WC, Clin Cancer Res, 15 (2009) 5494. — 11. BRUNNING RD, ORAZI A, GERMING U, LE BEAU MM, PORWIT A, BAUMANN I, VARDIMAN JW, HELLSTROM-LINDBERG E, Myelodysplastic syndromes/neoplasms, overview. In: SWERDLOV SH, CAMPO E, HARRIS NL, JAFFE ES, PILERI SA, STEIN H, THIELEJ, VARIDMAN JW (Eds), WHO classification of tumours of haematopoietic and lymphoid tissues (IARC, Lyon, 2008). — 12. BRUNNING RD, HASSERJIAN RP, PORWIT A, BENNETT JM, ORAZI A, THIELE J, HELLSTROM-LINDBERG E, Refractory cytopenia with unilineage dysplasia. In: SWERDLOV SH, CAMPO E, HARRIS NL, JAFFE ES, PILERI SA, STEIN H, THIELEJ, VARIDMAN JW (Eds), WHO classification of tumours of haematopoietic and lymphoid tissues (IARC, Lyon, 2008). — 13. HASSERJIAN RP, GATTERMANN N, BENNETT JM, BRUNNING RD, THIELE J, Refractory anaemia with ring sideroblasts. In: SWERDLOV SH, CAMPO E, HARRIS NL, JAFFE ES, PILERI SA, STEIN H, THIELEJ, VARIDMAN JW (Eds), WHO classification of tumours of haematopoietic and lymphoid tissues (IARC, Lyon, 2008). — 14. ORAZI A, BRUNNING RD, HASSERJIAN RP, GERMING U, THIELE J, Refractory anaemia with excess blasts. In: SWERDLOV SH, CAMPO E, HARRIS NL, JAFFE ES, PILERI SA, STEIN H, THIELEJ, VARIDMAN JW (Eds), WHO classification of tumours of haematopoietic and lymphoid tissues (IARC, Lyon, 2008). — 15. BRUNNING RD, BENNETT JM, MATUTES E, ORAZI A, VARDIMAN JW, THIELE J, Refractory cytopenia with multilineage dysplasia. In: SWERDLOV SH, CAMPO E, HARRIS NL, JAFFE ES, PILERI SA, STEIN H, THIELEJ, VARIDMAN JW (Eds), WHO classification of tumours of haematopoietic and lymphoid tissues (IARC, Lyon, 2008). — 16. HASSERJIAN RP, LE BEAU MM, LIST AF, BENNETT JM, THIELE J, Myelodysplastic syndrome with isplated del(5q). In: SWERDLOV SH, CAMPO E, HARRIS NL, JAFFE ES, PILERI SA, STEIN H, THIELEJ, VARIDMAN JW (Eds), WHO classification of tumours of haematopoietic and lymphoid tissues (IARC, Lyon, 2008). — 17. THIELE J, KVASNICKA HM, ORAZI

A, TEFFERI A, BIRGEGARD G, Polycythaemia vera. In: SWERDLOV SH, CAMPO E, HARRIS NL, JAFFE ES, PILERI SA, STEIN H, THIELEJ, VARIDMAN JW (Eds), WHO classification of tumours of haematopoietic and lymphoid tissues (IARC, Lyon, 2008). — 18. THIELE J, KVASNICKA HM, ORAZI A, TEFFERI A, GISSLINGER H, Essential thrombocythaemia. In: SWERDLOV SH, CAMPO E, HARRIS NL, JAFFE ES, PILERI SA, STEIN H, THIELEJ, VARIDMAN JW (Eds), WHO classification of tumours of haematopoietic and lymphoid tissues (IARC, Lyon, 2008). — 19. THIELE J, KVASNICKA HM, TEFFERI A, BAROSI G, ORAZI A, VARDIMAN JW, Primary myelofibrosis. In: SWERDLOV SH, CAMPO E, HARRIS NL, JAFFE ES, PILERI SA, STEIN H, THIELEJ, VARIDMAN JW (Eds), WHO classification of tumours of haematopoietic and lymphoid tissues (IARC, Lyon, 2008). — 20. VARDIMAN JW, MELO JV, BACCARANI M, THIELE J, Chronic myelogenous leukaemia, BCR-ABL1 positive. In: SWERDLOV SH, CAMPO E, HARRIS NL, JAFFE ES, PILERI SA, STEIN H, THIELEJ, VARIDMAN JW (Eds), WHO classification of tumours of haematopoietic and lymphoid tissues (IARC, Lyon, 2008). — 21. DAMESHEK W, J Am Ass Med, 142 (1950) 790. — 22. JAMES C, UGO V, CASADEVALL N, CONSTANTINESCU SN, VAINCHENKER WA, Trends Mol Med, 11 (2005) 546. — 23. ENRIGHT H, MCGLAVE PB, Curr Opin Hematol, 2 (1995) 293. — 24. SOKAL JE, GOMEZ GA, BACCARANI M, TURA S, CLARKSON BD, CERVANTES F, ROZMAN C, CARBONELL F, ANGER B, HEIMPEL H, Blood, 72 (1988) 294. — 25. KURZROCK R, TALPAZ M, Br J Haematol, 79 Suppl 1 (1991) 34. — 26. HEISTERKAMP N, GROFFEN, Hematol Pathol, 5 (1991) 1. — 27. ILARIA RL JR, VAN ETTEN RA, J Biol Chem, 271 (1996) 31704. — 28. GOTOH A, BROXMEYER HE, Curr Opin Hematol, 4 (1997) 3. — 29. STREUBEL B, VINATZER U, LAMPRECHT A, RADERER M, CHOTT A, Leukemia, 19 (2005) 652. — 30. WLODARSKA I, VEYT E, DE PAEPE P, VANDENBERGHE P, NOOIJEN P, THEATE I, MICHAUX L, SAGAERT X, MARYNEN P, HAGEMEIJER A, DE WOLF-PEETERS C, Leukemia, 19 (2005) 1299. — 31. FENTON JA, SCHUURING E, BARRANS SL, BANHAM AH, ROLLINSON SJ, MORGAN GJ, JACK AS, VAN KRIEKEN JH, KLUIN PM, Gene Chromosomes Canc, 45 (2006) 164.

P. Korac

University of Zagreb, Faculty of Science, Department of Biology, Division of Molecular Biology, Horvatovac 102a, 10 000 Zagreb, Croatia
e-mail: petra.korac@biol.pmf.hr

EKSPRESIJA FOXP1 U NORMALNIM I NEOPLASTIČNIM STANICAMA ERITROIDNE I MIJELOIDNE LOZE

SAŽETAK

Protein FOXP1 prvo je bio istraživani u normalnom tkivu i različitim tumorskim tkivima, najviše karcinomima i limfomima. Njegova je uloga u B-staničnim neoplazmama dobro istražena, a dokazano je i da je njegova ekspresija u pojedinim B ne-Hodgkinovim limfomima vezana za prognozu. U ovom istraživanju 16 uzoraka biopsija koštanih srži uklopljenih u parafin pacijanata bez hematoloških bolesti i 10 uzoraka razmaza periferne krvi zdravih ispitanika, imunohistokemijski su obojeni anti-FOXP1 antitijelom. Pozitivne stanice u koštanim sržima nisu bili samo limfociti, već i stanice koje su imunohistokemijski pozitivne i na glikoforin C ili mijeloperoksidazu. Uzorci razmaza periferne krvi nisu pokazivali druge pozitivne stanice osim malih, okruglih limfocita. Dodatno je analizirano 60 uzoraka koštanih srži pacijenata s neoplazmama mijeloidne linije. 25 uzoraka bilo je od pacijenata s mijelodisplastičnim sindromom (MDS), a 35 s mijeloproliferativnom bolesti (MPD). Svi su uzorci obojeni dvostrukim imunohistokemijskim bojenjem korištenjem anti-FOXP1/anti-glikoforin C i anti-FOXP1/anti-mijeloperoksidaza antitijela. FOXP1 nađen je u neoplastičnim stanicama 22 uzorka MDS-a, dok tumorske stanice MPD-a nisu pokazivale njegovu ekspresiju. Neoplastične MDS stanice koje eksprimiraju FOXP1 većinom su bile pozitivne i na mijeloperoksidazu. Samo su dva uzorka pokazala ekspresiju FOXP1 proteina i u stanicama pozitivnim na glikoforin C i u stanicama pozitivnim na mijeloperoksidazu. Ovakvi rezultati pokazuju prisutnost FOXP1 proteina u normalnim razvojnim stadijima eritroidne i mijeloidne loze i ukazuju na mogućnost da je on potreban za razvoj svih hematopoetskih stanica. Isto tako ukazuju na mogućnost da FOXP1 ima ulogu u razvoju mijeloidnih neoplazmi.