

Resolution of polyserositis after removal of appendix mucinous cystadenoma

Vujaklija Brajković, Ana; Zlopaša, Ozrenka; Brida, Vojtjeh; Gašparović, Vladimir

Source / Izvornik: **Tohoku Journal of Experimental Medicine, 2015, 235, 25 - 28**

Journal article, Published version

Rad u časopisu, Objavljena verzija rada (izdavačev PDF)

<https://doi.org/10.1620/tjem.235.25>

Permanent link / Trajna poveznica: <https://urn.nsk.hr/urn:nbn:hr:105:226130>

Rights / Prava: [In copyright](#) / [Zaštićeno autorskim pravom.](#)

Download date / Datum preuzimanja: **2025-02-17**



Repository / Repozitorij:

[Dr Med - University of Zagreb School of Medicine
Digital Repository](#)



Resolution of Polyserositis after Removal of Appendix Mucinous Cystadenoma

Ana Vujaklija Brajkovic,¹ Ozrenka Zlopasa,¹ Vojtjeh Brida² and Vladimir Gasparovic¹

¹Division of Intensive Care Medicine, Department of Medicine, University Hospital Centre Zagreb, Zagreb, Croatia

²Department of Cardiology, University Hospital Centre Zagreb, Zagreb, Croatia

Mucinous cystadenoma is a rare benign neoplasm and is usually discovered incidentally. Pleuritis and pericarditis, inflammation of the pleura and pericardium, may represent manifestations of autoimmune disorders especially in female subjects. We report a patient with polyserositis that was resolved after removal of the mucinous cystadenoma. To the best of our knowledge, this is a first report describing pleuritis and pericarditis as an initial presentation of mucinous cystadenoma of an appendix. A forty-year-old Caucasian female patient with a history of pleuritis and recurrent pericarditis was admitted to the hospital due to acute abdomen. At that time she was taking indomethacin and colchicine due to pericarditis that was controlled only with the combination of these two drugs. The patient had elevated erythrocyte sedimentation rate (ESR), increased C-reactive protein (CRP) and normocytic anemia. Immunological tests, including antinuclear antibody, anti-neutrophil cytoplasmic antibody, rheumatoid factor, and anti-cyclic citrullinated peptide antibodies, were repeatedly negative. Emergency surgery revealed acute appendicitis with perforation and subsequent diffuse peritonitis. Histopathological examination showed acute appendicitis and mucinous cystadenoma. Following the surgery the patient did not take any drugs. Fourteen months later the patient was symptom free. Pleuritis and pericarditis in female patients are most often associated with autoimmune diseases. We assume that increased ESR and CRP with anemia detected in the patient may reflect the altered immunity that is due to mucinous cystadenoma. We believe that this report has a broader clinical impact, implying that benign tumor could alter immunity, which can lead to unusual presentation such as polyserositis.

Keywords: appendix; cystadenoma; mucinous; pericarditis; pleuritis

Tohoku J. Exp. Med., 2015 January, 235 (1), 25-28. © 2015 Tohoku University Medical Press

Introduction

Pleuritis and pericarditis, inflammation of the pleura and pericardium, can have many different causes. Both may represent manifestations of autoimmune disorders especially in female subjects. On the other hand, neoplasms of the appendix are rare. They are found in about 1% of appendectomy specimens and accounts for 0.5% of intestinal neoplasms (Connor et al. 1998). Mucinous cystadenoma is a histologic subtype of appendiceal mucoceles and often discovered as an incidental finding during radiologic or endoscopic evaluation (Isaacs and Warshauer 1992). The most frequent symptom is acute or chronic right lower quadrant abdominal pain. Less frequently, patients can have intermittent colicky pain and gastrointestinal bleeding associated with intussusception of the mucocele, intestinal obstruction from mass effect, genitourinary symptoms due

to obstruction of the right ureter or bladder, acute abdomen from mucocele rupture, or sepsis (Landen et al. 1992).

We report a patient with a two-year history of polyserositis that became symptom free after emergency appendectomy. Histopathological examination of the appendix showed inflammation and mucinous cystadenoma.

Case Presentation

A forty-year-old Caucasian female patient with a two-year history of pleuritis and recurrent pericarditis was admitted to the hospital due to acute abdomen. Emergency surgery, exploratory laparotomy, revealed diffuse peritonitis due to perforation of an inflamed appendix. No pseudomyxoma peritonei was observed. Appendectomy was performed, and histopathological examination revealed acute gangrenous appendicitis and mucinous cystadenoma of the appendix. Appendix was 6 cm in length and 1.2 cm in

Received October 27, 2014; revised and accepted December 10, 2014. Published online December 26, 2014; doi: 10.1620/tjem.235.25.

Correspondence: Ana Vujaklija Brajkovic, Division of Intensive Care Medicine, Department of Medicine, University Hospital Centre Zagreb, Kispaticeva 12, 10 000 Zagreb, Croatia.
e-mail: avujaklija@gmail.com

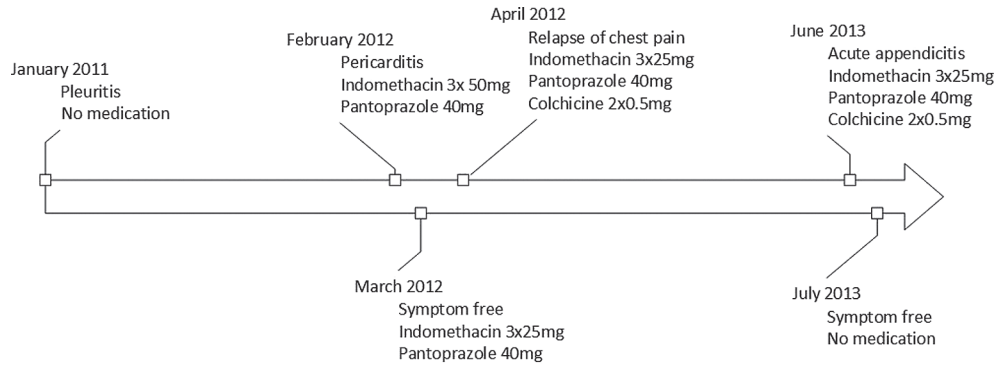


Fig. 1. Clinical course of the patient.

diameter; mucinous cystadenoma was located in the middle of the appendix, 2 cm in length and partially infiltrating the muscle layer of the appendix.

As the first and only presentation of acute abdomen in our patient was pain in the epigastrium we decided to temporarily suspend indomethacin and colchicine. The patient made an uneventful recovery after surgery and was discharged on postoperative day 10. Interestingly, until the day of surgery patient never had stomach ache.

Two years before indexed hospitalization the patient was hospitalized due to pleuritis. Patient's clinical course is summarized in Fig. 1. She was taking no drugs, worked as an economist in a bank and had no occupational exposure. She reported being healthy until the episode of pleuritis. Family history was negative on autoimmune disease. Patient was not married and had no children. Initial evaluation included standard microbiology and virology tests, tuberculin test (PPD, purified protein derivative), Interferon-gamma release assay, immunology tests (complement, anti-nuclear antibody test, rheumatoid factor, and anti-neutrophil cytoplasmic antibody), serum protein electrophoresis, serum immunoelectrophoresis as well as chest computed tomography (CT). Chest CT showed small bilateral pleural effusion, with no lymphadenopathy and no signs of pulmonary embolism. The patient did not allow diagnostic thoracentesis. Thorough evaluation revealed no evident cause of pleuritis, which resolved spontaneously.

A year after the episode of pleuritis the patient was hospitalized due to pericarditis. Extensive diagnostic workup was performed. All immunological tests as well as virology and bacteriology tests were negative. However, the patient had persistently elevated erythrocyte sedimentation rate (ESR), increased C-reactive protein (CRP) and normocytic anemia. Patient had no signs of cardiac tamponade and symptoms eased with indomethacin therapy. Given the above, pericardiocentesis was not done. However, underlying cause of the disease was not found. Most important laboratory test during episodes of pleuritis, pericarditis and appendicitis are presented chronologically in Table 1.

Despite maximum doses of indomethacin the patient had relapse of chest pain a month later. Echocardiography

showed recurrence of pericardial effusion, which is why colchicine was added to indomethacin. The patient was taking medicines for almost a year. Every attempt to reduce the dose of either of medicines resulted in relapse of chest pain and pericardial effusion. After the appendectomy the patient did not take any of the above-mentioned medicine and had no recurrence of pericardial effusion. Fourteen months later she was symptom free and there was no detectable pericardial effusion on echocardiography.

Discussion

We presented a female patient who had a two-year history of pleuritis and one-year history of recurrent pericarditis. Despite meticulous diagnostic evaluation no evident cause of either of the condition was found. Moreover, every attempt to reduce the dose of either indomethacin or colchicine resulted in recurrence of chest pain.

It is known that colchicine, which is a moderate mitose inhibitor, may cause appendicitis. It is possible that colchicine was responsible for appendicitis in our patient. Given the fact that the patient was taking colchicine for almost a year and never had stomach ache it is unlikely that patient had recurrent episodes of appendicitis caused by colchicine.

Mucinous cystadenoma of an appendix is a rare neoplasm. Usually it is asymptomatic and found by chance during diagnostic procedures of unrelated complaints. Since our patient never had stomach ache before indexed hospitalization we believe that mucinous cystadenoma was also asymptomatic in our patient. Interestingly, after appendectomy and removal of the benign tumor patient had no recurrence of pericarditis.

To the best of our knowledge, there are only a few cases of possible association between autoimmune disorders and mucinous cystadenoma. One report found recovery from idiopathic thrombocytopenic purpura following right hemicolectomy for mucocele of the appendix (Kitamura et al. 2005). Following the surgery platelet count increased significantly and platelet-associated immunoglobulin G decreased. Authors did not find pathophysiological explanation for recovery of thrombocyte count. Other two reports described cutaneous mucinosis in patients with systemic lupus erythematosus (Lee et al. 1996) and

Table 1. Results of diagnostic tests: pleuritis (2011), pericarditis (2012) and acute appendicitis (2013).

Variable	Reference range, Adults	2011	2012	2013
Erythrocyte sedimentation rate (mm/hr)	4-24	40	72	64
Erythrocyte count (10^{12})	3.86-5.08	4.22	3.57	3.74
Hematocrit (%)	35.6-47	38	31.8	32.9
Hemoglobin (g/L)	119-157	129	105	109
Mean corpuscular volume (fL)	83.0-97.2	91.8	89.2	87.8
White – cell count (10^9)	3.4-9.7	9.4	7.3	7.7
Differential count (%)				
Neutrophils	44-72	75	70	68
Band forms		0		
Lymphocytes	20-46	16	15	18
Monocytes	2-12	8	13	9
Eosinophils	0-7	1	2	4
Platelet count (10^9)	158-424	178	225	211
C-reactive protein (mg/l)	0-5.0	11.8	181	188.6
Lactate dehydrogenase (U/l)	< 240	162	175	111
Immunoglobulins (g/l)				
IgA	0.7-4	1.7	1.7	
IgG	7.0-16	7.94	7.3	
IgM	0.4-2.3	1.13	0.97	
Rheumatoid factor (IU/ml)	< 20	5.8		
CCP (U/ml)	< 17	< 7		
Antinuclear antibody test (ANA) (titer)	< 1 : 100	negative	negative	
Anti-neutrophil cytoplasmic antibody (ANCA) (titer)	< 1 : 20	negative	negative	
C3 (g/L)	0.9-1.8	1.34	1.48	
C4 (g/L)	0.1-0.4	0.37	0.3	
CH50 (titer)	0.2-0.5	0.4	normal	
Fe (umol/l)	8-30		2	
UIBC (umol/l)	26-59		44	
TIBC (umol/l)			46	
Ferritin (mcg/L)	15.0-150.0		169.7	
Ca 125 (kIU/L)	< 35		56.86	
CEA (mcg/L)	< 3.4		3.52	
CA 15-3 (kIU/L)	< 25		18.52	
T4 (nmol/l)	70-165		79.7	
TSH (mIU/L)	0.4-4.2		1.3	
PPD		positive (20 mm)		
Interferon-gamma release assay		negative		

CCP, anti-cyclic citrullinated peptide antibody; CH50, 50% hemolytic complement; UIBC, unsaturated iron binding capacity; TIBC, total iron binding capacity; CEA, carcinoembryonic antigen; CA 15-3, cancer antigen 15-3; PPD, purified protein derivative.

mucinous cystadenoma of the appendix as a cause of abdominal pain in a female patient with systemic lupus erythematosus (Wirtzfeld et al. 1998). None of the above mentioned articles gave specific explanation for alleviation of symptoms after resection of the mucinous cystadenoma. Maybe mucinous cystadenoma was accidental finding in those patients, but the fact that patients had alleviation of symptoms after treatment of mucocele is evident. Moreover, all of the above mentioned medical conditions have autoimmune etiology.

Pleuritis and pericarditis can be a result of altered immunity. Even though standard immunological tests were repeatedly negative in our patient, ESR was persistently elevated and CRP was increased. Even though ESR and CRP are acute phase reactants they can also be increased in a chronic condition. Normocytic anemia is an anemia of a chronic disease. We assume that changes in ESR, CRP and anemia present a form of altered immunity that connects cystadenoma and polyserositis in our patient.

An association between appendiceal mucoceles and

other tumors involving the gastrointestinal tract, ovary, breast, and kidney has been described (Rutledge and Alexander 1992; Stocchi et al. 2003). Coexistence of the appendix mucinous cystadenoma, tubulovillous adenoma and adenocarcinoma of the colon is described in the literature (Albayrak et al. 2012). Concomitant cases of mucinous cystadenomas and colon cancer have been described with an incidence up to 20% (Zagrodnik and Rose 2003). Another reason for regular check-up of patients with mucinous cystadenoma is a chance for peritoneal dissemination of potentially malignant cells and development of pseudomyxoma peritonei. We performed regular checkups. Colonoscopy is normal and we found no evidence of peritoneal dissemination.

Even though we did not have pathophysiological explanation, we think that mucinous cystadenoma of the appendix was an initial cause for pericarditis, and possibly pleuritis in our patient. We cannot find another explanation for recurrent pericarditis that demanded therapy with both indomethacin and colchicine and resolved after appendectomy and resection of the tumor. We are even more convinced that an association between mucinous cystadenoma and pericarditis exists because no relapse of pericarditis was documented after surgery. Our patient has been symptom free for fourteen months which is maybe too short a period of time to claim that no disease relapse will occur. However, given the fact that soon after every attempt to reduce the dose of either indomethacin or colchicine patient developed chest discomfort, we can assume that this time period is long enough to conclude that mucinous cystadenoma was associated with polyserositis in our patient.

Conflict of Interest

The authors declare no conflict of interest.

References

- Albayrak, Y., Capoglu, R., Kabalar, M.E. & Bayraktutan, U. (2012) Coexistence of appendix mucinous cystadenoma, tubulovillous adenoma of the colon and adenocarcinoma of the colon. *Minerva Chir.*, **67**, 284-285.
- Connor, S.J., Hanna, G.B. & Frizelle, F.A. (1998) Appendiceal tumors: retrospective clinicopathologic analysis of appendiceal tumors from 7,970 appendectomies. *Dis. Colon Rectum*, **41**, 75-80.
- Isaacs, K.L. & Warshauer, D.M. (1992) Mucocoele of the appendix: computed tomographic, endoscopic, and pathologic correlation. *Am. J. Gastroenterol.*, **87**, 787-789.
- Kitamura, T., Nakase, H., Kobayashi, T., Osawa, T. & Tsuchiya, S. (2005) Recovery from idiopathic thrombocytopenic purpura (ITP) following right hemicolectomy for mucocoele of appendix. *J. Gastroenterol.*, **40**, 752-755.
- Landen, S., Bertrand, C., Maddern, G.J., Herman, D., Pourbaix, A., de Neve, A. & Schmitz, A. (1992) Appendiceal mucocoeles and pseudomyxoma peritonei. *Surg. Gynecol. Obstet.*, **175**, 401-404.
- Lee, W.S., Chung, J. & Ahn, S.K. (1996) Mucinous lupus alopecia associated with papulonodular mucinosis as a new manifestation of lupus erythematosus. *Int. J. Dermatol.*, **35**, 72-73.
- Rutledge, R.H. & Alexander, J.W. (1992) Primary appendiceal malignancies: rare but important. *Surgery*, **111**, 244-250.
- Stocchi, L., Wolff, B.G., Larson, D.R. & Harrington, J.R. (2003) Surgical treatment of appendiceal mucocoele. *Arch. Surg.*, **138**, 585-589.
- Wirtzfeld, D.A., Price, L.M., Duggan, M.A., Medlicott, S.A. & Sutherland, F.R. (1998) Mucinous cystadenoma of the appendix in a patient with systemic lupus erythematosus. *Can. J. Gastroenterol.*, **12**, 573-576.
- Zagrodnik, D.F. 2nd. & Rose, D.M. (2003) Mucinous cystadenoma of the appendix: diagnosis, surgical management, and follow-up. *Curr. Surg.*, **60**, 341-343.