

# Infective endocarditis of aortic valve during pregnancy: a case report

---

Vincelj, Josip; Sokol, Ivan; Pevec, Damira; Sutlić, Željko

Source / Izvornik: **International Journal of Cardiology, 2007, 126, e10 - e12**

Journal article, Accepted version

Rad u časopisu, Završna verzija rukopisa prihvaćena za objavljivanje (postprint)

<https://doi.org/10.1016/j.ijcard.2006.12.066>

Permanent link / Trajna poveznica: <https://um.nsk.hr/um:nbn:hr:105:424131>

Rights / Prava: [In copyright](#) / [Zaštićeno autorskim pravom](#).

Download date / Datum preuzimanja: **2024-07-20**



Repository / Repozitorij:

[Dr Med - University of Zagreb School of Medicine  
Digital Repository](#)





### **Središnja medicinska knjižnica**

Vincelj, J., Sokol, I., Pevec, D., Sutlić, Ž. (2007) *Infective endocarditis of aortic valve during pregnancy: A case report*. International Journal of Cardiology, [Epub ahead of print].

<http://www.elsevier.com/locate/issn/0167-5273>

<http://dx.doi.org/10.1016/j.ijcard.2006.12.066>

<http://medlib.mef.hr/262>

University of Zagreb Medical School Repository

<http://medlib.mef.hr/>

**Title page**

**INFECTIVE ENDOCARDITIS OF AORTIC VALVE DURING PREGNANCY: A CASE REPORT**

**Authors:** Josip Vincelj, M.D., Ph.D., F.E.S.C., Ivan Sokol, M.D., M.S., F.E.S.C., Damira Pevec, M.D., and Željko Sutlić, M.D., Ph.D.\*

**Affiliation:** Institute of Cardiovascular Diseases, \*Department of Cardiac Surgery, Dubrava University Hospital, Zagreb, Croatia

**Short title:** Endocarditis of aortic valve during pregnancy

**Address for correspondence and reprints:** Josip Vincelj, M.D., Ph.D., F.E.S.C., Institute of Cardiovascular Diseases, Dubrava University Hospital, School of Medicine, University of Zagreb, Av. G. Šuška 6, HR-10000 Zagreb, Croatia,  
Fax: + 385-1-2902-700,  
E-mail: jvincelj@kbd.hr

**Abstract**

Infective endocarditis during pregnancy is uncommon but very serious. A 31-year-old woman in the 36<sup>th</sup> week of second pregnancy was admitted to hospital because of fever, weakness, chest pain, painful skin over her right leg and dyspnea. Transthoracic echocardiography showed aortic valve vegetation and severe aortic regurgitation. Transesophageal echocardiography revealed a 18 mm x 6 mm mobile vegetation, attached to the right coronary cusp. Emergency cesarean section followed with a delivery of a healthy baby.

Cardiopulmonary bypass with subsequent aortic replacement with bioprosthesis was initiated immediately after cesarean section. Early echocardiographic examination and 6 months after surgery revealed normal function of aortic valve bioprosthesis and normal LV function.

Clinical recognition and early echocardiographic diagnosis followed urgent simultaneous cesarean section and aortic valve replacement was lifesaving both for mother and fetus.

**Key words:** Aortic valve endocarditis; Pregnancy; Echocardiography

## **Introduction**

Incidence of infective endocarditis (IE) during pregnancy has been reported to be 0.006%.

The maternal mortality rate can reach 33%, with the most deaths related to heart failure or an embolic event. The rate of fetal mortality can reach 29% [1]. The high morbidity and mortality rate of IE is the consequence of both the destructive valvular lesions causing valve regurgitation and heart failure, and the valvular vegetations with their high embolic potential [2]. We describe a case with acute severe aortic regurgitation and right superficial femoral artery embolism due to IE in 8 month of pregnancy.

## **Case Report**

A 31-year-old woman with a history of urinary tract infection was admitted to an Obstetrics/Gynecology ward of the local hospital in the 36<sup>th</sup> week of pregnancy with the septic symptoms, weakness, chest pain and dyspnea. Two weeks prior she had fever of 39.5 °C. The blood cultures were negative. She was treated previously for 2 weeks by her gynecologist for the urinary tract infection with cephuroxime and paracetamol. She also had a history of right calf pain 4 weeks prior to hospital admission for which she sought no medical assistance. Three days after admission to the hospital she had right superficial femoral artery embolism detected by Doppler echosonography. After a 4-day history of clinical deterioration she was transferred to the Coronary Care Unit of our hospital. She presented with clinical signs of severe heart failure (NYHA class III). In clinical finding there were increased heart rate of 120/min, blood pressure was 105/55 mmHg, a diastolic murmur could be heard at the left sternal edge, and a systolic murmur of grade 1/6 could be heard at the apex and pulmonary rales. Also there were weakened peripheral pulses of the right leg. In laboratory findings there was increased sedimentation rate: 74 mm/h, leukocytosis: 15700, hemoglobin value: 9,3 g/dl and mild thrombocytopenia: 125000. Transthoracic and transesophageal echocardiography revealed a 18 mm x 6 mm mobile vegetation attached to the right coronary

cuspid (Figure 1, 2) with severe aortic regurgitation (gr. 4) (Figure 3). The vegetation was seen in LV outflow tract during diastole and in aortic root during systole. Gynecologic ultrasound revealed a longitudinal position of the fetus with normal heart action and estimated duration of pregnancy of 36 weeks. After taking blood and urine cultures therapy with penicillin and gentamycin was applied. A decision was made to perform an urgent cesarean section followed by aortic valve replacement. Patient was informed of the potential risks and complications of the procedure and she has chosen to have a bioprosthesis implanted to be able to carry out another pregnancy in the future.

A cesarean section was performed with delivery of a healthy male baby 47 cm in length and 2530 gr in weight, Apgar values 10/10. After completion of the cesarean section patient was heparinized with 3 mg/kg of heparin. Hypothermic (29 °C) cardiopulmonary bypass (CPB) was established in a routine fashion. Cold blood cardioplegia (Buckberg) was utilized for myocardial protection, delivered both anterogradely and retrogradely.

Surgical inspection of the native aortic valve revealed a left coronary leaflet completely destructed by endocarditis as well as fused right and non- coronary leaflets with a vegetation attached to the right coronary leaflet. There was also a small 2 mm x 4 mm subannular abscess in the ventricular septum which was excised, debridged and left open to drain into ventricular cavity. A 19 mm Medtronic Mosaic porcine bioprosthesis (Medtronic Inc., Minneapolis, MN, USA) was implanted in intraannular fashion. After uneventful disconnecting from CPB, patient was transferred to the ICU in stable hemodynamic condition with inotropic support with dopamine which was discontinued during the first 12 hours. Ablactation with bromocryptine 2.5 mg bid was started on postoperative day two and continued for 2 weeks. Antibiotic treatment was continued for 6 weeks with vankomycin, gentamycin and rifampicin. All blood cultures drawn preoperatively were found to be sterile. Postoperative course was uneventful and patient was released on postoperative day 37.

Early echocardiographic examination and 6 months after surgery revealed normal function of aortic valve bioprosthesis and normal LV function.

### **Discussion**

This report describes a successful treatment of aortic valve endocarditis in late pregnancy by simultaneous cesarean section followed by immediate aortic valve replacement.

Infective endocarditis is a rare but life-threatening complication of pregnancy. Over the past three decades, however, improved medical and surgical management of pregnant woman with heart disease has greatly reduced the maternal and fetal mortality rates, and the most recent collective study has indicated overall maternal and fetal mortality rates of 22.1% and 14.7%, respectively, in pregnant woman with infective endocarditis [3]. The diagnosis of endocarditis in pregnancy is difficult due to the common occurrence of heart murmurs and the use of antibiotics for other infective conditions such as urinary tract infections as was the situation in our case. In clinical management of pregnant woman with infective endocarditis the most important issue is to save both maternal and fetal lives. To minimize the maternal and fetal risks the first choice of treatment should be medical, however, in cases that are refractory to medical treatment, corrective cardiac operations are unavoidable.

In our case, TTE and TEE as well as CW and color Doppler were important for the diagnosis of aortic valve endocarditis in pregnancy. In our case both the maternal and fetal risk were very high. The risk can be reduced by early diagnosis and immediate intervention.

Blood culture negative IE is observed in about 10% of cases. In our case negative blood culture may be explained by prior antibiotic treatment. Recent improvements in neonatal care have improved the survival of premature infants of greater than 28 weeks of gestation. For these reasons, elective delivery by cesarean section just before CPB after heparinization and cannulation of the mother but before commencing CPB in the third trimester has been advocated for minimizing maternal and fetal risk. Consequently, in late pregnancy, several

strategies may be considered according to haemodynamic status of the mother. If it is possible to maintain haemodynamic stability with diuretics, antibiotic therapy is administered and cesarean section or vaginal delivery is performed, and cardiac surgery is electively planned after a few days [4]. If urgent or emergent cardiac surgery is indicated, cesarean section is usually performed prior to valve replacement surgery [5]. Treatment modalities should be considered individually according to length of pregnancy and haemodynamic status of pregnant woman.

Our observations show that transthoracic and transesophageal echocardiographies are important for the diagnosis aortic valve endocarditis in pregnancy. Clinical recognition and early echocardiography diagnosis followed urgent simultaneous cesarean section and aortic valve replacement were lifesaving both for mother and fetus.



**References**

1. Montoya ME, Karnath BM, Ahmad M. Endocarditis during pregnancy. *South Med J* 2003;96:1156-7.
2. Habib G. Management of infective endocarditis. *Heart* 2006;92:124-30.
3. Campuzano K, Roque H, Bolnick A, Leo MV, Campbell WA. Bacterial endocarditis complicating pregnancy: case report and systemic review of the literature. *Arch Gynecol Obstet* 2003; 268: 251-5.
4. Iwakura A, Kusuhara K, Shiraishi S, Ono H. A case report of successful mitral valve replacement for infective endocarditis during pregnancy. *Kyobu Geka* 1998;5:583-5.
5. Westaby S, Parry AJ, Forfar JC. Reoperation for prosthetic valve endocarditis in the third trimester of pregnancy. *Ann Thorac Surg* 1992;53:263-5.

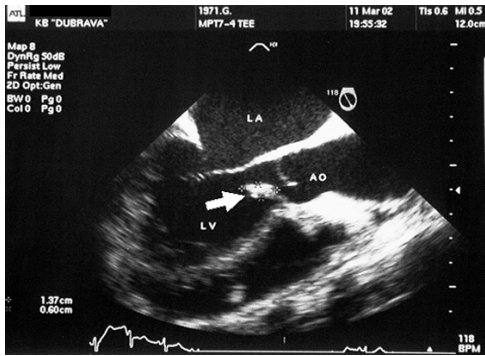


Figure 1. Transesophageal long-axis view showing vegetation attached to the right coronary cusp (arrow). (AO = aorta; LV = left ventricle; LA = left atrium.)

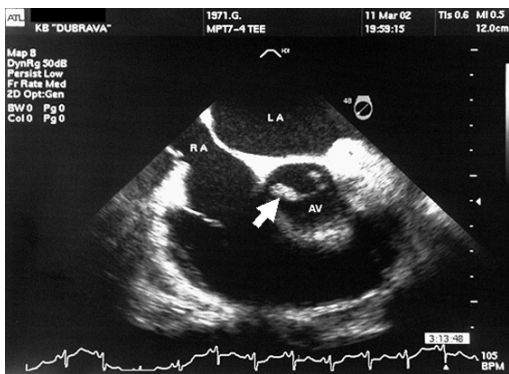


Figure 2. Transesophageal short-axis view showing vegetation attached to the right coronary cusp (arrow). ( AV = aortic valve; LA = left atrium; RA = right atrium.)

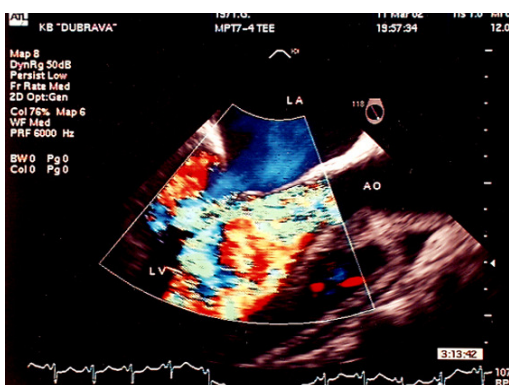


Figure 3. Transesophageal color Doppler image demonstrating severe aortic regurgitation. (AO = aorta; LV = left ventricle; LA = left atrium.)