

# Death by band-aid: fatal misuse of transdermal fentanyl patch

---

**Baković, Marija; Nestić, Marina; Mayer, Davor**

*Source / Izvornik:* **International Journal of Legal Medicine, 2015, 129, 1247 - 1252**

**Journal article, Accepted version**

**Rad u časopisu, Završna verzija rukopisa prihvaćena za objavljivanje (postprint)**

<https://doi.org/10.1007/s00414-015-1209-z>

*Permanent link / Trajna poveznica:* <https://um.nsk.hr/um:nbn:hr:105:113363>

*Rights / Prava:* [In copyright](#) / [Zaštićeno autorskim pravom.](#)

*Download date / Datum preuzimanja:* **2024-07-29**



*Repository / Repozitorij:*

[Dr Med - University of Zagreb School of Medicine  
Digital Repository](#)





## Središnja medicinska knjižnica

**Baković M., Nestić M., Mayer D. (2015) *Death by band-aid: fatal misuse of transdermal fentanyl patch*. International Journal of Legal Medicine, 129 (6). pp. 1247-52. ISSN 0937-9827**

<http://www.springer.com/journal/414>

<https://link.springer.com/journal/414>

The final publication is available at Springer via  
<https://doi.org/10.1007/s00414-015-1209-z>

<http://medlib.mef.hr/2717>

University of Zagreb Medical School Repository

<http://medlib.mef.hr/>

Authors:

Bakovic Marija, Nestic Marina, Mayer Davor

Title:

Death by band-aid: fatal misuse of transdermal fentanyl patch

The affiliation and address of the authors:

Institute of Forensic Medicine and Criminalistics, School of Medicine,

University of Zagreb

Šalata 11

10 000 Zagreb

Croatia

Corresponding author:

Mayer Davor

[dmayer@mef.hr](mailto:dmayer@mef.hr)

telephone: +385 91 5753 105

fax: +385 1 4590 221

**Abstract**

We present a case of fatal intoxication by the application of a transdermal fentanyl patch upon a superficial bleeding abrasion of a 2-year-old girl. The grandmother discovered the body of the child in bed at approximately 7 a.m. External examination revealed a properly developed, nourished and hydrated child, with some vomit in the nostrils and inside the mouth. There was no evidence of trauma besides small contusions and abrasions on knees, with a patch placed over the largest abrasion. Closer inspection revealed that this was transdermal fentanyl patch. Internal examination and microscopic analysis revealed regurgitation of stomach content, cerebral and pulmonary edema and liver congestion. Toxicology analysis revealed trace levels of fentanyl in the blood just above the limit of detection (2 ng/mL), while concentrations in the urine, liver and kidney were approximately 102, 28 and 10 ng/mL, respectively. Investigation discovered that the child injured her knee while playing the evening before. The grandmother applied the patch to cover the injury, unaware that she had used a fentanyl transdermal patch instead of simple band-aid.

Although fatal intoxications are uncommon among young children in high-income countries, it is of major interest to raise awareness of such events especially since a great majority of these are preventable. The presented case points at the need for more thorough education of users and more strict rules in prescribing and handling of this potent medicine. As well, we find this case to be a useful contribution to the evaluation of postmortem fentanyl concentrations in fatal intoxication in a small child.

**Keywords**

child fatality, fatal intoxication, transdermal fentanyl patch, postmortem, skin abrasion

## **Introduction**

Unnatural causes of death in children younger than 4 years of age accounted for 8.81% of all causes of death in developed countries in year 2008, according to the World Health Organization [1]. Road traffic accidents and drowning were most common while poisoning was a rare event represented with 2% of all unnatural deaths and 0.15% of all deaths in this age group [1].

Substances usually identified as the causative agent in fatal poisoning in children less than 5 years of age are divided into pharmaceutical and non-pharmaceutical agents, in similar proportion of incidence [2]. The most frequent pharmaceutical agents in fatal poisoning are opioid analgesics, cardiovascular drugs and paracetamol [3]. Unlike fatal poisoning, nonfatal poisoning is rather common among children. According to the Annual Reports of the American Association of Poison Control Centers' for years 2010 and 2011, over 1 million of poison exposures among children younger than six years of age are reported in United States every year [2, 4]. A great majority of poisonings in this age group are unintentional and occur at home (90%) [2, 4].

Fentanyl is a very potent synthetic  $\mu$ -opioid receptor agonist widely used in anesthesia or as an analgesic for intense chronic pain treatment. It is available for oral transmucosal and parenteral administration, as well as for transdermal use. In chronic pain treatment, fentanyl is commonly used in the form of transdermal patches which are available in doses of 12, 25, 50, 75 and 100  $\mu\text{g}/\text{h}$ . The emergence of effects of fentanyl (analgesia, hypoventilation, sedation, coma, respiratory and central nervous system depression and death) depends upon the dose, patients' tolerance of opioids and serum fentanyl concentrations.

Adverse reactions in the form of life threatening conditions due to improper use of the fentanyl transdermal patch in children have been reported [5-8], as well as fatalities [9-11].

Herein we present a case of fatal poisoning caused by application of transdermal fentanyl patch on bleeding wound of a 2-year old child.

## **Case history**

A 2-year-old girl was found dead at approximately 7 a.m. by her grandmother who had put her to bed evening before. Upon arrival to the scene, the emergency medical team was only able to confirm death. During the morning, the attending coroner examined the body. The body was sent to postmortem examination which was performed the following day. The external examination revealed a properly developed, well nourished (91 cm long, weighting 12 kg) and hydrated female child. A trace of dark vomit was visible in the nostrils and inside

the mouth. There was no evidence of external trauma except for the small contusions and abrasions on both knees and lower legs. A patch had been placed over the biggest abrasion (2x2 cm) located on the front side of the right knee. A closer look revealed that this wasn't a simple band-aid commonly used to treat superficial injuries. It was a rectangular, semi-translucent patch with the light imprint "Durogesic 25 µg/h". Internal examination and following microscopic analysis of sampled tissues revealed stomach content inside the esophagus, trachea and bronchi, cerebral and pulmonary edema, and liver congestion. Samples of body fluids (femoral blood, urine and gastric content) and tissues (liver and kidney) were taken for subsequent toxicology analysis.

Toxicology analysis revealed the presence of fentanyl in the femoral blood, urine, liver and kidney samples, while the gastric content showed no traces of fentanyl (Table 1 and Figure 1).

Sample	Fentanyl (ng/mL or ng/g)	Alcohol (g/kg)	Carboxyhemoglobin (%)
Femoral blood	Trace (LOD=2)	not detected	not detected
Urine	102	not detected	
Liver	28		
Kidney	10		
Gastric content	not detected		

Table 1: Results of toxicology analyses of fluids and tissues – the concentrations of fentanyl are approximate (pharmaceutical solution was used due to the lack of an internal standard)

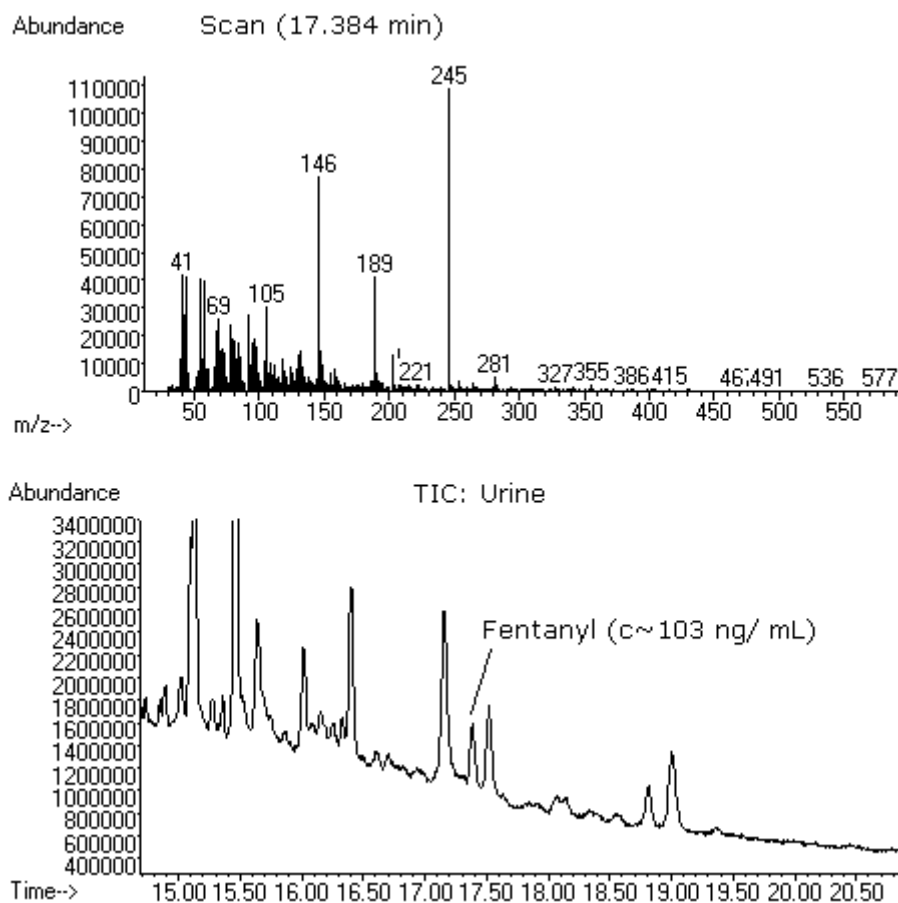


Figure 1: Total ion chromatogram of the urine sample and mass spectrum of the fentanyl

The victims' family was invited to bring the patches they used to treat the abrasion on the knee and what they brought were two unused Durogesic 25  $\mu\text{g}/\text{h}$  transdermal patches.

The following investigation revealed that the child came with the parents to visit the grandmother. During the afternoon, while playing in the courtyard, around 6:30 p.m., the child fell to the ground and injured her right knee. The abrasion bled fairly well so the grandmother placed the patch directly on the wound to stop the bleeding. During the next couple of hours the child continued to play without any apparent mood change. At approximately 9 p.m. the child stated that she was sleepy and, only few minutes after, fell asleep in her grandmothers' lap. This time of evening was the child's usual bed time so the parents decided to leave her at her grandmothers' place. During the night, at approximately 1 a.m., the grandmother heard the child breathing harder, wheezing and snoring, so she placed her on her side which, allegedly, helped child breathe easier. At approximately 7 a.m., the grandmother found the child lying in the bed at the same position, with her body cold and initially rigid.

Two additional fentanyl transdermal patches were found by parents at grandmothers' place. The origin of the patches remained unrevealed. None of the family members had a prescription for the usage of transdermal fentanyl patch and the grandmother could not recall (or decided not to tell) how she came to possess the transdermal fentanyl patches. Records at the grandmothers' general practitioner were devoid of any medical condition that could be connected with the need for serious analgesic treatment.

Once the police investigation concluded, the authorities charged the grandmother with death by negligence.

## **Materials and methods**

Biological samples collected during the autopsy were submitted to toxicology analysis.

### **Chemicals and standards**

A 10 mL ampule of Fentanyl Torrex 50 µg/mL solution for injection (Chiesi Pharmaceuticals GmbH, Vienna, Austria) was used as the calibration standard. Methanol, chloroform, ethyl acetate, sodium hydroxide and acetic acid were pro analysis grade (Kemika Zagreb, Croatia). L-Cysteine BioUltra was purchased from Sigma-Aldrich (Steinheim, Germany). Polymeric adsorbent Supelco-Amberlite® XAD®-2 was purchased from Sigma-Aldrich (Bellefonte, PA, USA). Supelco Reusable sample cleanup columns, Champagne design (160 mm long, 36 mm I.D., 6 mm stem I.D.) was purchased from Sigma-Aldrich (Taufkirchen, Germany).

### **Sample preparation**

Collected biological samples were prepared using the following method: 100 mg of L-Cysteine, 3 mL of water and 1 mL of concentrated HCl were added to biological samples (5 mL or 5 g tissue homogenate); samples were hydrolyzed at 90°C for 30 min, cooled to room temperature, adjusted to pH 8-9 with 0.1M NaOH and filtrated before extraction. Glass SPE column filed with Amberlite XAD-2 resin was activated with 25 mL of methanol and 10 ml of 0.01M NaOH. Prepared samples were drawn slowly through the column. The column was washed with 25 mL of water and eluted with 25 mL of chloroform:ethyl acetate (2:3, v/v). Liquid-liquid extraction of gastric content (1 mL) was performed with 5 mL of chloroform. Quantification in urine, kidney and liver was performed by means of standard addition of 50 and 100 ng/mL or ng/g of fentanyl.

The concentrations of alcohol in blood and urine samples were determined using head space gas chromatography.



The carboxyhemoglobin concentration was determined by Heilmeyer method using VIS-spectrophotometer.

#### Instrumentation

The gas chromatography – mass spectrometry (GC–MS) analyses were performed using Agilent 5973N Mass Selective Detector, 6890 Gas Chromatograph and 7683 Automatic Liquid Sampler equipped with an Elite–5 capillary column (25 m × 0.32 mm ID, 520 nm film thicknesses). The analyses were performed using total ion monitoring mode. Sample volume of 1 µL was injected in splitless mode. The temperatures at the injector, MS interface, electron impact source and mass filter were set at 250°C, 280°C, 230°C and 150°C respectively. The initial set point of a carrier (helium) was 0.5 mL/min. The initial oven temperature of 90°C was held for 3 min, increased to 270°C at a rate of 15°C/min, then increased to 300°C at a rate of 10°C/min and held for 17 min.

The fentanyl was identified according to its retention time and three characteristic ions ( $m/z$  245, 146, 189). The most abundant ion was used for quantification and the second and third ions were used for the confirmation.

#### Method validation

The selectivity of the method was tested on ten post-mortem blood samples and there were no signals interfering with the signal of the fentanyl.

Limit of detection (LOD) was estimated by spiking blank blood samples with calibration standards in the range from 1 to 5 ng/mL with step of 1 ng/mL. Each level was repeated five times. Based on a signal-to-noise (S/N) ratio of 3, a LOD of 2 ng/mL was achieved.

Inter-day precision and accuracy were determined at two different concentrations in five consecutive days. The blood samples were spiked with fentanyl at low (5 ng/mL) and high (100 ng/mL) calibration levels. Accuracy is expressed as a percent deviation from the accepted reference value and was within  $\pm 5.0\%$ . Precision is expressed as relative standard deviation (RSD, %) and was within 12.3%.

#### Results

Results of the toxicology analysis of fluids and tissues are shown in Table 1. Qualitative analysis confirmed the presence of fentanyl in the blood, urine, liver and kidney. The fentanyl was not detected in the gastric content. The total ion chromatogram of the urine sample and mass spectrum of the fentanyl are shown in Figure 1.

Due to the lack of the calibrated reference standard, as well as the lack of time for ordering the standard, we obtained the ampule of fentanyl solution for parenteral use which we used as a calibration standard. Concentration of the active substance in pharmaceutical products is allowed to vary  $\pm 5\%$  of the declared concentration. Therefore, use of fentanyl solution as calibration standard leads to additional uncertainty. Since no internal standard and no calibrated reference standard were used, the precision level was lower and obtained concentrations are approximate but still acceptable for practical purposes.

The concentration of fentanyl in the femoral blood was barely detectible and there was no remaining blood sample for repetition by more sensitive method extraction procedure with internal standard. Therefore, we determined the limit of detection (LOD), precision and accuracy of the applied method. The internal standard was not used because the blood sample has been already analyzed without the addition of an internal standard. LOD of 2 ng/mL was achieved and it was approximately femoral blood fentanyl level.

### **Discussion**

Life threatening events and fatalities due to the transdermal fentanyl device can occur either due to the abuse (intentional inappropriate use), the misguided use (improper use for therapeutic purposes) or accidental use (unintentional contact of the non-user with the fentanyl patch).

Only one case of the abuse of the fentanyl patch among children has been reported – a 15-year-old girl attempted to commit a suicide by applying five fentanyl patches to the skin [8]. Much more often, life threatening events and deaths due the fentanyl patch among children pertain to the misguided use or to the accidental use. A great variety of the scenarios from these two categories have been reported [5-7, 9-11] which all share one characteristic – a lack of knowledge, information and attention among the adult users of the fentanyl patch. These include the accidental transfer of the patch from another person while hugging the child [5], placement of the patch on the child skin in order to relieve pain [6, 9], improper disposal of the used fentanyl patch which resulted in ingestion of the patch by the child in one case [10] and with self-application of the discarded patch to the skin by the child in another [7]. The inadvertent users of the fentanyl patches in these incidents were most often grandparents [5-7, 9]. The contact of the fentanyl patch and the child was either completely accidental [5, 7, 10] or the patch was applied to the child skin in order to relieve acute pain [6, 9].

In this presented case, the patch was placed on the child skin with intent, but not to relieve the pain. The fentanyl patch was used in order to stop bleeding, and it seems that the grandmother was not even aware of the purpose of the fentanyl patch.

The impact of applying fentanyl patch to the skin of opioid-naive child was amplified by the application of the patch over the bleeding abrasion. That increased the rate of absorption of fentanyl through the skin. The proper use of the fentanyl transdermal patch has been specified by the manufacturer, and FDA has so far issued three additional safety warnings pertaining to the need for proper use in order to avoid adverse events while using the patch [11-13]. The warning issued in 2007 stated the need to apply the patch over the skin that is intact [13]. Roy and Flynn have established that *stratum corneum* is the principle barrier for skin permeation and that permeability of the taped stripped skin without *stratum corneum* for fentanyl was 30 times higher [14]. Furthermore, Gupta et. al. have reported that the application of the transdermal fentanyl patch to the broken skin can increase blood fentanyl concentrations by 5 times [15]. A similar case [6] included a 6-year-old, 27-kg girl admitted to the hospital in the morning due to the altered mental status after her grandfather applied the Durogesic 25 µg/h transdermal patch over abrasion on her back the evening before. Fortunately, after the administration of naloxone, the patient was alert and talkative, and without the recurrence of the symptoms.

Respiratory depression usually develops at serum fentanyl concentrations of 2 ng/mL or more, but the severity depends upon the patients' age, pharmacokinetic response, ingestion of other sedative drugs, and depressed pulmonary function [16]. The concentration of the fentanyl in the femoral blood in our case was just above the level of detection (approximately 2 ng/mL). A recent study of Andresen et. al. concluded that the general guideline for interpretation of blood fentanyl concentration in a postmortem specimen concerning possible intoxication cannot be given due to wide concentration overlap in cases with fentanyl considered to be therapeutic and where is considered toxic [17]. This pertains even more to the cases involving small children, simply due to considerably small number of the observed cases.

Reported pharmacokinetics of fentanyl shows broad interpatient and inpatient variability [18]. In general, after single intravenous dose fentanyl tends to rapidly disappear from the blood [19]. This is due to the strong first-pass effect in the liver, with the majority of dose eliminated by the kidneys [19]. Furthermore, fentanyl exhibits wide tissue distribution with high extravascular volume of distribution [20]. In children, higher total body water leads to larger volume of distribution. In addition, clearance of fentanyl is greater than in adults leading to reduced elimination half-life [21]. Performed analysis in this case showed the

highest concentration of fentanyl in urine, followed by liver and kidney, while blood concentration was significantly lower (Table 1). Such pattern is consistent with other published data [10, 22, 23] and in accordance with expected behavior of the substance. Properly used transdermal fentanyl patch achieves controlled release of the substance over time. Specificity of the presented case includes application of the patch to damaged skin, thus allowing absorption rate which was substantially more rapid compared to the application on sound skin, in turn leading to earlier onset of elimination of the substance. Furthermore, the time interval from patch application to death of the child (between 7 and 12 hours) allowed clearance of the substance from blood and its accumulating in urine, thus producing the result observed by the toxicology analysis.

After the evaluation of the medical history of the child, the police investigation of the case, autopsy findings and toxicology results, we have concluded that fentanyl intoxication was the cause of death of the child. The number of children fatally intoxicated with fentanyl is, fortunately, small.

Low incidence of such events makes the body of knowledge on fentanyl pharmacokinetics in children incomplete. Therefore, we find this case to be a useful contribution to the evaluation of the level of postmortem concentrations of fentanyl in small child after the application of one Durogesic 25 µg/h patch where the fentanyl intoxication is considered the cause of death. Furthermore, we aim to emphasize the role of all participants in health-care systems in prevention of similar cases. The doctors prescribing transdermal fentanyl patch must provide the patients with thorough education on indications, risks and proper use, storage and disposal of this medicine since this is of crucial relevance in prevention of similar fatalities. Additionally, positive assessment of patient's mental capability to follow the instructions given should be an obligatory task for each attending physician prior to prescribing such medications. Besides the additional effort of physicians, we find that pharmaceutical companies should find the solution to additionally accent the potency and hazard of transdermal fentanyl patch through more explicit and prominent labeling on the covers as well as on each individual package of this medication.

Although fatal poisoning is uncommon among young children in well developed countries, it is of major interest to raise awareness of such events especially since great majority of these are preventable. This presented case illustrates the need for more thorough education of users and more strict rules in prescribing and handling of this potent medicine.

At the same time, the case serves as a reminder for all medicolegal experts, especially those who are burdened with a high case load, to remain alert to notice minute findings at autopsy,

since these can occasionally be the clue for case-solving. Herein, the band-aid placed over the simple skin abrasion turned out to be an explanation for sudden and unexpected death of a child.

### **ETHICAL STANDARDS**

The presented content completely complies with laws in the Croatia.

### **CONFLICTS OF INTEREST**

The authors declare that they have no conflicts of interest.

## REFERENCES

1. Anonymous (2011) Causes of death 2008 summary tables. Health statistics and informatics Department, World Health Organization, Geneva, Switzerland  
[http://www.google.com/url?sa=t&rct=j&q=&esrc=s&source=web&cd=3&ved=0CDAQFjAC&url=http%3A%2F%2Fwww.who.int%2Fgho%2Fmortality\\_burden\\_disease%2Fglobal\\_burden\\_disease\\_DTHMDG\\_2008.xls&ei=GorOVLnuBebOygPdvoGYCA&usg=AFQjCNF99dF9V77uAjjLyDbENLDpKBU3jQ&bvm=bv.85076809,d.bGQ](http://www.google.com/url?sa=t&rct=j&q=&esrc=s&source=web&cd=3&ved=0CDAQFjAC&url=http%3A%2F%2Fwww.who.int%2Fgho%2Fmortality_burden_disease%2Fglobal_burden_disease_DTHMDG_2008.xls&ei=GorOVLnuBebOygPdvoGYCA&usg=AFQjCNF99dF9V77uAjjLyDbENLDpKBU3jQ&bvm=bv.85076809,d.bGQ) Accessed 1 February 2015
2. Bronstein AC, Spyker DA, Cantilena LR Jr, Rumack BH, Dart RC (2012) 2011 Annual Report of the American Association of Poison Control Centers' National Poison Data System (NPDS): 29th Annual Report. *Clin Toxicol (Phila)*50(10):911-1164
3. Bond GR, Woodward RW, Ho M (2012) The growing impact of pediatric pharmaceutical poisoning. *J Pediatr* 160(2):265-270
4. Bronstein AC, Spyker DA, Cantilena LR, Green JL, Rumack BH, Dart RC (2011) 2010 Annual Report of the American Association of Poison Control Centers' National Poison Data System (NPDS): 28th Annual Report. *Clin Toxicol (Phila)* 49:910-941
5. Hardwick WE Jr, King WD, Palmison PA (1997) Respiratory depression in a child unintentionally exposed to transdermal fentanyl patch. *South Med J* 90:962-964
6. Meyer D, Tobias JD (2005) Adverse effects following the inadvertent administration of opioids to infants and children. *Clin Pediatr (Phila)* 44(6):499-503
7. Foy L, Seeyave DM, Bradin SA (2011) Toxic Leukoencephalopathy Due to Transdermal Fentanyl Overdose. *Pediatr Emer Care* 27:854-856
8. Lyttle MD, Verma S, Isaac R (2012) Transdermal Fentanyl in Deliberate Overdose in Pediatrics. *Pediatr Emer Care* 28:436-464

9. Watson WA, Litovitz TL, Rodgers GC Jr, Klein-Schwartz W, Youniss J, Rose SR, Borys D, May ME (2003) 2002 Annual Report of the American Association of Poison Control Centers Toxic Exposure Surveillance System. *Am J Emerg Med* 21(5):353-421
10. Teske J, Weller JP, Larsch K, Troger HD, Karst M (2007) Fatal outcome in a child after ingestion of a transdermal fentanyl patch. *Int J Legal Med* 121:147-151
11. Anonymous (2012) Fentanyl Patch Can Be Deadly to Children. Consumer health information Food and Drug Administration  
<http://www.fda.gov/ForConsumers/ConsumerUpdates/ucm300803.htm> Accessed 30 January 2015
12. Anonymous (2005) FDA Issues Public Health Advisory on the Fentanyl Patch. Consumer health information Food and Drug Administration  
<http://www.fda.gov/NewsEvents/Newsroom/PressAnnouncements/2005/ucm108461.htm>  
Accessed 30 January 2015
13. Anonymous (2007) Second Safety Warning on Fentanyl Skin Patch. Consumer health information Food and Drug Administration  
<http://www.fda.gov/ForConsumers/ConsumerUpdates/ucm100223.htm> Accessed 30 January 2015
14. Roy SD, Flynn GL (1990) Transdermal delivery of narcotic analgesics: pH, anatomical and subject influences on cutaneous permeability of fentanyl and sufentanil. *Pharm Res* 7:842–847
15. Gupta SK, Southam M, Gale R, Hwang SS (1992) System functionality and physiochemical model of fentanyl transdermal system. *J Pain Symptom Manage* 7:S17–S26
16. Peng PW, Sandler AN (1999) A review of the use of fentanyl analgesia in the management of acute pain in adults. *Anesthesiology* 90:576-599

17. Andresen H, Gullans A, Veselinovic M, Anders S, Schmoldt A, Iwersen-Bergmann S, Mueller A (2012) Fentanyl: toxic or therapeutic? Postmortem and antemortem blood concentrations after transdermal fentanyl application. *J Anal Toxicol* 36(3):182-194
18. Grond S, Radbruch L, Lehmann KA (2000) Clinical pharmacokinetics of transdermal opioids: focus on transdermal fentanyl. *Clin Pharmacokinet* 38:59-89
19. McClain DA, Hug CC (1980) Intravenous fentanyl kinetics. *Clin Pharmacol Ther* 128:106-114
20. Mather LE, Gourlay GK (1991) Pharmacokinetics of Fentanyl. In: Lehmann KA, Zech D (eds) *Transdermal Fentanyl: A New Approach to Prolonged Pain Control*. Springer, Berlin Heidelberg, pp 73-97
21. Anderson B, Lerman J, Cote CJ (2013) Pharmacokinetics and Pharmacology of Drugs Used in Children. In: Cote CJ, Lerman J, Anderson B (eds) *A Practice of Anesthesia for Infants and Children*, 5th edn. Elsevier Saunders, Philadelphia pp 77-150
22. Kuhlman JJ, McCaulley R, Valouch TJ, Behonick GS (2003) Fentanyl use, misuse, and abuse: a summary of 23 postmortem cases. *J Anal Toxicol* 27:499-504
23. Martin TL, Woodall KL, McLellan BA (2006) Fentanyl-related deaths in Ontario, Canada: toxicological findings and circumstances of death in 112 cases (2002-2004) *J Anal Toxicol* 30:603-610