

Solitary pulmonary amyloidoma mimicking lung cancer on 18F-FDG PET-CT scan in systemic lupus erythematosus patient

Barešić, Marko; Sreter, Katherina Bernadette; Brčić, Luka; Hećimović, Ana; Janevski, Zoran; Anić, Branimir

Source / Izvornik: **Lupus, 2015, 24, 1546 - 1551**

Journal article, Accepted version

Rad u časopisu, Završna verzija rukopisa prihvaćena za objavljivanje (postprint)

<https://doi.org/10.1177/0961203315591025>

Permanent link / Trajna poveznica: <https://um.nsk.hr/um:nbn:hr:105:951781>

Rights / Prava: [In copyright](#)/[Zaštićeno autorskim pravom.](#)

Download date / Datum preuzimanja: **2024-08-11**



Repository / Repozitorij:

[Dr Med - University of Zagreb School of Medicine Digital Repository](#)





Središnja medicinska knjižnica

Barešić M., Sreter K. B., Brčić L., Hećimović A., Janevski Z., Anić B.
(2015) *Solitary pulmonary amyloidoma mimicking lung cancer on*
¹⁸F-FDG PET-CT scan in systemic lupus erythematosus patient.* *Lupus,
24 (14). pp. 1546-51. ISSN 0961-2033

<http://journals.sagepub.com/home/lup>

<http://dx.doi.org/10.1177/0961203315591025>

<http://medlib.mef.hr/2721>

University of Zagreb Medical School Repository

<http://medlib.mef.hr/>

TITLE:

SOLITARY PULMONARY AMYLOIDOMA MIMICKING LUNG CANCER ON ¹⁸F-FDG PET-CT SCAN IN SYSTEMIC LUPUS ERYTHEMATOSUS PATIENT

AUTHORS:

Marko Barešić, MD¹,

Katherina Bernadette Sreter, MD²,

Luka Brčić, MD, PhD³,

Ana Hećimović, MD⁴,

Zoran Janevski, MD⁵,

Branimir Anić, MD, PhD¹

AUTHOR AFFILIATIONS:

¹ Division of Clinical Immunology and Rheumatology, Department of Internal Medicine, University of Zagreb, School of Medicine, University Hospital Center Zagreb, Kišpatičeva 12, 10000 Zagreb, Croatia

² Department of Clinical Immunology, Pulmonology, and Rheumatology, University Hospital Centre "Sestre Milosrdnice", Vinogradska cesta 17, 10000 Zagreb

³ Department of Pathology, University of Zagreb, School of Medicine, University Hospital Center Zagreb, Kišpatičeva 12, 10000 Zagreb, Croatia

⁴ Department of Interstitial Diseases, Clinic for Respiratory Diseases "Jordanovac", University of Zagreb, School of Medicine, University Hospital Center Zagreb, Jordanovac 104, 10000 Zagreb, Croatia

⁵ Department of Thoracic Surgery, Clinic for Respiratory Diseases "Jordanovac", University of Zagreb, School of Medicine, University Hospital Center Zagreb, Jordanovac 104, 10000 Zagreb, Croatia

Corresponding Author:

Marko Barešić, MD

Division of Clinical Immunology and Rheumatology, Department of Internal Medicine, University of Zagreb, School of Medicine, University Hospital Center Zagreb, Kišpatičeva 12, 10000 Zagreb, Croatia

E-mail: markobaresic@gmail.com

ABSTRACT:

Localized amyloid deposits (tumoral amyloidosis or amyloidoma) are uncommon form of amyloidosis and nodular pulmonary amyloidomas are rarely found. This incidental finding can mimic a bronchopulmonary neoplasm and may occur secondarily to an infectious, inflammatory or lymphoproliferative disease. We report a case of a 62-year-old female with long-standing systemic lupus erythematosus (SLE) with low compliance who presented with radiologically-verified solitary pulmonary nodule. Work-up included positron emission tomography-computed tomography (PET-CT) scan which revealed hypermetabolic uptake of F-18 fluorodeoxyglucose (FDG) and lobectomy was performed. Staining of the tissue was positive for Congo red and was green birefringent under polarized light. Immunohistochemical methods excluded lymphoproliferative disease and confirmed amyloidoma. SLE was controlled with antimalarials and glucocorticoids. Pulmonary amyloidoma should be considered in the differential diagnosis of solitary lung nodules.

KEY WORDS:

Amyloidoma; Solitary lung nodule; Lung cancer; PET-CT imaging; Systemic Lupus Erythematosus.

INTRODUCTION:

Amyloid is an insoluble form of protein that can be deposited in almost every solid organ including the kidneys, heart, and liver. Solitary localized tumour-like amyloid deposits or amyloidomas, without systemic amyloidosis are uncommon (1).

Pulmonary amyloidomas (PA) may manifest in several forms: tracheobronchial, nodular (most common) or diffuse parenchymal and alveolar septal. Nodular parenchymal amyloidosis radiographically presents as a single or multiple peripheral pulmonary nodules that may be of various sizes and margin contours (2). Nodules are usually found subpleurally, in the lower lobes, and may be bilateral. Cavities are seen in up to 20% of cases and calcification in 20-50% on CT scans (3). PA may grow very slowly over years and the long-term prognosis is typically favourable. Patients are often elderly and asymptomatic, although symptomatology is related to the location and size of the lesion(s). PA is therefore frequently discovered incidentally on routine chest x-rays (2,3). Due to the rarity of amyloidomas and the scarcity of controlled clinical trials, management decisions are regularly made on an individual empirical basis (1). In most cases involving nodules that do not produce space-occupying effects, no intervention is required except for “watchful waiting” and regular follow-ups. Local recurrence rates following surgical control of PA are reported to be negligible.

The cause of nodular PA is still unknown. It is hypothesized to result due to a reaction to chronic inflammatory conditions affecting the lung, such as connective tissue disorders, tuberculosis, or HIV infection (1). Amyloidomas have also been associated with systemic lymphoproliferative disorders and plasma cell dyscrasias, primarily multiple myeloma, and lymphoplasmacytic lymphoma (4). It is therefore imperative that appropriate diagnostic testing is carried out to exclude these conditions. The gold standard for diagnosis of PA is pathohistological verification of tissue biopsy (1,2,4). Nodular PAs histologically appear as well-circumscribed consolidated masses of dense, amorphous eosinophilic material, frequently associated with inflammatory infiltrates of plasma cells, lymphocytes, and histiocytes, and may include a granulomatous reaction of giant multinucleated cells surrounding the amyloid deposits (4). Congo red staining gives a definitive diagnosis as the appearance of green birefringence under polarized light is a pathognomonic feature of amyloid (1).

CASE REPORT:

We report a case of a 62-year-old female attorney with a history of cervical conization (due to HPV infection) and a tonsillectomy at 42 years of age. She gave birth to a healthy son and had no history of miscarriage. The patient did not consume any tobacco, alcohol or illicit drugs. Her family history was positive for autoimmune disease (a grandmother with rheumatoid arthritis who also had pulmonary tuberculosis), and malignancy (brother had Hodgkin's lymphoma).

The patient was diagnosed in 1980 with systemic lupus erythematosus - SLE (leucopaenia, lymphopaenia, positive ANA and dsDNA, arthritis, oral aphthae) with no major organ involvement (no signs of lupus nephritis and no neuropsychiatric systemic lupus erythematosus). She was prescribed oral glucocorticoids and azathioprine and was subsequently followed by a rheumatologist over the next several years. The patient had a low adherence and low compliance to treatment and often missed recommended visits. She independently stopped taking the prescribed medications approximately 30 years ago for fear of known side-effects and opted for alternative treatments.

Her initial respiratory complaints began with symptoms of lower respiratory tract infection including febrile illness (maximum axillary body temperature of 40°C), a productive cough with thick green sputum, headache, and general malaise. Chest x-ray (**Figure 1**) revealed a heterogeneous dense opacity of the right supradiaphragmatic region highly suggestive of right lower lobe pneumonia. After the course of oral antibiotics (moxifloxacin), her cough remitted but febrile illness persisted. Follow-up chest x-ray was unchanged and the patient was given an additional course of amoxicillin-clavulanic acid combination and azithromycin. She remained febrile with new symptoms of pain and stiffness in the large joints diffusely without any visible signs of joint inflammation.

The patient was admitted to the Infectology Unit where she underwent complete laboratory and diagnostic assessment (elevated acute phase reactants, ESR being unproportionally higher than CRP). Transthoracic cardiac ultrasound excluded endocarditis, but a mild mitral and tricuspid regurgitation was noted. Ultrasound of the abdomen was unremarkable. Spirometry results were within normal limits; however, carbon monoxide diffusion capacity was somewhat decreased (74.4%). CT scan of the thorax raised suspicion of an early lung cancer given that a solitary nodule (1.5 cm in diameter) with slightly spiculated margins and microcalcifications, appearing sclerotic, was observed in the right supradiaphragmatic region at the border of the latero- and postero-basal segments of the right lower lobe in close association with the bronchovascular bundle. The appearance of the nodular formation seemed to indicate an older scarring-type lesion and below it were tracks of scarred tissue.

Further work-up was continued at the Pulmonology Unit where on two separate occasions, fiberbronchoscopy was performed. Cytologic results of bronchoscopic samples revealed inflammatory elements as well as several groups of uniform cells suspected to be carcinomatous. Microbiologic results of bronchoscopic and sputum samples tested negative for tuberculosis infection (direct smear and later on the culture). Given these findings, PET-CT scan with ¹⁸F-FDG uptake was recommended to rule out lung carcinoma although the tumour markers CYFRA 21-1 and NSE were negative.

PET revealed pathological utilization of the glucose analog (SUV max 5.25) corresponding to the pulmonary lesion (2.2 x 2 cm) on CT imaging that was consistent with metabolically active tissue with morphological characteristics of a possible neoplastic process (**Figure 2**).

There were no signs of lymphadenopathy, clinically and radiographically.

Due to suspected lung carcinoma, thoracotomy with tumour resection with diagnostic and therapeutic intent was performed. Intraoperative tumour biopsy revealed extensive necrosis, erythrocytes, lymphocytes, few plasma cells, multinucleated giant cells, poorly ordered groups of cubic epithelial cells with atypia, and some elastic tissue. Given these inconclusive findings for possible tumour cells, right lower lobectomy (16x11.5x8 cm) with resection of bronchopulmonary (1 cm diameter) and mediastinal (2 cm diameter) lymph nodes was performed. Postoperative histological findings of the lobectomized lung tissue were unremarkable; that of the lymph nodes showed reactive changes predominantly of the sinus histiocytosis type and was determined to be reactive lymphadenitis. The resected tumour-like mass (2.5 cm diameter) had sharply defined borders that macroscopically extended to the pleura. Histologically, the nodule was composed of large deposits of thick, amorphous eosinophilic material, partly surrounded by multinucleated giant cells of foreign body type, and partly by granulation tissue or fibroblastic stroma. The eosinophilic material stained positively for Congo red and was green birefringent under polarized light which is characteristic of AA amyloid. Deposits of AA amyloid were also found around the bronchus in the area of resected margin (**Figure 3**). Additional immunohistochemical staining methods (CD3, CD20, CD31, kappa and lambda light chains) excluded lymphoproliferative diseases. The diagnosis of systemic amyloidosis was ruled out after analyzing abdominal subcutaneous fat. The fat sample did not bind Congo red and there was no green birefringence under polarized light.

The patient's postoperative course involved a slow general recovery and normal healing of the wound. She continued to have low grade fever without any effect of the given antibiotics. Repeated bronchoscopy and analysis did not produce a pathological substrate.

Because her past history of systemic autoimmune disease the possibility of the relaps of SLE was suspected. She was referred to the Rheumatology unit where she presented with low

grade fever, fatigue and general malaise, pain in the hips and spine, as well as worsening of joint stiffness. There were no mucocutaneous or ophthalmological changes. A comprehensive reevaluation was undertaken. The tests came back positive for active SLE (lymphopaenia, high titer of ANA and dsDNA) with polyclonal hypergammaglobulinaemia without involvement of the kidneys and central nervous systems and without elements for antiphospholipid syndrome. The patient was started on an oral corticosteroid (0.5 mg/kg methylprednisolone) with gradual tapering and began antimalarial therapy (chloroquine phosphate) with prompt improvement of her general condition.

At the follow-up period (20 months post-op) the patient was in a good overall state of health. There were no major complaints with respect to respiratory functioning except for a dry irritating cough on occasion. Cardiac ultrasound showed a good ejection fraction (65%) with mild mitral regurgitation and mild to moderate diastolic dysfunction without signs of pulmonary hypertension. Her last chest x-ray was stationary and no fresh pleurobronchopulmonary lesions, lymphadenopathy or skeletal changes were noted. She remained on a minimal maintenance dose of methylprednisolone (4 mg) and antimalarial drug (chloroquine 250 mg) for SLE without any signs of local or systemic recurrence of amyloidosis.

DISCUSSION:

SLE is thought to be a T helper type 2 (Th2) driven disease, making cytokines IL-4, IL-5, and IL-10 and their association with humoral immune response and antibody production very important part of the pathogenesis of the disease. T helper type 1 (Th1) and T helper 17 (Th17) cells also play an important role in the SLE. Acute phase reactants ESR and CRP are elevated via different set of cytokines from Th1 and Th2 response. Active SLE should predominantly be driven by Th2 response and have accelerated ESR and low CRP unless there is a parallel infection or serositis occurring.

In our case initial laboratory findings at Infectology unit included ESR of 86 mm/h (normal value <24 mm/h) and CRP of 21.7 mg/l (normal value <5 mg/l) and during the patients stay at the Pulmonology unit ESR was 72 mm/h and CRP 6.7 mg/l. Disproportionality of ESR and CRP raised the suspicion of something other than infection which was confirmed to be an active SLE. As a result of an infection serum amyloid A (SAA) acts similar to CRP.

Although pulmonary manifestations of SLE are common, pulmonary amyloidosis is extremely rare (5). Accumulation of amyloid is more likely to be registered in untreated and undertreated patients. The described patient's non-compliance and low adherence was seen in irregular follow-up visits and periods of not taking any SLE drugs, leaving the disease untreated. This led to the episodes of active systemic inflammation which probably contributed to the formation of the amyloid. The potential mechanisms include long-lasting periods of active inflammation and activation of different cell types, predominantly B-cells. Although AA amyloid is rare in SLE and more common in Familial Mediterranean fever (FMF) and rheumatoid arthritis such cases have been described in medical literature (6). The formation of amyloid in our case is more likely related to the periods of untreated SLE caused by the low compliance of the patient and not merely a coincidence. There was no definitive evidence the cellular infiltrate in the lung nodule (amyloid) could point to a local cause of inflammation and local SAA production.

The case described also brought up the suspicion of the malignancy. In general, patients with SLE have increased risk of different malignancies, non-Hodgkin's lymphoma (diffuse large B cell) being the most common (with standardized incidence ratio of 3.64) (7).

Dysregulation of lymphocyte proliferation which is characteristic for SLE and some chromosomal abnormalities (translocations) may be the mechanism responsible for the development of lymphoma. It is uncertain whether the activity of the SLE or SLE immunosuppressive medications lead to the risk of the development of lymphoma (7).

Similar cases of unknown focal lesions should prompt us to perform additional tests to distinguish benign and malignant etiology of the lesions. The most important clinical implication after reaching the final diagnosis (amyloid vrs. tumour) is the planning of different

treatment options on an individual basis bearing in mind each patient's individual course of disease.

Positron emission tomography (PET) using ^{18}F - fluorodeoxyglucose (FDG) is a widely used diagnostic and staging modality to evaluate solitary pulmonary nodules suspected of being malignant. PET-CT imaging may therefore reduce inappropriate invasive diagnostic investigation and subsequent complications (8).

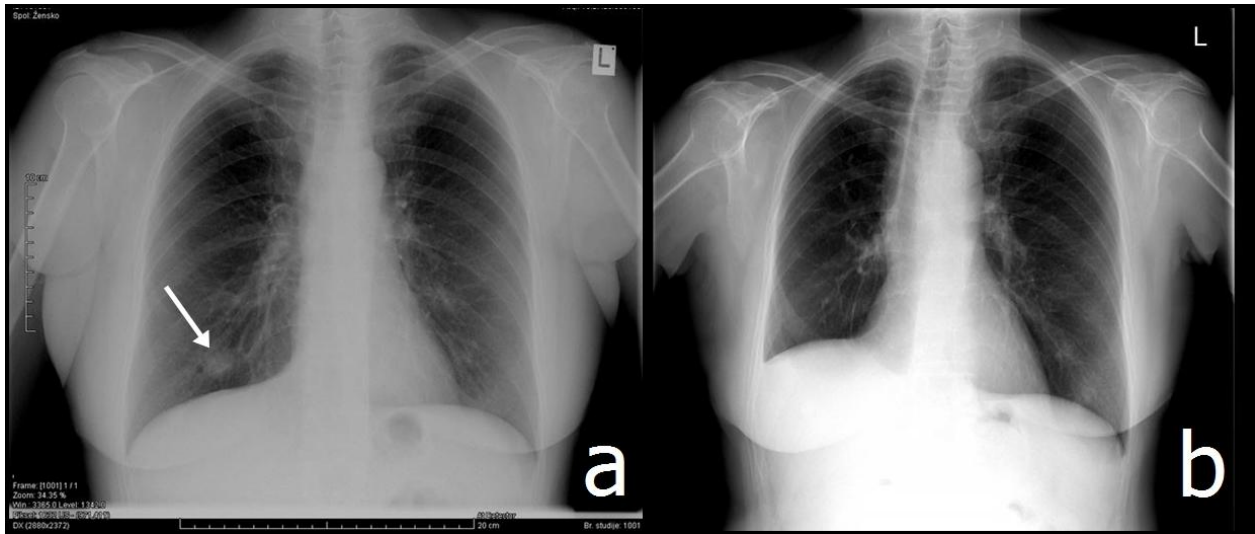
Increased FDG activity has also been described in benign pulmonary nodules. Such false-positive FDG results have been demonstrated in cases of active granulomatous disease (tuberculosis, fungal infections such as histoplasmosis and aspergillosis, and sarcoidosis), and inflammatory processes in the lungs (rheumatoid nodules and interstitial lung disease) and elsewhere (osteoarthritis, vascular thromboses, and osteoporosis) (9). The reason for uptake of ^{18}F -FDG in noncancerous conditions is unclear, but what is evident is that FDG is not tumour specific. It is hypothesized that benign lesions containing elevated concentrations of inflammatory cells (i.e., neutrophils and activated macrophages) have higher metabolic rates and therefore, greater glucose uptake (10).

Metser *et al.* conducted a retrospective review of 1134 consecutive reports of PET-CT studies in proven or suspected malignancy of various organs and found benign FDG uptake in over 25% of the PET-CT studies, with 28.2% of noncancerous lesions having moderate to marked FDG uptake. The most common cause for FDG avidity in benign lesions was inflammation (73.3%), both infectious and noninfectious, thus confirming the findings of multiple previous reports on FDG uptake in such lesions. A plausible explanation for the increased uptake of FDG in inflammatory processes is that activated leucocytes (granulocytes, lymphocytes, and macrophages) have enhanced levels of glucose transporters and an increased affinity to deoxyglucose through various cytokines and growth factors (10). The exact cause for FDG avidity in PA has not yet been fully elucidated. It is plausible that an inflammatory reaction by the amyloid lesion itself (i.e., presence of histiocytic infiltration) leads to increased FDG uptake.

In conclusion, solitary PA secondary to systemic lupus erythematosus is exceptionally rare. The differential diagnosis of a radiologically observed nodule in the lower respiratory tract should include benign lesion such as amyloidoma in addition to malignancy such as bronchopulmonary carcinoma. ^{18}F -FDG PET-CT scan is a helpful diagnostic tool to characterize indeterminate pulmonary nodules but its specificity is limited, resulting in false positives, such as in our patient. Plasma cell dyscrasias are commonly associated with amyloidosis and must be ruled out in each instance. Surgical resection as a means of local control may be indicated, as was the case here. Long-term follow-up is recommended due to possible development of systemic disease and/or local recurrence. However, the prognosis is favourable and recurrence rates are low. This case highlights the importance of

histological evaluation of tissue biopsy to confirm the diagnosis of suspected malignancy in ^{18}F -FDG avid lesions on PET-CT. The management and treatment of solitary pulmonary nodule, therefore, necessitates a personalized approach based on all relevant diagnostic results. Further studies to determine the etiology of PA in SLE patients and the mechanism of false positive ^{18}F -FDG uptake in PA on PET-CT scan are warranted.

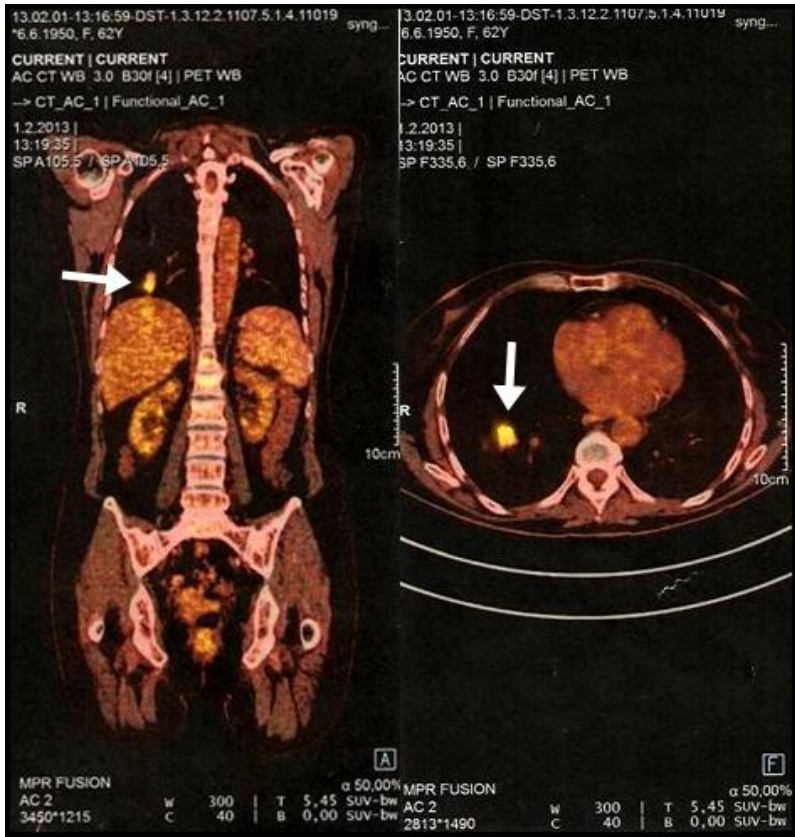
FIGURE 1:



Chest x-ray:

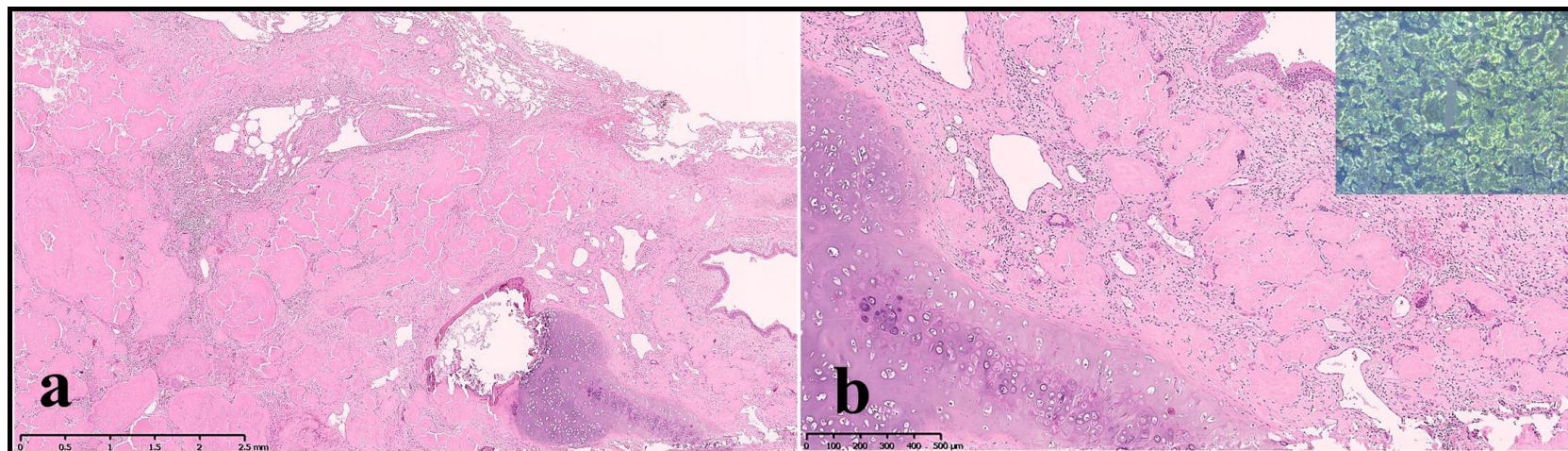
- a - a solitary pulmonary nodule (arrow) in the right lower lung lobe prior to tumour resection and
- b - follow-up radiograph post-surgery.

FIGURE 2:



F-18 FDG PET-CT scan with SUV max of 5.25 in the solitary pulmonary nodule indicating a hypermetabolic lesion highly suspicious of a pulmonary malignancy

FIGURE 3:



a - Lung parenchyma with sharply demarcated amyloid deposits and scant lymphoplasmacytic infiltrate mostly at the periphery of deposits. On the right side, bronchial wall is seen with amyloid deposits between surface epithelium and bronchial cartilage with metaplastic ossification. (Hematoxylin-eosin stain, objective x 1,67).

b - Amyloid deposits within the airway wall with occasional foreign body giant cells and mild infiltration of chronic inflammatory cells. Inlet demonstrates characteristic apple-green birefringence of Congo red-stained amyloid under polarized light. (Hematoxylin-eosin, objective x5, inlet Congo red under polarized light, objective x 2,5).

Funding:

This research received no specific grant from any funding agency in the public, commercial, or not-for-profit sectors.

Conflict of interest:

The authors have no conflicts of interest to declare.

REFERENCES:

1. Palladini G, Merlini G. Systemic amyloidoses: what an internist should know. *Eur J Intern Med* 2013; 24(8): 729-39.
2. Hagemeyer L, Stieglitz S, Röcken C, Randerath W. [Amyloidosis in pneumology]. [Article in German]. *Pneumologie* 2012; 66(8): 483-92.
3. Desai RA, Mahajan VK, Benjamin S, Van Ordstrand HS, Cordasco EM. Pulmonary amyloidoma and hilar adenopathy. Rare manifestations of primary amyloidosis. *Chest* 1979; 76(2): 170-3.
4. Dacic S, Colby TV, Yousem SA. Nodular amyloidoma and primary pulmonary lymphoma with amyloid production: a differential diagnostic problem. *Mod Pathol* 2000; 13(9): 934-40.
5. Westlake S, Edwards CJ. Pulmonary nodular amyloidosis and systemic lupus erythematosus. *Lupus* 2005; 14(8): 639-40.
6. Ridley MG, Maddison PJ, Tribe CR. Amyloidosis and systemic lupus erythematosus. *Ann Rheum Dis*. 1984; 43(4): 649-50.
7. Bernatsky S, Kale M, Ramsey-Goldman R, Gordon C, Clarke AE. Systemic lupus and malignancies. *Curr Opin Rheumatol*. 2012; 24(2): 177-81.
8. Khan AM, Manzoor K, Jain V, Mahadevia P, Berman A. Detection of nodular pulmonary amyloid by PET positive scan--deception for lung cancer. *Rev Port Pneumol* 2012; 18(6): 299-303.
9. Zhang LN, Xue XY, Wang N, Wang JX. Mimicking pulmonary multiple metastatic tumors: A case of primary nodular parenchymal pulmonary amyloidosis with review of the literature. *Oncol Lett* 2012; 4(6): 1366-1370.
10. Metser U, Miller E, Lerman H, Even-Sapir E. Benign nonphysiologic lesions with increased 18F-FDG uptake on PET/CT: characterization and incidence. *AJR Am J Roentgenol* 2007;189(5): 1203-10.