

Medical thermography (digital infrared thermal imaging - DITI) in paediatric forearm fractures - a pilot study

Ćurković, Selena; Antabak, Anko; Halužan, Damir; Luetić, Tomislav; Prić, Ivica; Šiško, Jerko

Source / Izvornik: *Injury*, 2015, 46, S36 - S39

Journal article, Accepted version

Rad u časopisu, Završna verzija rukopisa prihvaćena za objavljivanje (postprint)

<https://doi.org/10.1016/j.injury.2015.10.044>

Permanent link / Trajna poveznica: <https://um.nsk.hr/um:nbn:hr:105:139222>

Rights / Prava: [In copyright](#)/[Zaštićeno autorskim pravom](#).

Download date / Datum preuzimanja: **2024-11-06**



Repository / Repozitorij:

[Dr Med - University of Zagreb School of Medicine Digital Repository](#)





Središnja medicinska knjižnica

Ćurković S., Antabak A., Halužan D., Luetić T., Prlić I., Šiško J. (2015)
Medical thermography (digital infrared thermal imaging - DITI) in
paediatric forearm fractures - A pilot study. Injury, 46 (Suppl. 6). pp.
S36-9. ISSN 0020-1383

<http://www.elsevier.com/locate/issn/00201383>

<http://www.sciencedirect.com/science/journal/00201383>

<http://dx.doi.org/10.1016/j.injury.2015.10.044>

<http://medlib.mef.hr/2732>

University of Zagreb Medical School Repository

<http://medlib.mef.hr/>

Medical thermography (Digital Infrared Thermal Imaging- DITI) in pediatric forearm fractures- pilot study

Ćurković S¹, Antabak A², Halužan D², Luetić T², Prlić I³, Šiško J³

1. General Hospital Karlovac, Karlovac, Croatia

2. Department of Surgery, University hospital center Zagreb, Zagreb, Croatia

3. Institute for Medical Research and Occupational Health, Zagreb, Croatia

Corresponding author:

Selena Ćurković ,M.D., pediatric surgeon

General hospital Karlovac

Department of surgery

Andrije Stampara 3, 47000 Karlovac, CROATIA

selenacurkovic@gmail.com

Keywords: medical thermography, DITI, forearm fractures, pediatric trauma

Abstract

Pediatric trauma is most common case of hospitalization in pediatric population, and forearm fractures make 35% of all pediatric fractures. One third of them are distal forearm fractures which represent one of the most common fractures in pediatric population. This type of fracture represent everyday problem for every pediatric surgeon. It is to presume that three phases of fracture healing in pediatric trauma is followed by skin temperature changes and that it can be measured and compared with standard plain radiography visible callus formation and eventually used in everyday practice. Thermographic assessment of temperature distribution within the examined tissues allows a quick, noncontact, noninvasive measurement of their temperature. Medical thermography is used as screening method in other parts of medicine, but thermography use in traumatology is still not researched.

Introduction

Pediatric trauma is most common case of hospitalization in pediatric trauma, and forearm fractures make 35% of all pediatric fractures. The incidence of fractures increases with age with falls from below bed height (<1m) being the commonest cause of fracture. The majority of fractures in children involve the upper limb^{1,2}. One third of them is distal forearm fractures and as one is most common fracture in pediatric population and for every pediatric surgeon this type of injury is everyday problem. Most of them are treated nonsurgical with proper casting, and therefore need regular radiographic scans for follow up of fracture healing.

Today, in pediatric traumatology it is state of the art to make planed x-ray fracture follow up, and as surgeon visualize proper callus formation on x-ray scans, removes casting and advices patient and parents³.

It is well known that fractures heal in three phases, first inflammatory, second reparative and third remodeling phase. First two phases are specific for microvascular invasion, which occurs very quickly in children because the state of vascularity. Higher blood flow consequently rises local temperature in and around fracture site. In third, remodeling phase, much vascularized fibrous callus is remodeled into bony bridge⁴, so we can assume that local temperature is decreasing. Medical thermography (Digital Infrared Thermal Imaging- DITI) is a noninvasive diagnostic technique that allows the examiner to visualize and quantify changes in skin surface temperature⁵. An infrared scanning device is used to convert infrared radiation emitted from the skin surface into electrical impulses that are visualized in color on a monitor. This visual image graphically maps the body temperature and is referred to as a thermogram. The spectrums of colors indicate an increase or decrease in the amount of infrared radiation being emitted from the body surface. Since there is a high degree of thermal symmetry in the normal body, subtle abnormal temperature asymmetry's can be easily identified^{6,7}.

Skin blood flow is under the control of the sympathetic nervous system. In healthy people there is a symmetrical dermal pattern which is consistent and reproducible for any individual. This is recorded in precise detail with a temperature sensitivity of 0.1°C by DITI⁸.

With this study we want to measure difference, dynamics and duration of temperature changes during fracture healing. Until now, in recent literature there is no such study. We

would like to research value of medical thermography in clinical follow up of pediatric fracture healing as one noninvasive and harmful diagnostic method.⁹

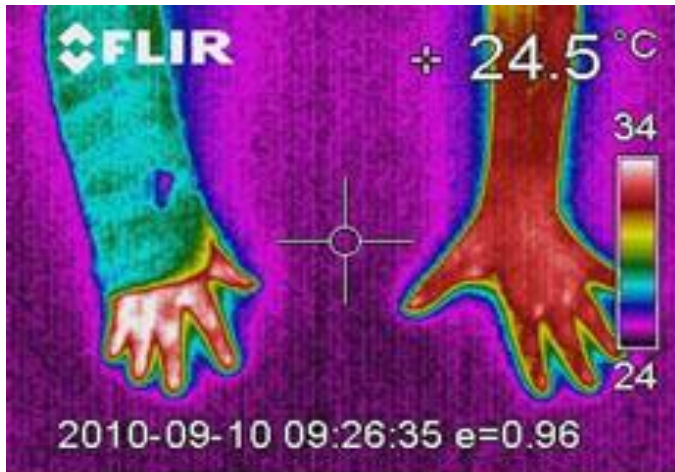
Materials and methods

This research has assessed consent of ethical committee of Medical school Zagreb, University of Zagreb and University hospital center Zagreb, Croatia. All parents of children included in this study signed informed consent¹⁰.

We have decided to do this prospective pilot study on children from 4-14 years of age who came to emergency ambulance of University hospital center Zagreb, were diagnosed with forearm fractures and had their injury treated nonsurgical. Patients with green stick, Buckle fractures and growth plate fractures, or those who already had their forearm fracture in last two years were excluded from this pilot study. All children in the study were healthy, excluding fracture, and were appointed for first control one week after initial injury. For thermographic measurements thermographic camera Flir ThermaCam B2 (FLIR Systems, Inc., Oregon, USA) was used. This infrared system has a 320 x 240 pixels image presentation and thermal sensitivity of $< 0.10^{\circ}\text{C}$ at 25°C . This camera produces graphical maps (thermograms) and results were analyzed by Flir ThermaCam QuickView 2.0 and Flir QuickReport 1.2 software. Indoor room temperature was measured and controlled by ETHG 880 thermo-hydrometer (IDT International, San Jose, CA, USA)

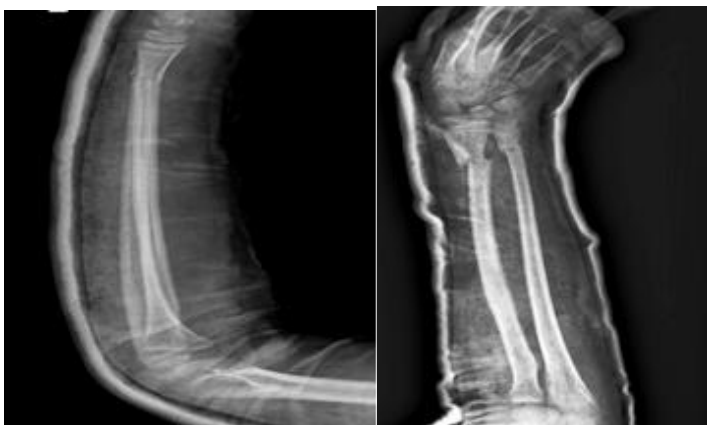
Before measurement patient have spent 30 minutes in acclimatized room with indoor temperature form $22-24^{\circ}\text{C}$, and thermographs were made in another room with same indoor temperature. Patients have putted both forearms on Styrofoam board, thermographic camera was 100 cm from both forearms, and in alignment with the board (Picture 1).

Picture 1. Thermogram made by thermographic camera



Thermographic measurement was planned and done 7/14/21 day after injury and on 28 the day only in those patients who still had temperature discrepancy on after 21nd day. Temperature was measured on both arms, fractured and healthy, and compared. During our thermographic study, regular radiographic scans, as it is usual in pediatric fracture measurement, were made on same days as measurement of temperature (Picture 2).

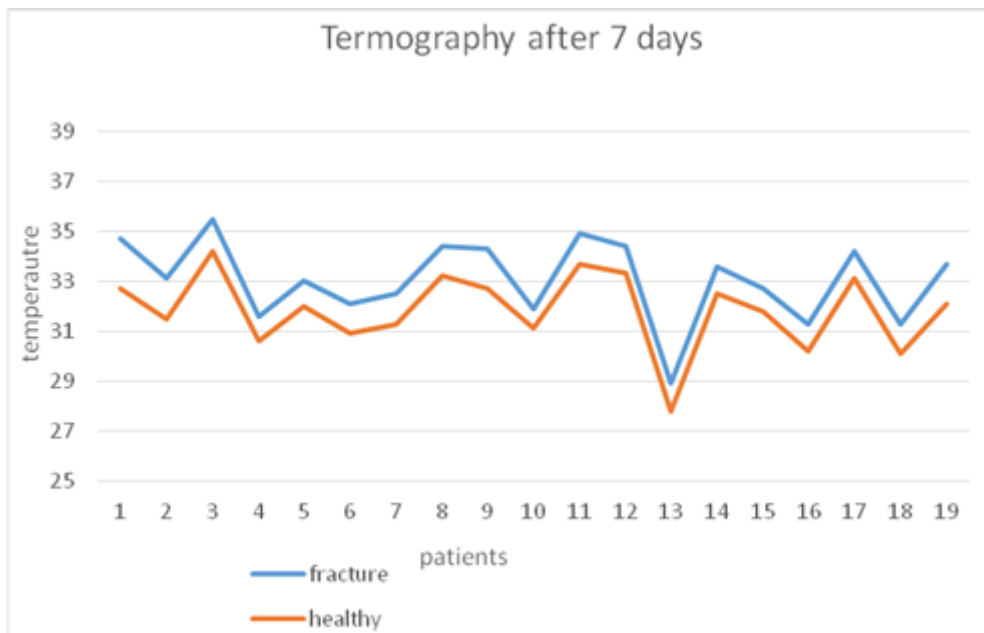
Picture 2. Plain radiographic scan of same forearm as on picture 1.



Results

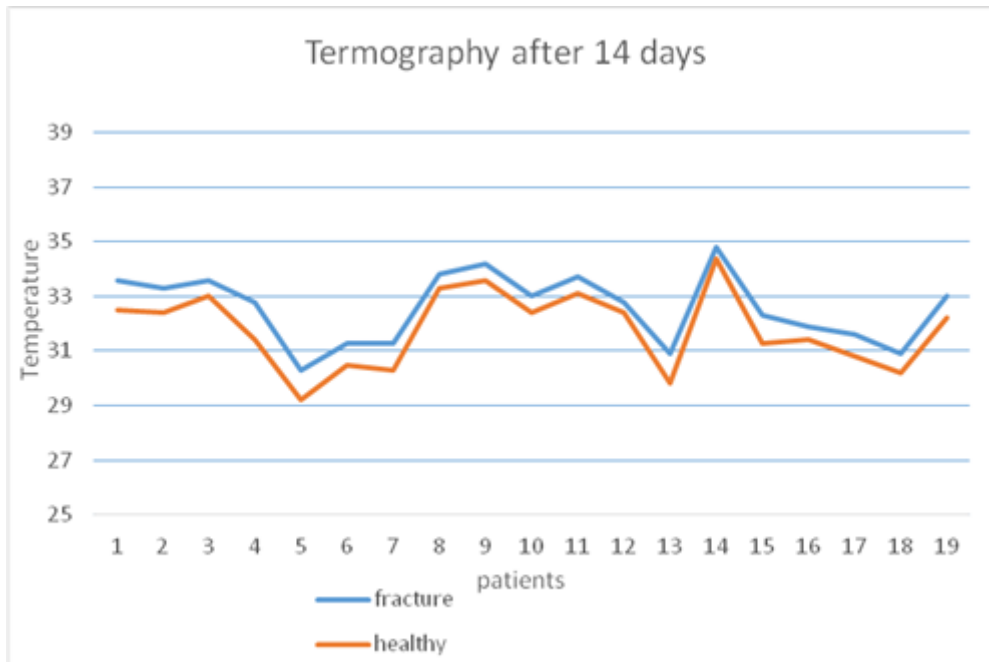
In our pilot study, we had 19 patients, from 4 to 14 years of age, in average $9,05 \pm 3,13$ years of age. After evaluating thermograms we made charts which show that in all patients temperature on fractured side, measured 7 days after injury, was higher. Difference in temperature between forearms varied from $0,8^{\circ}\text{C}$ till 2°C . Highest temperature measured on fracture side was $35,5^{\circ}\text{C}$, and lowest was $28,9^{\circ}\text{C}$ (Chart 1.).

Chart 1. Temperature measurements on both forearms after 7 days



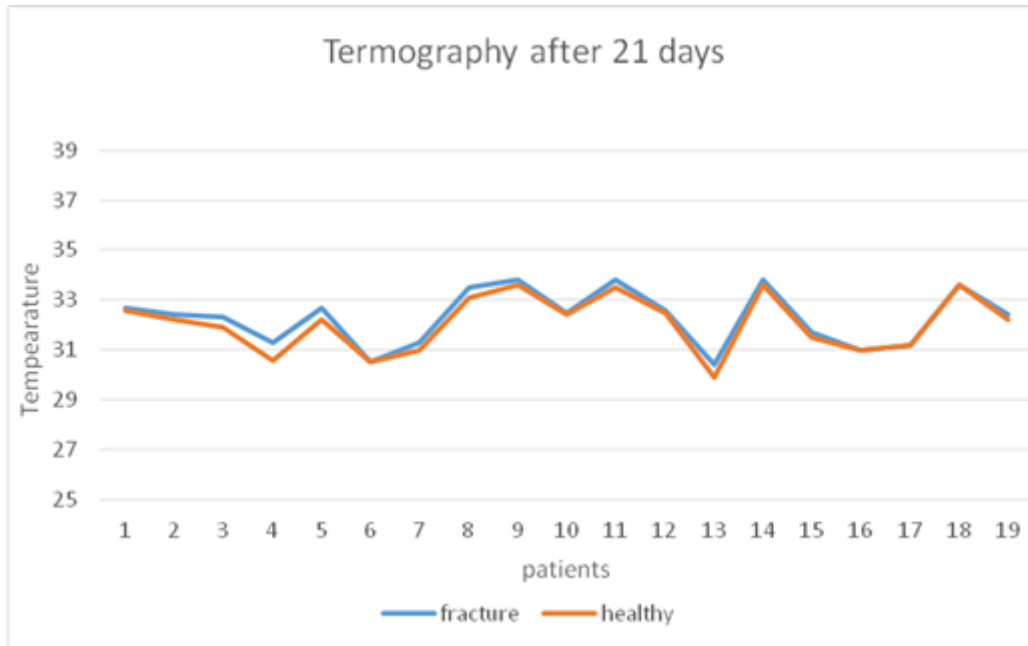
Measurement made 14 days after initial injury showed that temperature on fractured side is still higher but temperature difference between fractured and healthy forearm are lower. They varies from $0,4^{\circ}\text{C}$ to $1,4^{\circ}\text{C}$. In comparison to results 7 days earlier they are in average for 1°C lower (Chart 2.).

Chart 2. Temperature measurements on both forearms after 14 days



And 21 days after initial injury results are as we presumed. Temperature difference between fracture and healthy side is low. It varies from 0°C to 0, 7°C. Results correlate with pathophysiology of pediatric fractures where it is well known that remodeling phase of fractured children's forearm is already started after 3rd week (Chart 3.).

Chart 3. Temperature measurements on both forearms after 21 days



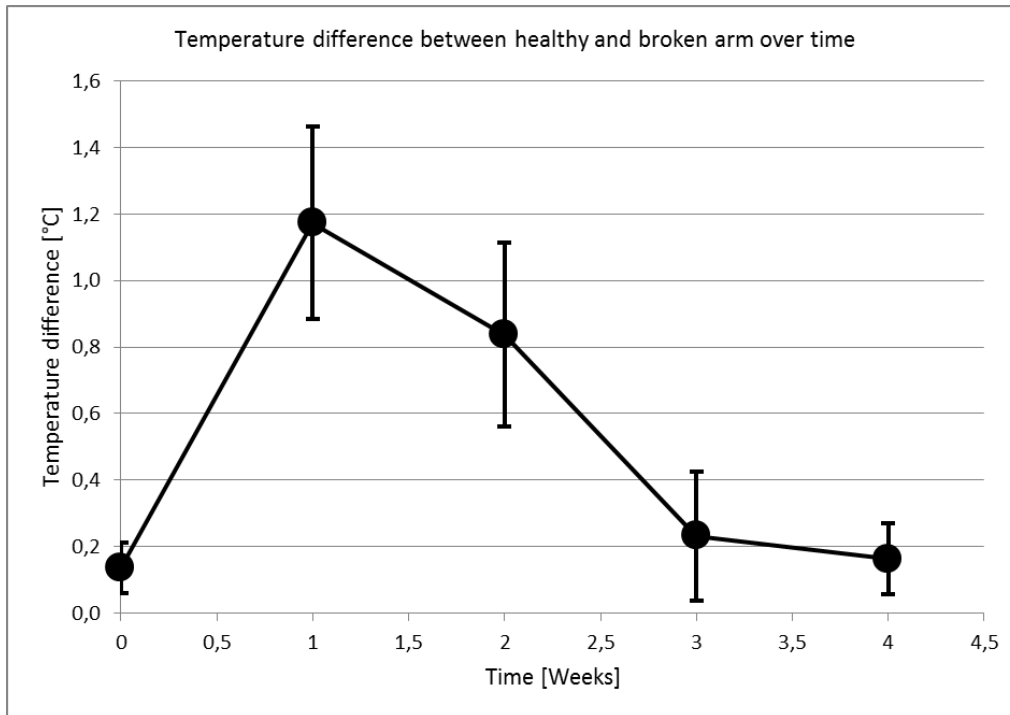
On chart and table below it is visible that temperature difference between fractured and healthy forearm at highest 7 days after fracture. Highest temperature difference is 2°C, and is measured on 7th day, and lowest temperature difference is 0°C (no temperature difference between forearms) which is taken on 21nd day and one month after fracture (Table 1. and Chart 4).

Table 1.

Temperature difference between broken and healthy arm over time

| Patients | First day | First week | Second week | Third week | One week |
|-----------------|------------------|-------------------|--------------------|-------------------|-----------------|
| 1 | 0,1 | 2 | 1,1 | 0,2 | 0,1 |
| 2 | 0,2 | 1,6 | 0,9 | 0,2 | 0,2 |
| 3 | 0,2 | 1,3 | 0,6 | 0,4 | 0,2 |
| 4 | 0,3 | 1 | 1,4 | 0,7 | 0,3 |
| 5 | 0,2 | 1 | 1,1 | 0,5 | 0,2 |
| 6 | 0,1 | 1,2 | 0,8 | 0 | 0,1 |
| 7 | 0,2 | 1,2 | 1 | 0,3 | 0,2 |
| 8 | 0,2 | 1,2 | 0,5 | 0,4 | 0,2 |
| 9 | 0,1 | 1,6 | 0,6 | 0,2 | 0,1 |
| 10 | 0,1 | 0,8 | 0,6 | 0,1 | 0,1 |
| 11 | 0,2 | 1,2 | 0,6 | 0,3 | 0,2 |
| 12 | 0,1 | 1,1 | 0,4 | 0,1 | 0,1 |
| 13 | 0,2 | 1,1 | 1,1 | 0,5 | 0,2 |
| 14 | 0,1 | 1,1 | 0,4 | 0,2 | 0,1 |
| 16 | 0,1 | 0,9 | 1 | 0,2 | 0,1 |
| 16 | 0,1 | 1,1 | 0,5 | 0 | 0,1 |
| 17 | 0 | 1,1 | 0,8 | 0 | 0 |
| 18 | 0 | 1,2 | 0,7 | 0 | 0 |
| 19 | 0,1 | 1,6 | 0,8 | 0,2 | 0,1 |
| | 0,136842 | 1,173684 | 0,836842 | 0,231579 | 0,136842 |

Chart 4. Temperature difference between healthy and broken arm over time



Discussion

The measurements demonstrate noticeable discrepancies in temperature differences over a period of time. With such a small number of samples and measurements, even smaller discrepancies can contribute to the total error. In order to decrease this error, it is necessary to conduct measurements on a larger number of patients (min. 30) and more frequently (at least every three to four days or even more often if possible).

It is to presume that in younger children 7-14 days after initial injury on fracture site there is furious periosteal reaction and after that quick fibrous callus formation which lowers fracture site temperature. Formation of bony bridges in fibrous callus makes fracture site stable. In everyday pediatric surgery outpatient clinic we see that as visible callus formation on plain radiology scan.

In this pilot study it is visible that temperature difference between broken and healthy forearm is highest 7 days after injury and temperature difference is from 0,8°C till 2° C. It correlates with fast periosteal reaction on site of fracture. Seven days later temperature difference is

smaller, from 0, 4°C till 1, 4°C as local periosteal reaction is decreasing and fibrous callus is forming. Finally after 21 day temperature difference is smallest, from 0°C to 0, 7°C, as bony bridges form inside fibrous callus and fracture becomes stable. Those results shown in this pilot study, make our assumptions right, that change of local temperature at fracture site follows well known radiological healing of children's bone.

Results shown in this pilot study take us to relative conclusions, but to accomplish better results we need to have bigger group of participants, compare result in the smaller age groups (divide participant into groups from 4-8 years, 8-12 years and teenagers) and differ them with types of forearm fractures. As a result we will get numeric value (temperature) which will correlate with bone healing process which we see on plain radiography and in that way implement thermography in standard fracture healing follow up, lowering down frequency of exposure to x-rays.

It is also to presume that study made on older children groups and teenagers will have different results, as well as study on adults, as it is well known in trauma that fracture healing in children and adults differ.

Conclusion

Our pilot study on pediatric distal forearm fracture takes us to conclusion that there is noticeable temperature difference between broken and healthy forearm and that can be measured with thermographic camera. As we have already said we need to increase the number of participants and make more frequent temperature measurements to decrease total error and have better results.

If this future research takes us to the point to decrease radiography scans even for one, we can say we have made scientific progress in follow up of pediatric forearm fractures.

In our Medical Research Institute there is also research in progress which deals with use of thermography in adults distal forearm fractures.

References

1. Rennie L, Court-Brown CM, Mok JYQ, Beattie TM. The epidemiology of fractures in children. *Injury*. 2007 Aug; 38(8):913-22.
2. Oskam J, Kingma J, Klasen HJ. Fracture of the distal forearm: epidemiological developments in the period 1971–1995. *Injury* 1998;29(5):353–5.
3. Green JS, Williams SC, Finlay D, Harper WM. Distal forearm fractures in children: the role of radiographs during follow up, *Injury* 1998;29(4);309–12.
4. Antabak A, Luetić T, Sjekavica I, Karlo R, Cavar S, Bogović M, Srsen Medancic S. Treatment outcomes of both-bone diaphyseal paediatric forearm fractures. *Injury*. 2013 Sep;44 Suppl 3:S11-5.
5. American Academy of Thermology. <http://aathermology.org/organization/thermology>
6. Merla A., Romani G. L. Functional infrared imaging in medicine: a quantitative diagnostic approach. *Proceedings of the 28th Annual International Conference of the IEEE Engineering in Medicine and Biology Society (EMBS '06)*; September 2006; pp. 224–7.
7. Jiang L, Ng EY, Yeo AC et al. A perspective on medical infrared imaging. *J Med Eng Technol*. 2005 Nov-Dec; 29(6):257-67.
8. Overview of Digital Infrared Thermal Imaging. http://www.meditherm.com/thermography_page1.htm
9. Całkosiński I, Dobrzyński M, Rosińczuk J, Dudek K, Chrószcz A, Fita K, Dymarek R: The Use of Infrared Thermography as a Rapid, Quantitative, and Noninvasive Method for Evaluation of Inflammation Response in Different Anatomical Regions of Rats; *Biomed Res Int*. 2015;2015:972535. doi: 10.1155/2015/972535. Epub 2015 Mar 5.
10. Declaration of Helsinki World Medical Association. <http://www.wma.net/e/ethicsunit/helsinki.htm>