

Bilateral thalamic astrocytoma

**Habek, Mario; Brinar, Vesna V.; Mubrin, Zdenko; Barun, Barbara;
Žarković, Kamelija**

Source / Izvornik: **Journal of Neuro-Oncology, 2007, 84, 175 - 177**

Journal article, Accepted version

Rad u časopisu, Završna verzija rukopisa prihvaćena za objavljivanje (postprint)

<https://doi.org/10.1007/s11060-007-9404-5>

Permanent link / Trajna poveznica: <https://um.nsk.hr/um:nbn:hr:105:311402>

Rights / Prava: [In copyright](#)/[Zaštićeno autorskim pravom.](#)

Download date / Datum preuzimanja: **2024-08-01**



Repository / Repozitorij:

[Dr Med - University of Zagreb School of Medicine
Digital Repository](#)





Središnja medicinska knjižnica

Habek, M., Brinar, V. V., Mubrin, Z., Barun, B., Žarković, K. (2007) *Bilateral thalamic astrocytoma*. *Journal of Neuro-Oncology*, [Epub ahead of print].

The original publication is available at www.springerlink.com
<http://www.springerlink.com/content/x8463m5vt84783h3/>

<http://medlib.mef.hr/274>

University of Zagreb Medical School Repository

<http://medlib.mef.hr/>

Bilateral thalamic astrocytoma

Mario Habek, Vesna V. Brinar, Zdenko Mubrin, Barbara Barun

University Department of Neurology, Zagreb School of Medicine and University Hospital Center, Zagreb, Croatia

Corresponding author:

Mario Habek, MD

University Department of Neurology

Zagreb School of Medicine and University Hospital Center

Kišpatićeva 12

HR-10000 Zagreb, Croatia

Phoe: +38598883323; Fax +38512421891; e-mail: mhabek@mef.hr

Key words : Bilateral thalamic astrocytoma; Dementia; MRI

A 68-year-old woman was admitted to our Department for cognitive disturbances. The first symptoms occurred three years before when her family members observed her to show forgetfulness and difficulties in performing daily house work. After her husband death, her condition progressed, she used to get lost in her neighborhood and did not recognize her family members. She was seen by a neurologist at a local hospital, where the diagnosis of Alzheimer's disease was made. At that time, non-contrast brain CT scan was normal. In November 2006, she presented to our Department for the first time. At that time she was disoriented in time and place, with severe deficit of short term memory and visual-spatial construction and object recognition. She had positive palmomental reflexes. Motor, sensory and cranial nerve examination was normal. The working diagnosis was frontotemporal dementia and the patient was scheduled for brain MRI. MRI findings are presented in Figures 1 and 2. MRI spectroscopy revealed elevated choline level compared to creatine, and a decreased level of N-acetylaspartate. Stereotactic biopsy revealed atypical glial cells with irregular, elongated, hyperchromatic nuclei (Figure 3). According to WHO classification, the tumor corresponded to diffuse fibrillary astrocytoma grade II. Bilateral thalamic astrocytomas are very rare tumors. In most of the reported cases, the presenting symptoms were cognitive impairment and normal cranial nerve, motor and sensory examination (1). Because of these characteristics, the diagnosis is often delayed, making treatment options very limited. This case points to the role of neuroimaging in patients presenting with classical symptoms of dementia.

Reference:

- 1) Hirano H, Yokoyama S, Nakayama M, Nagata S, Kuratsu J. Bilateral thalamic glioma: case report. *Neuroradiology* 2000;42:732-4.

Figure 1. Brain MRI, T2 weighted.

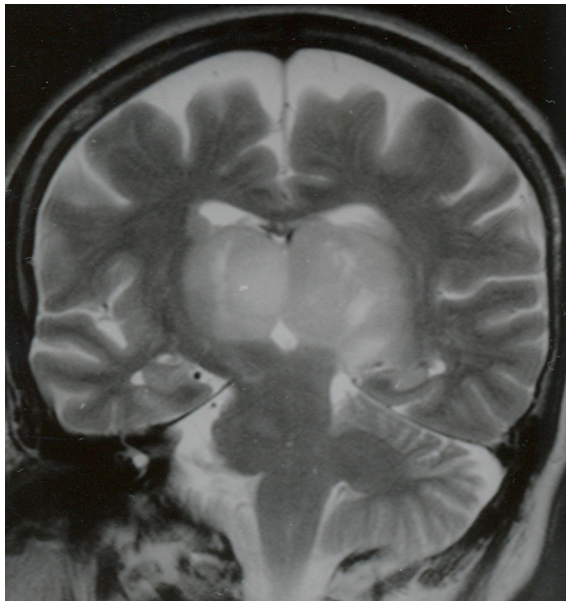


Figure 2. T1 weighted, post-contrast sequences showing tumor mass in both thalami, more pronounced on the left side where it infiltrated the head of caudate nuclei, the putamen, part of insular cortex, the base of frontal lobe, the amygdala bilaterally and the hippocampus. Gadolinium application yielded enhancement of the pulvinar thalami bilaterally.

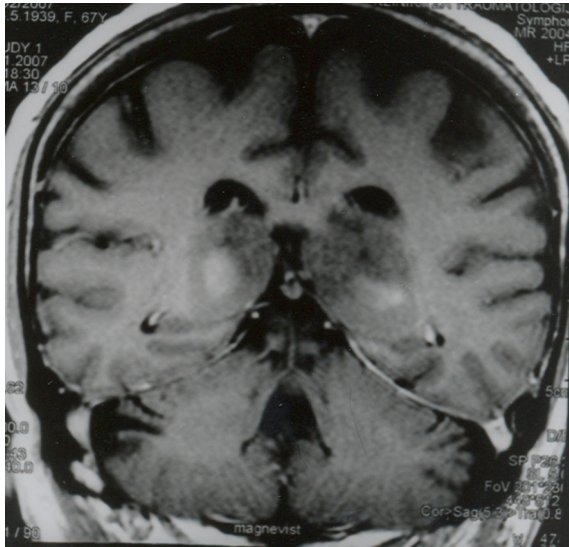


Figure 3. (A) and (B) Biopsy after neurosurgical treatment yielded three needle cores of grayish cerebral tissue. Hematoxylin-eosin stained sections of paraffin embedded tissue showed gray brain tissue infiltrated with neoplastic fibrillary astrocytes with occasional nuclear atypia. Mitotic activity, necrosis and microvascular proliferation were absent; (C) tumor cells showing diffuse GFAP expression; (D) the proliferation fraction, measured by Ki 67, was absent.

