

Expression and prognostic value of putative cancer stem cell markers CD117 and CD15 in choroidal and ciliary body melanoma

Lukenda, Adrian; Dotlić, Snježana; Vukojević, Nenad; Šarić, Borna; Vranić, Semir; Žarković, Kamelija

Source / Izvornik: **Journal of Clinical Pathology**, 2015, 69, 234 - 239

Journal article, Accepted version

Rad u časopisu, Završna verzija rukopisa prihvaćena za objavljivanje (postprint)

<https://doi.org/10.1136/jclinpath-2015-203130>

Permanent link / Trajna poveznica: <https://um.nsk.hr/um:nbn:hr:105:418549>

Rights / Prava: [In copyright](#)/[Zaštićeno autorskim pravom](#).

Download date / Datum preuzimanja: **2024-10-06**



Repository / Repozitorij:

[Dr Med - University of Zagreb School of Medicine Digital Repository](#)





Središnja medicinska knjižnica

Lukenda A., Dotlić S., Vukojević N., Šarić B., Vranić S., Žarković K.
(2016) *Expression and prognostic value of putative cancer stem cell markers CD117 and CD15 in choroidal and ciliary body melanoma.*
Journal of Clinical Pathology, 69 (3). pp. 234-9. ISSN 0021-9746

<http://jcp.bmj.com/>

<http://dx.doi.org/10.1136/jclinpath-2015-203130>

<http://medlib.mef.hr/2759>

University of Zagreb Medical School Repository

<http://medlib.mef.hr/>

Running title:

Expression and prognostic value of putative cancer stem cell markers

CD117 and CD15 in choroidal and ciliary body melanoma

Adrian Lukenda^{1*}, Snjezana Dotlic², Nenad Vukojevic³, Borna Saric⁴, Semir Vranic⁵,
Kamelija Zarkovic⁶

¹ Ocna poliklinika Opto Centar, Vlaska 64, Zagreb, Croatia

² Department of Pathology and Cytology, University Hospital Center Zagreb, Zagreb, Croatia

³ Department of Ophthalmology, University Hospital Center Zagreb, Zagreb, Croatia

⁴ Ophthalmology Clinic, University Hospital "Sveti Duh", Zagreb, Croatia

⁵ Department of Pathology, Clinical Center of the University of Sarajevo, Sarajevo, Bosnia and Herzegovina

⁶ Department of Pathology, Zagreb University School of Medicine, Croatia

***Corresponding author:**

Adrian Lukenda

Livadiceva 33

10000 Zagreb

Croatia

E-mail: alukenda@opto-centar.hr

Telephone: +3851 4686 544

Fax: +3851 4614144

Key words: Uveal melanoma, cancer stem cell, marker, CD117, CD15

Word count: 2628

ABSTRACT

Aims: The aim of the present study was to immunohistochemically investigate the expression and prognostic significance of putative cancer stem cell markers CD117 (c-kit), CD34, CD20 and CD15 in a cohort of patients with primary choroidal and ciliary body melanoma.

Methods: The immunohistochemical expression of these markers was evaluated using DAB and AEC chromogens on paraffin-embedded tissue samples from 40 patients who underwent enucleation in the period from 1985 through 2000. Thirty-one patients had adequate tissue specimens for analysis.

Results: CD117 overexpression was observed in 12 of the 31 samples (39%) when AEC chromogen was used and in 14 of 26 (54%) samples when DAB was used. CD15 positivity was seen in 3 out of 30 (10%) samples with AEC and in 6 out of 26 (23%) samples with DAB. CD20 and CD34 exhibited no positivity in the tested samples. During the follow-up time, 17 patients (55%) died due to metastatic disease. The Kaplan-Meier plots showed a significantly shorter overall and disease-free survival in CD117-positive patients when the AEC chromogen was used. CD15 expression had no impact on patients' survival. In multivariate analysis, patients expressing the CD117 AEC had 4.13 times higher risk of lethal outcome in comparison with CD117 AEC negative patients.

Conclusions: Our retrospective cohort study has for the first time demonstrated a small proportion of CD15-positive uveal melanomas. CD117 AEC overexpression was associated with a worse outcome in patients with choroidal and ciliary body melanoma. Further studies should confirm the validity of these observations and their potential for targeted treatment modalities.

INTRODUCTION

Malignant melanoma arising in the uveal tract is a rare neoplasm constituting less than 1% of all malignant tumors, but represents the most common ocular malignancy in adults.[1, 2]

Despite a good local control accomplished with radiotherapy, phototherapy, local resection or enucleation, a median survival reported in large studies was 7 years.[3] Approximately half of the patients develop metastatic disease and die within 15 years after diagnosis.[4] Metastases tend to be highly resistant to various treatment modalities.[3, 4] The risk of metastasis in choroidal and ciliary body melanomas is significantly higher than in melanomas of the iris, which justifies a separate investigation of these two uveal melanoma subgroups.[5]

A slow progress in the treatment of the metastatic disease has renewed the interest in the cancer stem cell (CSC) model as a basis for the research of underlying molecular mechanisms.[6] Many putative cancer stem cell markers, including CD117, CD34, CD20 and CD15, have been proposed.[6-10] However, no universal cancer stem cell marker has been found to be expressed in all solid tumors.

The transmembrane tyrosine kinase receptor CD117 (c-kit) is expressed in both normal and malignant tumors; the tumor expression includes both solid and hematological neoplasms. When activated by its ligand, known as stem cell factor (SCF), CD117 triggers signaling pathways that are involved in various cell functions including cell survival, proliferation, apoptosis, differentiation, and migration.[11]

The percentage of primary uveal melanoma patients expressing the immunohistochemical marker CD117 has been reported to vary between 63% and 87%,[12-15] while one study reported a 100% positivity rate.[16] No significant correlation between CD117 expression, with survival or metastasis formation, was

found in three studies that have investigated the prognostic significance of CD117 in patients with uveal melanoma.[12, 13, 16]

The expression of other putative stem cell markers CD15, CD20, and CD34 on choroidal and/or ciliary body melanoma tissue samples has not yet been explored. In one melanoma cell line from the NCI60 tumor panel, 20.5% of tumor cells expressed CD15 when analyzed by flow cytometry.[10] CD15 is a cell surface carbohydrate antigen expressed on most differentiated myeloid cells, adult neural stem/progenitor cells, some epithelial cells, as well as in different cancers including lymphomas, carcinomas, and gliomas. The prognostic value of the expression of sialylated form of CD15 (sLe^x) is still controversial, but positive correlation with poor outcome was shown in patients with colorectal cancer and breast cancer.[17]

Glycoprotein CD34 is expressed by human myeloid and lymphoid progenitor cells, including the haemopoietic stem cells. It may also be expressed in vascular and spindle cell tumors and infrequently in cutaneous melanomas.[18] CD34 was one of the first specific markers found to be expressed in a subpopulation of cells capable of initiating tumors in an immunocompromised host.[7] Similarly, a minor subset of CD20-positive tumor cells that were isolated from cutaneous melanoma and detected by flow cytometry were recently shown to be capable of initiating new melanoma lesions when transplanted into immune-deficient NIH-III mice.[8] Targeted elimination of CD20-positive melanoma cells resulted in complete and lasting eradication of established tumor lesions.

The purpose of this study was to investigate the expression and prognostic significance of putative cancer stem cell markers CD117, CD34, CD20, and CD15 in a cohort of primary choroidal and ciliary body melanomas.

MATERIALS AND METHODS

Patients

Formalin-fixed paraffin-embedded tissue samples from 40 Caucasian patients with primary melanoma of the ciliary body or choroid, who have undergone enucleation in the period from 1985 through 2000, were retrieved from the archive at the Department of Pathology, University Hospital Center Zagreb. Only patients for whom data on the largest tumor diameter (LTD) was available, patients who did not receive irradiation or chemotherapy prior to enucleation, and those with minimum follow-up of 7 years, if alive, were included in the study.

Nine patients were excluded from the study due to a) in 6 patients the tissue was not adequate for processing and staining due to suboptimal fixation or insufficient tumor tissue, b) two tumors were located in the iris, and c) extensive necrosis precluded appropriate evaluation in one patient. Final analysis included 31 patients. The study was approved by the Ethics Committee of Zagreb University Medical School.

Methods

Tissue samples were fixed in 10% buffered formalin and embedded in paraffin. Haematoxylin-eosin stained sections from each specimen were independently reviewed by two pathologists without knowledge of the clinical outcome (K.Z., S.D.). All tumors were classified according to the modified Callender classification.[19] Tumors composed only of spindle cells were classified as spindle cell melanomas, tumors containing both spindle and epithelioid cells as mixed, and tumors composed of more than 50% epithelioid cells as epithelioid melanomas.

Immunohistochemical analysis was performed on deparaffinized tissue sections (4 μ m), using following antibodies obtained from Dako (Glostrup, Denmark): mouse monoclonal CD15 (clone Carb-3, 1:30), CD20 (clone L26, 1:200), CD34

(clone QBEnd 10, 1:50) antibodies, and a rabbit polyclonal antibody CD117 (1:300). The staining was performed in Dako Autostainer Universal Staining System (Glostrup, Denmark) for all antibodies except CD15, which was stained manually. Antigen retrieval was performed with high-pH buffer 9.0 at 97°C for 14 minutes. Following peroxidase block, visualization of the antigen–antibody complex was carried out with Dako EnVision FLEX system, using 3-amino-9-ethylcarbazole (AEC) and 3,3'-diaminobenzidine tetrahydrochloride (DAB) as chromogens. Two chromogen protocols were used because of possible interference of the endogenous pigment with DAB-detection system in melanoma samples.[20, 21] Also, in order to preserve the epitopes, no bleaching was applied. Consequently, 5 heavily pigmented melanomas stained with CD117 and DAB chromogen were excluded from further analysis. Finally, sections were counterstained with Mayer's haematoxylin. Both positive and negative controls were included in all assays.

The intensity of the staining and the percentage of positive tumor cells were evaluated by two blinded, independent pathologists (K.Z., S.D.). Samples were classified as positive if more than 10% of tumor cells displayed distinct immunostaining pattern, irrespective of the staining intensity.

Statistics

Overall (OS) and disease-specific (DS) survival were calculated as the time from diagnosis to the date of death (endpoint reached or censored) or last contact (censored) and plotted as survival curves according to the Kaplan–Meier method. The associations between CD117 expression and outcomes were analyzed using the log-rank test. Univariate and multivariate analyses were performed using Cox proportional-hazards regression to analyze the effect of several parameters as possible independent risk factors on OS and DS. Cox regression statistics was presented with regression coefficient (b), standard error of regression coefficient (SE(b)), and hazard

ratio (HR) with 95% confidence intervals (95% CI). *P*-values lower than 0.05 were considered significant. Statistical analysis was done using IBM SPSS Statistics version 21 (IBM, Armonk, NY, USA).

RESULTS

Demographic and clinicopathologic characteristics of the cohort

The results are outlined in Table 1.

Among 31 patients with choroidal and ciliary body melanoma that fulfilled the entry criteria there were 16 women (52%) and 15 men (48%). The median age at the time of enucleation was 63 years (range 29-85 years). The average follow-up time was 8.7 years (range 0.5-22 years). During the follow-up, 20 patients (65%) had died and 17 patients (55%) of which were due to metastatic disease.

Expression of immunohistochemical markers

Immunohistochemical staining with CD117 showed immunoreactivity (>10% of the tumor cells) confined to the plasma membrane and/or cytoplasm in 12 of 31 samples (39%) when AEC chromogen was used, and in 14 of 26 (54%) samples when DAB was used (Figure 1). Predominantly focal cytoplasmic positive reaction for CD15 was observed in 3 out of 30 (10%) samples with AEC chromogen and 6 out of 26 (23%) samples with DAB (Table 1). Immunohistochemical staining for CD20 and CD34 with both chromogens revealed no positive tumor cells in any of the tested samples.

Survival analysis

The median OS for the studied patients was 8 years. The estimated five-year OS and DS was 67.7% (SE 8.4%) and 66.1% (SE 9.2%), respectively. The analysis of Kaplan-Meier plots showed a significantly shorter OS ($p=0.005$) and DS ($p=0.009$), as well as 5-year OS (Breslow, $p=0.001$) and DS ($p=0.006$) in CD117 positive patients when AEC chromogen was used (Figure 2). No significant difference was found when DAB was used as a chromogen for CD117 staining. CD15 expression had no influence on OS and DS when either chromogen was used.

Of 11 demographic and histopathologic parameters listed in Table 1, univariate analysis revealed significant associations between age ($p=0.038$), epithelioid tumor type ($p=0.005$), LTD >18 mm ($p=0.016$), positive CD117 AEC reaction ($p=0.008$) and OS, as well as between age ($p=0.043$), epithelioid type ($p=0.013$), positive CD117 AEC reaction ($p=0.014$) and DS.

In multivariate analysis CD117-positivity remained its significance for OS after adjusting for tumor type and age, as well as for DS after adjusting for tumor type, age, gender, lymphocyte infiltration and ciliary body involvement. Patients with CD117 positive melanomas analyzed with AEC chromogen had 4.13 times higher risk ($p=0.017$, 95% CI: 1.289-13.223) of lethal outcome in comparison with CD117 AEC negative cases. In the same model, age marginally influenced DS by increasing the hazard ratio for 4.3% every year (95% CI: 1.000-1.087, $p=0.48$; Table 2).

DISCUSSION

The absence of lymphatic drainage in the non-inflamed uveal tract explains the lack of lymphatic spread in uveal melanoma. Hence, the only route of its invariably fatal metastatic spread is the hematogenous dissemination of tumor cells. The dichotomy of outcomes makes uveal melanoma a simple model for studying various potential prognostic factors in relatively small cohorts of patients.[22]

The most intriguing characteristics of uveal melanoma cells are their extended period of proliferative quiescence and complete chemoresistance of disseminated tumor cells. A recent study has demonstrated a subpopulation of uveal melanoma cells that can sustain progression with increased resistance to chemotherapeutical agents [8]. It is postulated that these small subsets of cells can drive tumor initiation and progression resembling the resistance of normal stem cells to cytotoxic agents and radiation, hence the name cancer stem cells.[23]

Many potential CSC markers have been described but so far no universal single immunohistochemical marker has been found. In this study we have investigated the expression and prognostic significance of routinely used antibodies against putative CSC markers CD15, CD20, CD34, and CD117 of which only CD15 and CD117 exhibited positivity in the melanoma cells. The expression and prognostic value of CD117 has been well documented in various human cancers, often with variable and conflicting results.[24] PubMed literature search revealed only three studies that explored the expression and prognostic significance of CD117 in uveal melanoma.[12, 13, 16] In these studies, as in our study, the OS and DS were shorter when compared with large epidemiological studies.[4] This result was expected because larger tumors are known to carry worse prognosis. In both our and the other three studies tumors were obtained by enucleation, which is mostly performed for tumors with larger LTD.

In the present study we have demonstrated a significant association between CD117 expression and OS and DS when the AEC chromogen was used. This finding is in contrast to the previously published data.[12, 13, 16] Since the obtained basic demographic data was comparably similar in all studies, the variability of fixation and immunohistochemical techniques might account for this discrepancy. It has been reported that variable antigen retrieval techniques, the dilutions and choice of antibodies or chromogens, as well as arbitrary cutoff values can influence the interpretation immunohistochemical analysis.[25] This variability might explain substantial differences in the proportion of CD117 positive tumors between the studies. The percentage of CD117 DAB positive patients in the study with the largest cohort of patients was 63%,[13] which is somewhat higher than in our study. In the same study, the percentage of CD117 positive samples was higher (88%) when Western blot technique on fresh frozen tumor samples was used, suggesting different detection thresholds for various methods.

We have also shown a clear difference in the expression and prognostic significance of CD117 when different chromogens were used. As in the study by *All Ericsson et al.*, we found no correlation with survival when DAB chromogen was used. We can hypothesize that this might be due to the higher specificity and lower sensitivity of AEC staining, especially since all AEC- positive samples in our study were also positive when DAB chromogen was used. The use of red chromogen is advised in melanoma because the endogenous brown pigment may interfere with the detection of the more commonly used DAB chromogen.[20, 21] We did not use bleaching to eliminate melanin from the DAB stains to avoid any additional alterations in the expression of antigens. The subsequent exclusion of highly pigmented samples in our DAB-stained series should not have significantly influenced the results due to the lack of prognostic significance of the pigmentation rate in our study. In the third

study by *Luke et al.*, no prognostic value of high versus low CD117 expression was found. However, in the same study all uveal melanomas tested positive for CD117, making the analogy more difficult.

Interestingly, Kaplan-Meier survival curves of CD117-positive and negative patients in the study from *Mouriaux et al.* who have also studied a subgroup of patients with choroidal and ciliary body melanoma using AEC as chromogen, were comparably similar to our CD117 AEC survival plots. In the same study the survival rate at 87 months was 35% for CD117 positive patients and 78% for CD117 negative patients, as compared to 33% and 78% in our study. The difference in the survival rates in that study did not reach statistical significance, but CD117 expression was positively associated with mitotic activity.

To our knowledge, CD15 expression was not previously reported in patients with uveal melanoma. In our study, 10% to 23% of uveal melanoma samples displayed distinct and predominant focal positivity when AEC or DAB chromogen were used. Some authors suggest that the role of sLe^x in interactions between disseminated tumor cells and endothelial cells could provide a possible explanation for the correlation between sLe^x expression and poor outcome in patients with colorectal and breast cancer.[17] Our results did not demonstrate an association between CD15 expression and survival, but the number of the CD15-positive uveal melanoma patients in our cohort was small.

The prevention and treatment of metastatic uveal melanoma have not substantially improved in the last few decades.[15] A more personalized approach, which would include early stratification of patients according to verified prognostic factors and potential therapeutic response, is therefore required. Recent advances in molecular technologies, gene expression profiling in particular, have shown promising results in overcoming the weaknesses of traditional cytogenetic methods. These are

mostly attributed to the non-uniform distribution of cytogenetic abnormalities in uveal melanomas.[26]

Nevertheless, immunohistochemistry is a widely available diagnostic tool for visualization of the antigen localization in the context of tissue morphology. In spite of CD117 overexpression in uveal melanoma and its possible prognostic significance, no significant clinical response to therapy with CD117 inhibitor imatinib mesylate was noted in CD117 positive patients.[11] Poor clinical efficacy may be attributed to the low frequency (1-10%) of KIT mutations in all types of ocular melanoma and a limited correlation between KIT mutations and CD117-positivity detected immunohistochemically.[14] Nevertheless, in patients with confirmed KIT mutations in skin melanomas, encouraging results of imatinib therapy were observed.[14] The more frequent mechanisms of CD117 overexpression might include SCF/CD117 autocrine stimulation loop, gene amplification or constitutive phosphorylation of the receptor and dysfunction of phosphatases that turn off the activation.[13, 14]

In summary, our study has for the first time revealed a small percentage of CD15-positive uveal melanomas. CD15 positivity was not associated with patients' survival, which might be caused by a small sample size of our study. We have also demonstrated a correlation between CD117 expression and survival in patients with choroidal and ciliary body melanoma when AEC was used as the chromogen. Further studies should determine the validity of these markers in patient stratification and therapeutic considerations respecting the possible influence of the chosen technique on the final interpretation.

Key messages

- * A subset of choroidal and ciliary body melanomas overexpress the CD15 antigen.
- * CD117 overexpression can be associated with poor survival when AEC is used as a chromogen.
- * The use of different immunohistochemical techniques may significantly influence the final results.

Acknowledgments

We are grateful for the technical assistance provided by Ms. Katarina Raznjevic. We also thank Dr. Martina Herwig for her valuable advice in the design of the study and the late Professor Marin Nola (1964-2008) for initiating this research.

Competing Interests

The authors have no conflict of interest to disclose.

Ethical approval

The study was approved by the Ethics Committee of Zagreb University Medical School.

Contributions:

Conceived and designed the study: AL and KZ. Acquired and analyzed the data: AL, SD, NB, BS, SV, AS. Wrote and drafted the manuscript: AL, SD, SV, KZ. All authors have read, revised and approved the final version of the manuscript.

Funding:

There are no funders to report for this submission.

Permissions and exclusive licenses:

Original research. Exclusive licence granted on behalf of all authors to the BMJ Publishing group to be published in Journal of Clinical Pathology.

REFERENCES

- 1 Singh AD, Topham A. Incidence of uveal melanoma in the United States: 1973-1997. *Ophthalmology* 2003;110:956-61.
- 2 Bergman L, Seregard S, Nilsson B, et al. Incidence of uveal melanoma in Sweden from 1960 to 1998. *Invest Ophthalmol Vis Sci* 2002;43:2579-83.
- 3 Willson JK, Albert DM, Diener-West M et al., Assessment of metastatic disease status at death in 435 patients with large choroidal melanoma in the Collaborative Ocular Melanoma Study (COMS): COMS report no.15. *Arch Ophthalmol* 2001;119:670-6.
- 4 Kujala E, Mäkitie T, Kivelä T. Very long-term prognosis of patients with malignant uveal melanoma. *Invest Ophthalmol Vis Sci* 2003;44:4651-9.
- 5 Henderson E, Margo CE. Iris melanoma. *Arch Pathol Lab Med* 2008;132:268-72.
- 6 Kalirai H, Damato BE, Coupland SE. Uveal melanoma cell lines contain stem-like cells that self-renew, produce differentiated progeny, and survive chemotherapy. *Invest Ophthalmol Vis Sci* 2011;52:8458-66.
- 7 Bonnet D, Dick JE. Human acute myeloid leukemia is organized as a hierarchy that originates from a primitive hematopoietic cell. *Nat Med* 1997;3:730-7.
- 8 Schmidt P, Abken H. The beating heart of melanomas: a minor subset of cancer cells sustains tumor growth. *Oncotarget* 2011;2:313-20.
- 9 Dahlrot RH, Hermansen SK, Hansen S, et al. What is the clinical value of cancer stem cell markers in gliomas? *Int J Clin Exp Pathol* 2013;6:334-48.
- 10 Stuelten CH, Mertins SD, Busch JI, et al. Complex display of putative tumor stem cell markers in the NCI60 tumor cell line panel. *Stem Cells* 2010;28:649-60
doi:10.1002/stem.324.

- 11 Miettinen M, Lasota J. KIT (CD117): a review on expression in normal and neoplastic tissues, and mutations and their clinicopathologic correlation. *Appl Immunohistochem Mol Morphol* 2005;13:205-20.
- 12 Mouriaux F, Kherrouche Z, Maurage CA, et al. Expression of the c-kit receptor in choroidal melanomas. *Melanoma Res* 2003;13:161-6.
- 13 All-Ericsson C1, Girnita L, Müller-Brunotte A, et al. C-Kit-dependent growth of uveal melanoma cells: a potential therapeutic target? *Invest Ophthalmol Vis Sci* 2004;45:2075-82.
- 14 Wallander ML, Layfield LJ, Emerson LL, et al. KIT mutations in ocular melanoma: frequency and anatomic distribution. *Mod Pathol* 2011;24:1031-5.
- 15 Pache M, Glatz K, Bösch D, et al. Sequence analysis and high-throughput immunohistochemical profiling of KIT (CD 117) expression in uveal melanoma using tissue microarrays. *Virchows Arch* 2003;443:741-4.
- 16 Lüke J, Wegner J, Wegner R, et al. Expression of c-Kit and its ligand SCF in primary uveal melanoma. *Eur J Ophthalmol* 2011;21:615-24.
- 17 Machida E, Nakayama J, Amano J, et al. Clinicopathological significance of core 2 beta1,6-N-acetylglucosaminyltransferase messenger RNA expressed in the pulmonary adenocarcinoma determined by in situ hybridization. *Cancer Res.* 2001;61:2226-31.
- 18 Breza TS, Magro CM. CD34 expression in primary cutaneous malignant melanoma: apropos of a case and review of the aberrant melanoma phenotype. *J Cutan Pathol* 2005;32:685-9.
- 19 McLean IW, Foster WD, Zimmerman LE, et al. Modifications of Callender's classifications of uveal melanoma at the Armed Forces Institute of Pathology. *Am J Ophthalmol* 1983;96:502-9.

- 20 Sanderson T, Zardin G. Immunohistochemistry quality control. In: Suvarna KS, ed. Bancroft's Theory and Practice of Histological Techniques: Expert Consult : Online and Print. Edinburgh: Churchill Livingstone 2012:435-455.
- 21 Ferringer T. Skin. In: Lin F, Prichard JW, Liu H, Wilkerson M, Schuerch C, eds. Handbook of Practical Immunohistochemistry: Frequently Asked Questions. New York, NY: Springer 2011: 524.
- 22 Petrausch U, Martus P, Tönnies H, et al. Significance of gene expression analysis in uveal melanoma in comparison to standard risk factors for risk assessment of subsequent metastases. Eye (Lond) 2008;22:997-1007.
- 23 Wicha MS, Liu S, Dontu G. Cancer stem cells: an old idea--a paradigm shift. Cancer Res 2006;66:1883-90.
- 24 Zhao F, Chen Y, Wu Q, et al. Prognostic value of CD117 in cancer: a meta-analysis. Int J Clin Exp Pathol 2014;7:1012-21.
- 25 De Wit NJ, van Muijen GN, Ruiters DJ. Immunohistochemistry in melanocytic proliferative lesions. Histopathology 2004;44:517-41.
- 26 Onken MD, Worley LA, Char DH, et al. Collaborative Ocular Oncology Group report number 1: prospective validation of a multi-gene prognostic assay in uveal melanoma. Ophthalmology 2012;119:1596-603.

Tables

Table 1. Demographic and histopathologic characteristics of 31 patients with choroid and ciliary body melanoma

Patient characteristics		Number (%)
Age (years)	Median	63
	Average (range)	59.2 (29-85)
Age distribution (years)	<60	13 (42%)
	≥60	18 (58%)
Gender	Female	16 (52%)
	Male	15 (48%)
Histologic type	Spindle	7 (23%)
	Mixed	19 (61%)
	Epithelioid	5 (16%)
Largest tumor diameter	10-15 mm	14 (45%)
	15.1-18 mm	6 (19%)
	>18 mm	11 (36%)
Pigment	Low (<1/3 of the tumor)	9 (29%)
	Medium (<1/3 to 2/3 of the tumor)	21 (68%)
	High (>2/3 of the tumor)	1 (3%)
Ciliary body involvement	Yes	4 (13%)
	No	27 (87%)
Lymphocytic Infiltration	Present	6 (19%)
	Not present	25 (81%)
CD15 AEC	Positive (>10%)	3 (10%)
	Negative	27 (90%)
CD15 DAB	Positive (>10%)	6 (23%)
	Negative	20 (77%)
CD117 AEC*	Positive (>10%)	12 (39%)
	Negative	19 (61%)
CD117 DAB**	Positive (>10%)	14 (54%)
	Negative	12 (46%)
Survival	Alive	11 (36%)
	Dead	20 (64%)
	Alive + Dead (other causes)	14 (45%)
	Dead (uveal melanoma)	17 (55%)

* AEC - 3-amino-9-ethylcarbazole chromogen

* DAB - 3,3'-diaminobenzidine tetrahydrochloride chromogen

Table 2 Prognostic impact of CD117 AEC expression, tumor cell type (spindle, mixed and epithelioid), age, gender, lymphocytic infiltration and ciliary body involvement on disease-specific survival (Cox regression)

Variable	B	SE	HR	p	95% CI
CD117AEC	1,42	,59	4,13	,017	1,29 to 13,22
Spindle				,393	
Mixed	1,27	1,10	3,55	,251	0,41 to 31,00
Epithelioid	1,61	1,18	5,03	,172	0,49 to 50,99
Age	,04	,02	1,04	,048	1,00 to 1,09
Gender	-1,02	,69	,36	,137	0,09 to 1,38
Lymph inf*	,03	,74	1,03	,971	0,24 to 4,35
CB inv.**	,04	,91	1,04	,967	0,17 to 6,22

* Lymph - lymphocytic infiltration;

** CB inv. - ciliary body involvement

B - regression coefficient, SE - standard error of regression coefficient, HR - hazard ratio, 95% CI - 95% confidence intervals, p <0,05 indicates statistical significance

Figures

Figure 1 A case of choroidal melanoma, mixed cell type, haematoxylin-eosin staining (a) (original magnification x 400). Tumor cells show strong and diffuse expression of CD117 with DAB chromogen (b) (original magnification x 400)

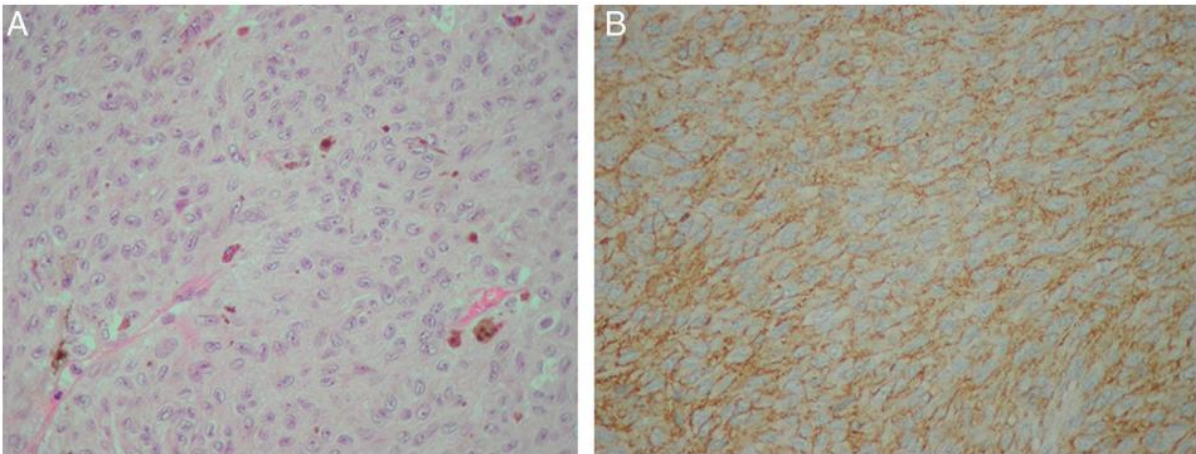


Figure 2 Kaplan-Meier estimates for overall (a) and disease-specific survival (b) of 31 patients with choroidal and ciliary body melanoma according to CD117 AEC positive (green line, N= 12) and CD117 negative (blue line, N=19) cases

