

Postoperative gastric perforation in a newborn with duodenal atresia

Antabak, Anko; Bogović, Marko; Vuković, Jurica; Grizelj, Ruža; Barbarić Babić, Vinka; Papeš, Dino; Luetić, Tomislav

Source / Izvornik: **Journal of Neonatal Surgery, 2016, 5, 62 - 62**

Journal article, Published version

Rad u časopisu, Objavljena verzija rada (izdavačev PDF)

<https://doi.org/10.21699/jns.v5i4.469>

Permanent link / Trajna poveznica: <https://urn.nsk.hr/urn:nbn:hr:105:867694>

Rights / Prava: [In copyright](#) / [Zaštićeno autorskim pravom.](#)

Download date / Datum preuzimanja: **2025-03-23**



Repository / Repozitorij:

[Dr Med - University of Zagreb School of Medicine
Digital Repository](#)



CASE REPORT

Postoperative Gastric Perforation in a Newborn with Duodenal Atresia

Anko Antabak,^{*1} Marko Bogović,¹ Jurica Vuković,² Ruža Grizelj,² Vinka Barbarić Babić,³
Dino Papeš,¹ Tomislav Luetić,¹

1 Department of Surgery, Clinical Hospital Center Zagreb, Zagreb, Croatia

2 Department of Pediatrics, Clinical Hospital Center Zagreb, Zagreb, Croatia

3 Department of Radiology, Clinical Hospital Center Zagreb, Zagreb, Croatia

How to cite: Antabak A, Bogović M, Vuković J, Grizelj R, Babić VB, Papeš D, et al. Postoperative gastric perforation in a newborn with duodenal atresia. J Neonat Surg. 2016; 5:62.

This is an open-access article distributed under the terms of the Creative Commons Attribution License, which permits unrestricted use, distribution, and reproduction in any medium, provided the original work is properly cited.

ABSTRACT

Gastric perforation (GP) in neonates is a rare entity with high mortality. Although the etiology is not completely understood, it mostly occurs in premature neonates on assisted ventilation. Combination of duodenal atresia and gastric perforation is very rare. We present a case duodenal atresia who developed gastric perforation after operation for duodenal atresia. Analysis of the patient medical record and histology report did not reveal the etiology of the perforation.

Key words: Gastric perforation; Neonate; Duodenal atresia

CASE REPORT

A one-day-old full-term male newborn, weighing 3400g, was admitted with suspicion of duodenal atresia due to history of polyhydramnios and antenatal ultrasound findings. An 8Fr nasogastric (NG) tube was inserted and prophylactic antibiotic (ceftriaxone) was initiated. A supine abdominal radiograph and contrast study revealed a double-bubble sign (Fig.1A). At laparotomy, the atresia was detected in the pre-ampullary region of the duodenum, and diamond-shaped duodeno-duodenostomy was performed. NG tube was passed across the anastomosis. Abdominal distension, tachypnea and respiratory distress occurred suddenly 24 hours after surgery. Abdominal radiography showed massive pneumoperitoneum. Emergent re-surgery found a linear tear (5 cm) along greater curvature of the posterior gastric wall (Fig.2A). The edges of the tear seemed very thin, as the muscular layer was missing. Perforation edges were excised until normal gastric wall was reached (approximately 1 cm from edge) and primary repair of the perforation was performed in two-layer

(Fig.2B). Further postoperative course was uneventful. Upper GI series performed after seven days (Fig.1B) was normal so NG tube was removed, breastfeeding was started, and he was discharged on the 14th postoperative day. Histological analysis of the excised perforation edges showed gastric wall necrosis.

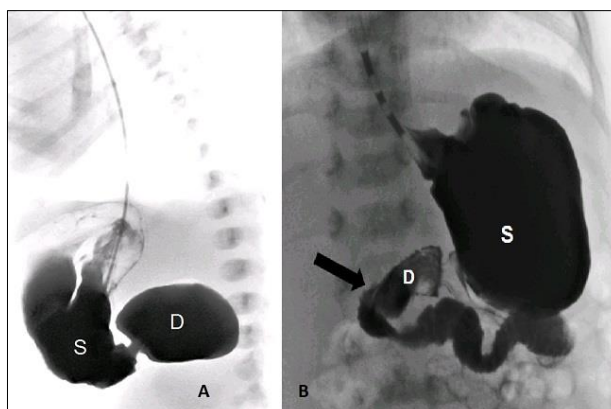


Figure 1: A) Contrast study showing duodenal atresia. B) Postoperative contrast study showing intact stomach and duodenal repairs.

Correspondence*: Prof. Anko Antabak, MD, PhD, Department of Surgery, Clinical Hospital Center Zagreb, Zagreb, Croatia, EU

E mail: aantabak@yahoo.com

Submitted: 03-09-2016

Conflict of interest: Nil

© 2016, Journal of Neonatal Surgery

Accepted: 03-09-2016

Source of Support: Nil

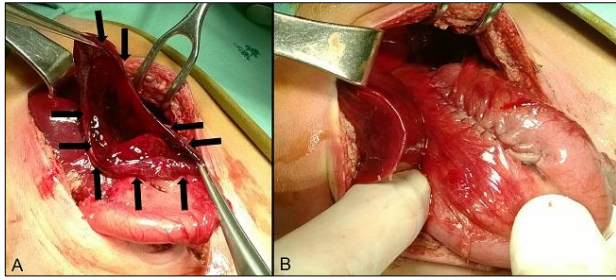


Figure 2: A) intraoperative view of the stomach rupture, B) after repair

DISCUSSION

Neonatal GP is a rare entity which requires prompt diagnosis and surgical intervention. The exact etiology of the condition is unclear, although various theories have been suggested including congenital absence of the muscular layer of stomach, increased intraluminal pressure due to distal obstruction by atresia, stenosis or bands, positive pressure mask ventilation during resuscitation, all have been proposed. Vigorous NG tube placement occasionally causes GP, which usually appears as a puncture wound or as a short tear. Prematurity and perinatal stresses are the most important risk factors for GP because of a possible low-perfusion state that leads to gastric wall injury. However, predisposing factors cannot be identified in around 20% of the patients [1-8]

Congenital duodenal atresia complicated by a GP is a very rare condition. According to a case report and literature review by Takebayashi, there were 12 reported cases of GP related to duodenal atresia, between 1940 and 1975, and one additional case was reported afterwards [9,10]. Only three of the reported 13 cases survived. In our patient, although the stomach had a wide perforation, generalized peritonitis was absent. Preoperative antibiotic use, early diagnosis of the GP and the pre-ampullary type of duodenal atresia might have prevented peritoneal irritation by pancreatic and bilious fluids. Our patient had two risk factors for the neonatal GP: duodenal obstruction and NG tube insertion. However, we do not believe that any of those had caused GP in our patient. The NG tube had a proper length and was placed under direct vision during the first surgery. In addition, the

perforation type was different than NG tube related perforation, which generally has a small diameter. Increased intra-gastric pressure due to distal obstruction too cannot stand as an etiology as the stomach was decompressed by NG tube.

To conclude, neonatal GP may occur after successful treatment of duodenal atresia without clear etiology. Revision surgery performed as soon as possible and intensive treatment is crucial for good outcome.

REFERENCES

1. Lin CM, Lee HC, Kao HA, Hung HY, Hsu CH, Yeung CY et al. Neonatal gastric perforation: report of 15 cases and review of the literature. *Pediatr Neonatol.* 2008;49:65-70.
2. Chouteau W, Green DW. Neonatal gastric perforation. *J Perinatol.* 2003;23:345-7.
3. Duran R, Inan M, Vatansever U, Aladag N, Acunaz B. Etiology of neonatal gastric perforations: review of 10 years' experience. *Pediatr Int.* 2007;49:626-30.
4. Leone RJ, Krasna IH. Spontaneous neonatal gastric perforation: is it really spontaneous? *J Pediatr Surg.* 2000;35:1066-9.
5. Ng PC, Brownlee KG, Dear PR. Gastroduodenal perforation in preterm babies treated with dexamethasone for bronchopulmonary dysplasia. *Arch Dis Child.* 1991;66:1164-6.
6. Terui K, Iwai J, Yamada S, Takenouchi A, Nakata M, Komatsu S, et al. Etiology of neonatal gastric perforation: a review of 20 years' experience. *Pediatr Surg Int.* 2012;28:9-14.
7. Lai S, Yu W, Wallace L, Sigalet D. Intestinal muscularis propria increases in thickness with corrected gestational age and is focally attenuated in patients with isolated intestinal perforations. *J Pediatr Surg.* 2014;49:114-9.
8. Ohshiro K, Yamataka A, Kobayashi H, Hirai S, Miyahara K, Sueyoshi N, et al. Idiopathic gastric perforation in neonates and abnormal distribution of intestinal pacemaker cells. *J Pediatr Surg.* 2000;35:673-6.
9. Takebayashi J, Asada K, Tokura K, Ookita A, Okuno M. Congenital atresia of the duodenum with gastric perforation. Case report and review of the literature. *Am J Dis Child.* 1975;129:1227-8.
10. Sajja SB, Middlesworth W, Niazi M, Schein M, Gerst PH. Duodenal atresia associated with proximal jejunal perforations: a case report and review of the literature. *J Pediatr Surg.* 2003;38:1396-8.