

# Contribution of forensic anthropology to identification process in Croatia: examples of victims recovered in wells

---

Šlaus, Mario; Strinović, Davor; Petrovečki, Vedrana; Vyroubal, Vlasta

Source / Izvornik: **Croatian Medical Journal, 2007, 48, 503 - 512**

Journal article, Published version

Rad u časopisu, Objavljena verzija rada (izdavačev PDF)

Permanent link / Trajna poveznica: <https://urn.nsk.hr/urn:nbn:hr:105:488230>

Rights / Prava: [In copyright](#) / [Zaštićeno autorskim pravom.](#)

Download date / Datum preuzimanja: **2025-01-14**



Repository / Repozitorij:

[Dr Med - University of Zagreb School of Medicine](#)  
[Digital Repository](#)



## Contribution of Forensic Anthropology to Identification Process in Croatia: Examples of Victims Recovered in Wells

Mario Šlaus<sup>1,2</sup>, Davor Strinović<sup>2</sup>, Vedrana Petrovečki<sup>2</sup>, Vlasta Vyrubal<sup>1</sup>

<sup>1</sup>Department of Archaeology,  
Croatian Academy of  
Sciences and Arts, Zagreb,  
Croatia

<sup>2</sup>Department of Forensic  
Medicine, Zagreb University  
School of Medicine, Zagreb,  
Croatia

**Aim** To describe the contribution of forensic anthropology to the recovery, analysis, and identification of victims from the 1991-1995 war in Croatia recovered in wells.

**Methods** From 1996 to the present, human remains of a total of 61 individuals have been recovered from 13 wells. Six wells contained the remains of a single individual, one well contained the remains of 2 individuals, and 6 wells contained the remains 3 or more individuals. The majority of wells, containing 90.2% (55/61) of recovered individuals, were located within a 4 km radius of the Croatian-Serbian border.

**Results** Forensic anthropologists re-individualized 26/61 (42.6%) individuals out of skeletonized and commingled remains, provided basic biological data on sex, age-at-death, and stature in all identifications (n = 37), as well as established positive identification by recognizing unique skeletal features (antemortem fractures and skeletal evidence of antemortem surgical interventions) in 3/37 (8.1%) cases. Trauma analyses carried out by forensic anthropologists contributed to the determination of the cause of death in 38/61 (62.3%) individuals and to the probable cause of death in an additional 18/61 (29.5%) individuals. The most frequent (27/38, 71.0%) type of trauma causing death in individuals recovered from wells was a single gunshot wound.

**Conclusion** Forensic anthropologists, collaborating closely with forensic pathologists, forensic odontologists, forensic radiologists, criminologists, and molecular biologists contributed significantly to trauma analysis and identification of war victims recovered from wells.

> **Correspondence to:**

Mario Šlaus  
Department of Archaeology  
Croatian Academy of Sciences and Arts  
Ante Kovačića 5  
10 000 Zagreb, Croatia  
[mario.slaus@zg.htnet.hr](mailto:mario.slaus@zg.htnet.hr)

> **Received:** March 15, 2007

> **Accepted:** June 1, 2007

> **Croat Med J. 2007;48:503-12**

To address the need for identification of a large number of war victims in the 1991-1995 war in Croatia (1-8), in 1991 the Croatian Government formed a multidisciplinary team of forensic experts with a purpose of recovering, analyzing, and identifying human remains from individual and mass graves. This report describes the contribution of forensic anthropologists to this endeavor, specifically to the recovery, analysis, and identification of 61 individuals recovered from 13 wells in Croatia after the 1991-1995 war. The recovery and analysis of these individuals was, for a number of reasons, considerably more complicated than the recovery and analysis of individuals from other types of mass graves and individual graves (1).

For obvious reasons, the recovery of human remains deposited in wells was more hazardous than the recovery of remains from other types of settings. Standard risks associated with this type of work are difficult access to the grave sites through mine fields, possible explosive devices hidden among the remains, and poorly preserved human remains. Besides this, recovery from wells was complicated by varying depth of the wells, problems pertaining to the draining off the wells, and – in the case of more dilapidated wells – the risk of collapse of the well walls. Trauma analyses and identification of the recovered individuals was hampered by problems such as poor preservation and commingling of the remains which were significantly more present in wells than in other types of settings (1).

The multidisciplinary team assembled by the Croatian government to recover and identify missing individuals included forensic pathologists, forensic anthropologists, forensic odontologists, forensic radiologists, criminologists, and molecular biologists. Forensic anthropologists contributed to this team effort by: 1) helping in locating and recovering human remains; 2) separating and re-individualizing commingled remains; 3) interpreting skeletal evidence of trauma – identifying the presence of trauma, differentiating between antemortem, postmor-

tem, and perimortem trauma, as well as establishing the sequence of perimortem traumas, when possible; and 4) adopting an osteo-biographical approach in order to supply not only basic data on the age-at-death, sex, and stature, but also on other biological characteristics potentially useful in the identification process. To facilitate this, a joint US-Croatian forensic anthropology project was developed. In this project, forensic anthropologists from the Croatian Academy of Sciences and Arts and forensic specialists from the Department of Forensic Medicine at the School of Medicine, University of Zagreb, together with forensic anthropologists from the Smithsonian Institution, Washington DC, USA and the University of Tennessee in Knoxville developed a forensic anthropology database. Data on sex, age-at-death, stature, cranial and postcranial metric characteristics, and osteological and dental features were collected, including the evidence on pathology, ante-mortem fractures, disease, and surgical interventions, as well as perimortem trauma and possible cause of death. The purpose of this database was 3-fold: 1) to identify a basic and standard set of measurements, observations, and definitions to ensure that data are comparable; 2) to store the data in a computer so that particular subsets can be quickly accessed, analyzed, and compared; and 3) to provide up-to-date discriminant formulae for determining sex, stature, and other traits useful for comparative research and forensic analysis. The data gathered so far have already been proved useful for calculating discriminant functions for determining sex from fragmentary and complete Croatian femora (3), estimating male stature from the maximum lengths of the humerus, femur, and tibia (9), as well as determining craniometric relationships between Americans (Caucasians), Croatians, and Bosnians (10).

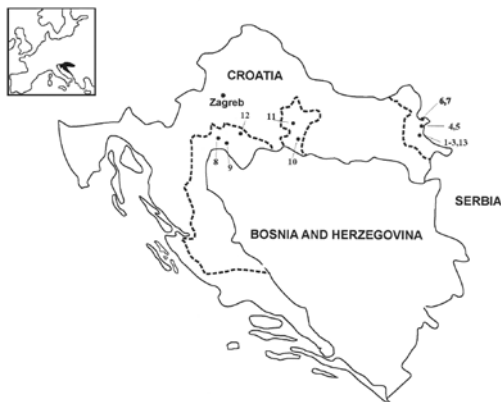#### Materials and methods

Recovery of victims' remains deposited in wells was the most difficult type of recovery encoun-

tered by the identification team. From 1996 to 2001, human remains were recovered from 13 wells that contained a total of 61 individuals. Detailed comparison between human remains recovered in wells and non-well settings was previously described (1). The sources of information on wells with human remains were the surviving family members, relatives, and neighbors, as well as various anonymous sources. Table 1 shows the number of individuals recovered from each well and their current identification status. The geographical location of the wells is shown in Figure 1. As can be seen, 8/13 wells, including 6 wells containing more than 3 individuals, were locat-

**Table 1.** Number of victims from Croatian 1991-1995 war recovered from wells and their current identification status

Well	Current status		Total
	unidentified	identified	
Borovo-Lovački Dom		3	3
Borovo Selo	1		1
Čakovci	2	4	6
Dalj-Planina		1	1
Daljski Atar	6	17	23
Erdut-Dun. Ulica	7		7
Erdut-Žarkovac	4		4
Gredjani	1		1
Gvozd		1	1
Okučani	1	1	2
Pakrac		1	1
Petrinja		1	1
Vukovar-Ul. Nova	2	8	10
Total	24	37	61



**Figure 1.** Geographical locations of the 13 analyzed wells: 1. Borovo-Lovački Dom, 2. Borovo Selo, 3. Čakovci, 4. Dalj-Planina, 5. Daljski Atar, 6. Erdut-Dunavska Ulica, 7. Erdut-Žarkovac, 8. Gredjani, 9. Gvozd, 10. Okučani, 11. Pakrac, 12. Petrinja, 13. Vukovar-Ulica Nova. Dotted lines show the parts of Croatia temporarily occupied from 1991 to 1995.

ed in the immediate vicinity of the Croatian-Serbian border. The sites Borovo-Lovački Dom, Borovo-Selo, Čakovci, Dalj-Planina, Daljski Atar, Erdut-Dunavska Ulica, Erdut-Žarkovac, and Vukovar-Ulica Nova were all within a 4 km radius of the border. These 8 sites also contained the majority (55/61 or 90.2%) of the recovered individuals. In contrast to this, most of the wells with one individual (4/6), and a single well with 2 individuals were located 150 or 200 km to the west, in other temporarily occupied parts of Croatia. The reasons for this discrepancy are at present unclear.

The wells in the immediate vicinity of the Croatian-Serbian border were deeper than those located in the western counties. These wells were between 11-20 m deep, while the remaining wells, with the exception of the Pakrac well, were between 8-12 m deep. The Pakrac well, 31 m deep, was the deepest well where the recovery of human remains took place. All of the wells had similar diameters, between 2 to 3 m. Slightly more than a half (7/13) of the wells had been used as reservoirs of drinking water, 4 were dry, and 2 contained small amounts of non-drinking water useable for agricultural (Daljski Atar) or other (Čakovci) purposes. Five wells were located on private estates in backyards, orchards, or gardens, while 8 wells were in common use.

Besides human remains, all wells contained large amounts of garbage: debris from destroyed houses, earth, bricks, broken appliances, furniture, and automobile and engine-parts. In all wells, except in Daljski Atar and Erdut-Žarkovac, the bodies were distributed in one layer at the deepest stratum of the well, with garbage thrown on top, presumably in an attempt to hide the bodies or disable access to them.

In Daljski Atar, which in several important features differed from the other wells, the bodies were distributed in two layers. The deeper layer (at a depth of approximately 14 m) was covered by a layer of garbage about 1.5 m deep, on which the second layer of bodies was laid down.

These bodies were also covered with garbage that filled the well to the depth of approximately 5 m. Some of the garbage used to cover the bodies seems to have come from an auto mechanic garage or store. It consisted of broken automobile parts, elements of automobile chassis, and engine parts. This is interesting because the Daljski Atar well is located in a large field, 1 km from the nearest road, 4 km from the nearest farm, and 6 km from the outskirts of Dalj village. The nearest auto mechanic garage is located 25 km south, in Vukovar. The well was used exclusively for agricultural purposes, ie watering the fields and providing water to grazing cattle. The two separated layers of bodies and the large amount of individuals recovered suggest that this well may have been used as a receptacle of bodies on more than one occasion.

The other exception is the Erdut-Žarkovac well, which contained the remains of 4 individuals. Three of the individuals were partially skeletonized and one was saponified. The recovered human remains were almost completely disarticulated, extensively commingled, and evenly dispersed together with earth, branches, and general debris, all over the entire depth of the well. Among the recovered garbage remains of several badly burned army ammunition boxes were found. It appears that these boxes, containing mines or ammunition, were placed on top of the bodies and that some type of explosive device was used to detonate them, resulting in extensive destruction and commingling of the remains.

Unexploded explosive devices were recovered from two wells. Several unexploded hand grenades and an unexploded 82 mm mortar shell was found in the Pakrac well and an unexploded tromblone shell (Figure 2) in the Vukovar-Ulica Nova well. The shell was placed on top of the bodies and under the debris, and everything was covered by garbage.

Three of the wells contained animal remains. The Borovo-Lovački Dom contained skeletonized and partially preserved remains of sever-



Figure 2. Unexploded tromblone shell recovered from the Vukovar-Ulica Nova well.

al sheep, the Erdut-Dunavska Ulica contained a well preserved dog skeleton placed on top of human remains, and the Čakovci well contained skeletonized remains of several sheep and saponified remains of a dog and a pig.

Because of these factors, the recovery of human remains from wells was carried out carefully and deliberately, with maximum emphasis on the safety of the recovery team.

The recovery team consisted of members of the Committee for Imprisoned and Missing Individuals, local law-enforcement and judiciary personnel, local police, and members of the identification team. Two professional well diggers also offered their services and were crucial for the recovery of the remains.

Before the beginning of the recovery, some wells needed to be drained by pumps. Depending on the amount of water present, the process sometimes lasted several hours and sometimes draining was carried out during the recovery process. The most complicated and potentially dangerous conditions were encountered in the Čakovci well, where, after the removal of the debris covering the bodies, the walls of the well began collapsing and water flooded in. Besides pumps, buckets were also employed to dry out the well, but the recovery team ended up working in water up to their waist.

Once the wells were dry, two types of recovery procedures were employed. In the first two recoveries – the Petrinja and Okučani wells,

backhoes were used to remove the earth from one side of the well. When a sufficient depth was achieved, the wall of the well was perforated and recovery of the bodies was carried out. This procedure, however, was not only very costly and time consuming but increased the risk of collapse of the well walls. Furthermore, while this procedure could be attempted when wells were relatively shallow (the Petrinja and Okučani wells were approximately 8-9 m deep), it was clearly impractical in deeper wells. A different procedure was, therefore, used to recover human remains from these wells. In this procedure, a pulley was constructed above the entrance to the well and one of the professional well diggers was slowly lowered by a rope into the well (Figure 3). The material from the wells was placed into buckets and then pulled to the surface. All of the buckets were numbered and recovery proceeded according to layers.



Figure 3. Simple pulley constructed above the entrance to the Čakovci well.

Because the time between death and recovery of the bodies was between 4-14 years, some of the remains were completely skeletonized and commingled. As each body was recovered, it was assigned a location name and number. In cases of extensive commingling, all of the remains were removed together as a single layer, given a series of numbers based on a probable number of individuals present, and sent to the Department of Forensic Medicine in Zagreb for re-individualization (Figure 4). All attempts were made to



Figure 4. Recovery of human remains from the Vukovar-Ulica Nova well. All of the recovered individuals were skeletonized or partially skeletonized and extensively commingled. Arrows point to gunshot wounds.

recover as much of the human and material remains as possible.

A forensic anthropologist was present at all autopsies. Criteria used to determine sex, age-at-death, and stature in adults and subadults, as well as the condition of the recovered remains, were reported previously (1).

## Results

About half (33/61) of the recovered remains were completely or partially skeletonized. A breakdown of the analyzed sites (Table 2) showed that skeletonization and the resulting commingling of remains was most prevalent in the Čakovci, Vukovar-Ulica Nova, Erdut-Dunavska Ulica, and Borovo-Lovački Dom wells. The highest rate of preservation was recorded in

Table 2. State of the remains of victims from Croatian 1991-1995 war recovered from wells

Well	No. of recovered remains			Total
	skeletonized	partially skeletonized	saponified	
Borovo-Lov. Dom	3			3
Borovo Selo	1			1
Čakovci	6			6
Dalj-Planina			1	1
Daljski Atar		3	20	23
Erdut-Dun. Ulica	4		3	7
Erdut-Žarkovac		1	3	4
Gredjani	1			1
Gvozd		1		1
Okučani	2			2
Pakrac	1			1
Petrinja			1	1
Vukovar-Ul. Nova	6	4		10
Total	24	9	28	61

the Daljski Atar well where 20 of 23 recovered individuals (86.9%) were saponified.

Commingling of remains was present in 26/61 of the recovered bodies. In wells where commingling had occurred, forensic anthropologists re-individualized the remains based on compatibility in sex, age-at-death, bone length, robustness, muscle crest development, joint surface articulations, and variations in taphonomic features. Approximately two thirds (40/61) of the recovered individuals were well-preserved (1) and this facilitated the re-individualization process. Age and sex distribution in some wells also helped. For instance, in the Borovo Lovački Dom well, there were 3 completely skeletonized and commingled individuals – a woman aged 20 years, a woman aged 50 years, and a man aged 31 years. The greatest difficulties were encountered in the Čakovci well where 6 adult men, all between 20 to 50 years were commingled, and in the Erdut Dunavska Ulica well where 4 men aged between 18-35 years were commingled. Differences in age, bone length, robustness and muscle crest development, and taphonomic features were, however, sufficient to re-individualize all of the recovered individuals. Preserved clothing, in some cases up to 5 layers, including coats, waistcoats, jerseys, jackets, sweaters, shirts, trousers, and different types of footwear also facilitated the process of re-individualization since they were holding ribs, vertebrae, and the bones of the feet together. The bones of the hands could rarely be re-individualized.

Sex distribution and mean age-at-death of 37 identified individuals is reported by Šlaus et al (1). In both men and women, most of the identified individuals were between 51 to 60 years old – 6/12 women and 11/25 men (Table 3). The oldest identified individuals were between 76 to 80 years old – 2 women and 1 man. Four individuals – 3 men and 1 woman – were younger than 20 years. Age distribution (24/37 were either younger than 21 or older than 51 years) indicated a high ratio of civilians in the sample.

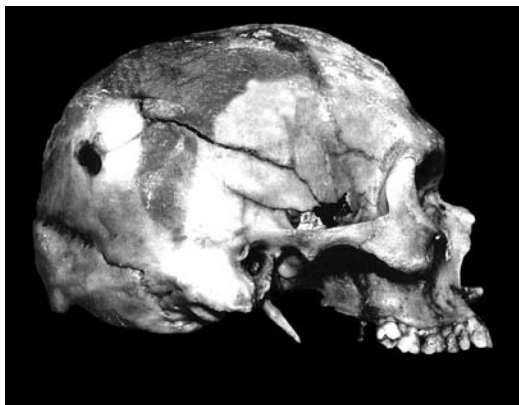
**Table 3.** The age and sex distribution of the identified victims from Croatian 1991-1995 war recovered from wells

Age category (years)	No. of identified victims		total
	female	male	
11-15		1	1
16-20	1	2	3
21-25		2	2
31-35		4	4
36-40	1	1	2
41-45	1	1	2
46-50	1	2	3
51-55	3	4	7
56-60	3	7	10
76-80	2	1	3
Total	12	25	37
Age-at-death (mean±SD)	53.6 ± 15.6	44.0 ± 16.6	47.1 ± 16.7

Age and sex distribution in different wells showed that the well in Daljski Atar differed significantly from other wells. Seventeen identified individuals from the Daljski Atar well (12 men and 5 women) had mean ± standard deviation age-at-death of  $56.9 \pm 10.32$  years. Identified individuals from other 8 wells (13 men and 7 women) had mean ± SD age-at-death of  $38.7 \pm 16.8$  years. Identified individuals from the Daljski Atar well were, therefore, on average 18.19 years older than the individuals recovered from other wells. This difference was significant, according to pooled *t* test (pooled *t* test  $t = 3.883$ ;  $df = 35$ ; two-tailed  $P < 0.001$ ).

The types of trauma recorded in the recovered remains included injuries resulting from gunshots, shrapnel, and blunt force trauma. Because of severe peri- and postmortem damage, forensic anthropologists frequently had to reconstruct shattered bones to determine and distinguish between different traumatic injuries. Most of the recovered individuals had more than one trauma, as was the case in the Erdut-Dunavska Ulica.

In Erdut-Dunavska Ulica, a well-preserved skeleton of a still unidentified male aged between 25-35 years was found. The skull was complete, except for the lower face that was fragmented but could be reconstructed. Three perimortem traumas were identified in the cranium. One of them was blunt force trauma applied to the right parietal bone that produced a fracture extending

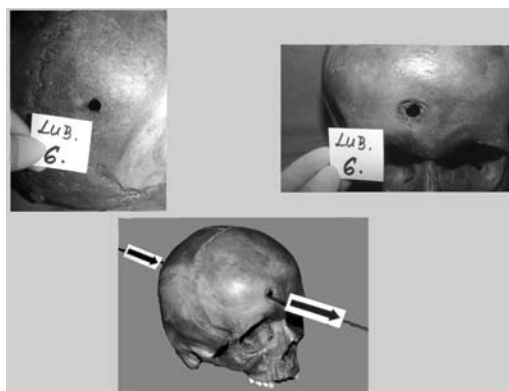


**Figure 5.** Skull of an adult male recovered from the well in Erdut-Dunavska Ulica. The skull exhibits blunt force trauma to the right parietal, temporal, and sphenoid bones, and two joined gunshot entry wounds in the posterior right parietal.

from approximately the middle of the sagittal suture into the right temporal and posterior right sphenoid bone (Figure 5). The fracture terminated in an oblong (approximately 30×10 mm) defect. Two joined gunshot entry wounds in the shape of the number “8” were located in the posterior right parietal bone. The wounds were approximately 35 mm superior of the lambdoid suture and 65 mm lateral of the sagittal suture. Both components exhibited internal beveling and light flaking of the outer table. Each component was approximately 7 mm in diameter. Two exit wounds were present. One was in the left frontal bone and superior part of the left orbit, producing a defect approximately 55×45 mm with prominent external beveling. The other was in the left parietal bone, approximately 70 mm from the sagittal suture, and produced a 10×15 mm defect with prominent external beveling. A fracture line extended from the entry wounds to the right parietal bone fracture, but did not cross the fracture line, indicating that the blunt force trauma occurred first, prior to two gunshot wounds through the back of the head. The possible caliber of the weapon was 7.62 mm.

Another example of gunshot trauma to the head was noted in an individual from the Vukovar-Ulica Nova well. This 16-year-old male exhibited an entry wound in the posterior right

parietal approximately 37 mm superior from lambda and 28 mm lateral from the sagittal suture (Figure 6). The wound had a diameter of approximately 7 mm and exhibited internal beveling and light flaking of the outer table. The exit wound was located approximately in the midline of the frontal bone, 30 mm superior of the nasion and was characterized by prominent external beveling and a circular defect, 17 mm in diameter.



**Figure 6.** Skull of a 16 years old male recovered from the well in Vukovar-Ulica Nova with entrance gunshot wound in the posterior part. The diameter of the entrance wound suggests that the caliber of the murder weapon was 7.62 mm.

Traumas of different types were recorded in 59/61 recovered individuals. Only 2 individuals did not exhibit evidence of trauma. One was a 50 years old man recovered from the Čakovci well. The remains were completely skeletonized and well-preserved, but a careful analysis of the bones showed no evidence of trauma. The other was a 79-year-old woman recovered from the Petrinja well. Her remains were saponified and wrapped in a blanket. The body was tightly tied with a rope around the waist, which left deep marks. The other end of the rope was tied to a large stone. No traumas were noted. This finding strongly suggested that the cause of death was drowning.

The cause of death was determined in 38/61 individuals, probable cause in 18/61 individuals, while in 5/61 individuals the cause of death could not be determined.



In 38 individuals in whom the cause of death was determined, the most frequent (27/38) type of trauma causing death was a single gunshot wound. Other types of traumas causing death included multiple gunshot wounds (6/38), shrapnel injuries (4/38), and blunt force trauma with one or more gunshot wounds (1/38).

## Discussion

Our principal objective was the identification of recovered individuals, requiring joint efforts of different specialists – forensic pathologists, forensic anthropologists, forensic radiologists, forensic odontologists, and molecular biologists. Forensic anthropologists contributed to this collaborative effort by adopting an osteo-biographical approach and supplying not only basic data on age-at-death, sex, and stature, but also data on personal biology as reflected in skeletal material.

These data were crucial for the identification process for two reasons. First, basic biological data on sex, age-at-death, and stature were essential for narrowing down the range of possible matches in cases where positive identification was established by forensic DNA testing, through comparisons with the existing dental records, or as additional conformation in cases where identification was established through recovered personal documents, jewelry, or artifacts. Second, osteological evidence of antemortem trauma and surgery, when confirmed through interviews with surviving family members, was crucial for establishing positive identification. Four individuals recovered from the Vukovar-Ulica Nova well provide an example of the contribution of forensic anthropology to the identification process.

Several lines of evidence suggested that a family of four was present among the individuals recovered from the Vukovar-Ulica Nova well. The family consisted of a husband, wife, and two sons – 12 and 16 years old. The analysis of the recovered remains ( $n=10$  individuals) indicated the

presence of two subadults. Based on dental development (11), diaphyseal lengths, and epiphyseal closure (12), the age-at-death for these individuals was estimated to be between 9-13 and 14-18 years. These remains were the possible matches. The younger individual was not old enough for an accurate determination of sex, based on skeletal morphology. However, the clothing in which he was recovered looked like a clothing of a young boy and subsequently matched the description of the clothing in which the boy had last been seen. Dental criteria – specifically the presence of 2 amalgam fillings in the mandible also corresponded to data reported in the questionnaire. Several small toys, including a metal model of a racing car and 7 hard plastic figures were recovered from the trouser pockets. These were later recognized by relatives.

The sex of the older subadult was recognized as male based on cranial and pelvic morphology (13). This individual had bilateral well-developed muscle attachment sites for the deltoid and pectoral muscles on the humeri, a shallow benign cortical defect at the attachment site of the biceps brachii muscle on the right proximal radius, and bilateral shallow rhomboid fossae on the medial clavicles. These findings were compatible with data supplied by relatives and neighbors who informed us that the missing boy was a promising athlete who trained in the local football club and regularly lifted weights. Clothing associated with the remains also matched data from the questionnaire, as did the presence of 3 amalgam fillings in the maxilla. Both subadults also exhibited spondylolysis of the fifth lumbar vertebra. Although the etiology of this condition remains unresolved, genetic factors must be considered (14). Spondylolysis is present in about 6% of the Croatian population (14) and its presence in both recovered subadults provided additional support for a genetic relationship between them.

Data gathered for the father indicated that he was a 43-year-old man, who earlier in his life

had had an automobile accident in which he had broken his left leg and right clavicle. He was reported to have considerable antemortem tooth loss but no dentures. One of the recovered individuals matched this description. The sex of this individual was recognized as male based on pelvic and cranial morphology. The age-at-death was estimated to be between 35-45 years, based on pubic symphysis morphology (15,16), auricular surface morphology (17), and the Lamendin dental age protocol (18). Additional evidence for this age range was the presence of mild osteophytes on the ventral surfaces of the superior end plates of 4 thoracic vertebrae, and the bilateral presence of slight osteoarthritis (marginal osteophytes) on the glenoid fossae. This individual exhibited 3 healed fractures. The first was a well-healed fracture of the right clavicle. The bone was 17 mm shorter than the left clavicle and noticeably thicker – the result of healed osteomyelitis. The second and third fractures were located on the left tibia and fibula. The left tibia exhibited a large callus with no angulation or signs of infection. No shortening was noticed when both tibias were compared. The left fibula was also fractured antemortem with slight overriding that resulted in a 9 mm shortening of the bone. The dental status of the recovered individual also matched the missing father – there were 4 antemortem tooth extractions in the maxilla and 8 extractions in the mandible.

The mother was hardest to identify. Data from the questionnaire indicated that she was a 40-year-old woman, mother of two children, with a stature of approximately 160 cm. She had two antemortem tooth extractions in the maxilla and several amalgam fillings in the mandible. Five females were recovered from the Vukovar-Ulica Nova well. Four were aged between 35-50 years and therefore represented possible matches. One of these individuals was tentatively excluded, as she was a relatively tall woman with a maximum femoral length of 471 mm. According to the regression formula of Petrovečki et al

(19), this individual had an estimated stature between 167.5-176.3 cm. One of the remaining three candidates, besides fitting in the age range and general stature estimate, exhibited a metopic suture on the frontal bone. Normally, this suture, which separates the frontal bone down the midline in children, begins to obliterate at the end of the first year, with complete fusion usually not later than the fourth year (20). In some individuals, however, the two frontals fail to unite, resulting in a persistent metopic suture from the nasion to bregma, usually referred to as a *sutura metopica persistens*. The frequency of this suture is between 1.75%-3.4% (21-24), and varies in different populations, indicating some sort of genetic basis. This finding was important because the younger subadult also exhibited a metopic suture. Attention was, therefore, shifted to this female. The analysis of dental remains was inconclusive because of extensive perimortem damage, but subsequent forensic DNA testing confirmed that the remains did indeed belong to the missing mother.

The analysis of the factors responsible for positive identification showed that data on sex, age-at-death, and stature contributed to all positive identifications ( $n=37$ ). Osteo-biographical data on degenerative changes, in conjunction with supporting reports from surviving family members, helped to confirm the identification in 6/37 of individuals. Encountered degenerative changes included severe spinal osteophytosis that fused several vertebrae into blocks, severe degenerative joint disease that included severe marginal osteophytes, macroporosity of the joint surface, and/or joint surface eburnation. Corroborated by family members, healed antemortem fractures made identification possible in 2/37 cases and skeletal evidence of antemortem surgical interventions in 1/37 cases.

In conclusion, forensic anthropologists, collaborating closely with forensic pathologists, forensic odontologists, forensic radiologists, criminologists, and molecular biologists, contributed

significantly to the analysis and identification of victims of the 1991-1995 war in Croatia recovered from wells. Forensic anthropologists re-individualized 26/61 of the recovered bodies and contributed significantly to trauma analyses by reconstructing shattered bones, differentiating between antemortem, postmortem, and perimortem trauma, and establishing the sequence of perimortem traumas, when possible.

Forensic anthropologists also provided basic biological data on sex, age-at-death, and stature in all identifications, and established positive identification by identifying unique skeletal features (antemortem fractures and skeletal evidence of antemortem surgical interventions) in 3/37 cases.

#### Acknowledgment

This study was financially supported by the Ministry of Science, Education, and Sport of the Republic of Croatia (Grants No. 101-197-0677-0670 and 108-0000000-0030).

#### References

- Šlaus M, Strinović D, Pećina-Šlaus N, Brkić H, Baličević D, Petrovečki V, et al. Identification and analysis of human remains recovered from wells from the 1991 War in Croatia. *Forensic Sci Int*. 2007.
- Andelinović S, Sutlovic D, Erceg Ivković I, Skaro V, Ivković A, Paic F, et al. Twelve-year experience in identification of skeletal remains from mass graves. *Croat Med J*. 2005;46:530-9. [Medline:16100755](#)
- Šlaus M, Strinović D, Skavac J, Petrovečki V. Discriminant function sexing of fragmentary and complete femora: standards for contemporary Croatia. *J Forensic Sci*. 2003;48:509-12. [Medline:12762518](#)
- Jurčević S, Urlić I. Linking objects in the process of mourning for sons disappeared in war: Croatia 2001. *Croat Med J*. 2002;43:234-9. [Medline:11885053](#)
- Huffine E, Crews J, Kennedy B, Bomberger K, Zinbo A. Mass identification of persons missing from the break-up of the former Yugoslavia: structure, function, and role of the International Commission on Missing Persons. *Croat Med J*. 2001;42:271-5. [Medline:11387637](#)
- Brkić H, Strinović D, Šlaus M, Skavac J, Zečević D, Milicević M. Dental identification of war victims from Petrinja in Croatia. *Int J Legal Med*. 1997;110:47-51. [Medline:9168318](#)
- Primorac D, Andelinović S, Definis-Gojanović M, Drmić I, Rezić B, Baden MM, et al. Identification of war victims from mass graves in Croatia, Bosnia, and Herzegovina by use of standard forensic methods and DNA typing. *J Forensic Sci*. 1996;41:891-4. [Medline:8789853](#)
- Definis-Gojanović M, Ivanović J, Drmić I, Galić M, Andelinović Š. Identification of fifty-nine victims of the war from the Kupres battlefield, Bosnia and Herzegovina. *Croat Med J*. 1995;36:61-4.
- Ross AH, Konigsberg LW. New formulae for estimating stature in the Balkans. *J Forensic Sci*. 2002;47:165-7. [Medline:12064645](#)
- Ross AH, Jantz RL, Owsley DW, Cihlarz Z, Vedo T, Šlaus M, et al. Cranial variation among American Whites, Croatians and Bosnians. *Proceedings of the American Academy of Forensic Sciences*; 1999 Feb 15-20; Orlando (FL). Colorado Springs (CO): American Academy of Forensic Sciences; 1999.
- Moorrees CF, Fanning EA, Hunt EE. Age variation of formation stages for ten permanent teeth. *J Dent Res*. 1963;42:1490-502. [Medline:14081973](#)
- Bass WM. *Human osteology. A laboratory and field manual of the human skeleton*. 3rd ed. Columbia (MO): Missouri Archaeological Society; 1987.
- Krogman WM, İşcan MY. *The human skeleton in forensic medicine*. 2nd ed. Springfield (IL): Charles C. Thomas; 1986.
- Pećina M, Bojanić I. *Overuse injuries of the musculoskeletal system*. 2nd ed. Boca Raton (FL): CRC Press; 2003.
- Brooks S, Suchey JM. Skeletal age determination based on the os pubis: A comparison of the Acsádi-Nemeskéri and Suchey-Brooks methods. *Human Evolution*. 1990;5:227-38.
- Todd TW. Age changes in the pubic bone. I: The white male pubis. *Am J Phys Anthropol*. 1920;3:285-334.
- Lovejoy CO, Meindl RS, Pryzbeck TR, Mensforth RP. Chronological metamorphosis of the auricular surface of the ilium: a new method for the determination of adult skeletal age at death. *Am J Phys Anthropol*. 1985;68:15-28. [Medline:4061599](#)
- Lamendin H, Baccino E, Humbert JF, Tavernier JC, Nossintchouk RM, Zerilli A. A simple technique for age estimation in adult corpses: the two criteria dental method. *J Forensic Sci*. 1992;37:1373-9. [Medline:1402761](#)
- Petrovečki V, Meyer D, Šlaus M, Strinović D, Skavac J. Prediction of stature based on radiographic measurement of cadaver long bones: a study of the Croatian population. *J Forensic Sci*. 2007;52:547-52. [Medline:17456080](#)
- Scheuer L, Black S. *Developmental juvenile osteology*. San Diego (CA): Academic Press; 2000.
- Baaten PJ, Haddad M, Abi-Nader K, Abi-Ghosn A, Al-Kutoubi A, Jurjus AR. Incidence of metopism in the Lebanese population. *Clin Anat*. 2003;16:148-51. [Medline:12589670](#)
- del Sol M, Binvignat O, Bolini PD, Prates JC. Metopism in Brazilians [in Portuguese]. *Rev Paul Med*. 1989;107:105-7. [Medline:2629053](#)
- Ajmani ML, Mittal RK, Jain SP. Incidence of the metopic suture in adult Nigerian skulls. *J Anat*. 1983;137:177-83. [Medline:6630031](#)
- Agarwal SK, Malhotra VK, Tewari SP. Incidence of the metopic suture in adult Indian crania. *Acta Anat (Basel)*. 1979;105:469-74. [Medline:552786](#)