

The modification of rotation - advancement flap made in 1950

Knežević, Predrag; Vuletić, Marko; Blivajs, Igor; Dediol, Emil; Macan, Darko; Virag, Mišo

Source / Izvornik: **Acta Stomatologica Croatica, 2017, 51, 60 - 64**

Journal article, Published version

Rad u časopisu, Objavljena verzija rada (izdavačev PDF)

<https://doi.org/10.15644/asc51/1/8>

Permanent link / Trajna poveznica: <https://urn.nsk.hr/urn:nbn:hr:105:451334>

Rights / Prava: [In copyright](#) / [Zaštićeno autorskim pravom.](#)

Download date / Datum preuzimanja: **2024-07-14**



Repository / Repozitorij:

[Dr Med - University of Zagreb School of Medicine
Digital Repository](#)



Predrag Knežević¹, Marko Vuletić², Igor Blivajs³, Emil Dediol¹, Darko Macan¹, Mišo Virag⁴

Modifikacija klizno-rotirajućeg reznja napravljenog 1950. godine

The Modification of Rotation - Advancement Flap Made in 1950

- ¹ Stomatološki fakultet Sveučilišta u Zagrebu – Zavod za oralnu i maksilofacijalnu kirurgiju Kliničke bolnice Dubrava, Zagreb, Hrvatska
School of Dental Medicine, University of Zagreb, Department of Oral and Maxillofacial Surgery, University Hospital Dubrava, Zagreb, Croatia
- ² Privatna ordinacija, Sisak, Hrvatska
Private practice, Sisak, Croatia
- ³ Zavod za oralnu i maksilofacijalnu kirurgiju Kliničke bolnice Dubrava, Zagreb, Hrvatska
Department of Oral and Maxillofacial Surgery, University Hospital Dubrava, Zagreb, Croatia
- ⁴ Medicinski fakultet Sveučilišta u Zagrebu – Zavod za oralnu i maksilofacijalnu kirurgiju Kliničke bolnice Dubrava, Zagreb, Hrvatska
Professor, DM, MSc, PhD at the School of Medicine, University of Zagreb, Department of Oral and Maxillofacial Surgery, University Hospital Dubrava, Zagreb, Croatia

Sažetak

Rane tehnike zatvaranja rascjepa usne uključuju linearnu ili druge oblike geometrijskih linija (trokutasta ili četvrtasta zatvaranja). Prekretnica u operaciji rascjepa usana počela je 1955. godine kada je, na Prvom međunarodnom kongresu za plastičnu kirurgiju u Stockholmu, dr. Millard predstavio svoju metodu – klizno-rotirajuću tehniku ili režanj. Danas tu tehniku diljem svijeta, s modifikacijama ili bez njih, primjenjuje više od 85 posto kirurga za rascjepe. Predstavljamo pacijenta s potpunim jednostranim rascjepom usne i nepca koji je operiran prije šezdeset i pet godina. Ožiljak na usni sličan je klizno-rotirajućoj liniji. Plastiku usne obavio je profesor Šercer 1950., pet godina prije Millardove publikacije. Profesor Ante Šercer međunarodno je poznat otorinolaringolog iz Hrvatske. Ističe se njegov značajan doprinos operaciji velofaringealne insuficijencije i plastičnoj kirurgiji nosa i uha.

Zaprimljen: 14. studenoga 2016.
Prihvaćen: 13. veljače 2017.

Adresa za dopisivanje

Marko Vuletić, dr. med. dent.
Privatna ordinacija, Žitna 8,
44 000 Sisak, Hrvatska
tel: +385 44 531 004
faks: +385 44 531 004
vulesk@gmail.com

Ključne riječi

rascjep usne; ožiljak; kirurški režanj;
operativna tehnika; plastična kirurgija

Uvod

Rane tehnike zatvaranja rascjepa usne uključuju linearnu ili druge oblike geometrijskih linija (trokutasta ili četvrtasta zatvaranja). Godine 1843. Malgaigne je opisao metodu za zatvaranje rascjepa usne lokalnim reznjem, a navedena godina smatra se početkom plastične kirurgije kad je riječ o rascjepu usne. Iduće godine Mirault prilagođava Malgaigneovu tehniku s bočnim reznjem preko rascjepa. Sve sljedeće tehnike zatvaranja rascjepa usne uglavnom su se temeljile na ovom principu (1). Prvi linearni popravak usne učinio je Ambroise Pare (1568.). W. Rose je 1879. zagovarao zakrivljen rez koji je uključivao parni dizajn reza koji se pruža od dna nosa do granice vermilion. LeMesurier je 1945. ponovno predstavio geometrijsku tehniku popravka usne na temelju Hagerdonova opisa iz 1892. godine, lateralno baziranu na četverokutnom reznju usne. Tennisonov režanj za popravak, koji je uključivao trokutasti režanj s donjeg lateralnog dijela usne, modificirao je Randall 1959. (1, 2).

Prekretnica u operaciji rascjepa usana dogodila se na Prvom međunarodnom kongresu za plastičnu kirurgiju u Stockholmu 1955. godine, kada je dr. Millard predstavio vla-

Introduction

The early techniques of cleft lip repair involved a straight-line or some kind of geometric line (triangular, quadrangular closure). In 1843, Malgaigne described the cleft lip closure method with local flaps and that year was considered to be the beginning of plastic surgery of the cleft lip. The following year, Mirault modified Malgaigne's technique with a lateral flap across the cleft. All future methods of cleft lip closure have been based on Mirault's principle (1). The first straight line lip repair was performed by Ambroise Pare in 1568. W. Rose advocated curved incision, which included paired incision design that extended from the nasal floor to the vermilion border in 1879. In 1945, LeMesurier reintroduced the geometric lip repair technique, based on Hagerdon's description from 1892, of a laterally based quadrangular lip flap. The Tennison flap repair, which included a triangular flap from the inferior part of the lateral lip, was modified by Randall in 1959 (1, 2).

The First International Congress of Plastic Surgery in Stockholm in 1955 marked a turning point in cleft lip surgery when doctor Millard presented his technique: the rotation-advance-

stisu tehniku – klizno-rotirajući režanj. Na početku svojega kliničkog rada Millard se koristio LeMesurierovom metodom, ali nije bio potpuno zadovoljan. Ralph Millard razvio je klizno-rotirajuću tehniku operirajući rascjepe usne kod djece tijekom vojne službe u Korejskom ratu. Oblikovanje klizno-rotirajućeg režnja temelji se na zakrivljenoj liniji (rotaciji) zdrave strane kako bi se uspostavila ravnoteža u diskrepanciji visine usne. Ovom tehnikom postižu se više simetrična visina usana, širina filtruma i simetrija baze nosa. Simetrična zakrivljena linija napravljena je na strani rascjepa s malim proširenjem ispod nosnih krila tako da se može postići pristup nosu (2, 3).

Ni jedna druga tehnika nije izdržala toliko dugo kao Millardov inovativni princip (4). Tehnika je anatomske logične te dopušta pojedinačne izmjene tako da se može prilagoditi svakom obliku rascjepa usne. Postoperativni ožiljak omogućuje korekciju, ako je potrebna. Danas se diljem svijeta ovom tehnikom (slika 1.), s modifikacijama ili bez njih, koristi više od 85 posto kirurga za rascjepe (5).

Prikaz slučaja

Je li ova tehnika doista počela nakon objavljenog rada Ralpa Millarda?

Opisujemo bolesnika s potpunim jednostranim rascjepom usne i nepca operiranog 1950., ili pet godina prije nego što je tiskan Millardov tekst.

Pacijent je nedavno hospitaliziran nakon hitnog prijama zbog frakture zigomatične kosti. Očito je bilo da mu je bio operiran rascjep usne i nepca, a koštani nedostatak bio je također vidljiv na MSCT-u kada je fraktura dijagnosticirana (slika 2.).

Ožiljak na usni zamjetan je i vrlo sličan klizno-rotirajućoj liniji. Skriven je u filtrumu usnice, a linija je zakrivljena na medijalnoj strani usne i čini se da je rotacija produžena ispod baze kolumele. Tu je jasno vidljiv ožiljak ispod nosnih krila na strani rascjepa koji bi mogao tvoriti klizno-rotirajući režanj. Plastiku usne obavio je prof. Šercer. U prilogu se nalazi nekoliko fotografija na kojima se vidi linija reza (slike 3. i 4.).

Pacijent je rođen 5. srpnja 1950. godine, a u dobi od šest mjeseci operirao ga je prof. Šercer u KBC-u Sestre milosrdnice u Zagrebu. Pokušali smo dobiti medicinsku dokumentaciju od Odjela ORL-a, ali ti su se podatci izgubili. Unatoč tomu, vrijeme operacije i kirurg dobro su poznati.

Rasprava

Nakon Millardova predstavljanja klizno-rotirajuće tehnike pojavile su se poteškoće zbog kratkoće usana. Millard je poslije primijenio tehniku sa stražnjim rezom kako bi se omogućilo više rotacije i veća dužina medijalnog režnja. Klizno-rotirajuću tehniku prilagođavali su mnogi kirurzi za ras-

ment flaps. At the beginning of his clinical career, Millard used LeMesurier method but he was not entirely satisfied with the results. Ralph Millard developed the rotation-advancement technique by operating the children with cleft lip during his military service in the Korean War. The design of rotation-advancement flap is based on a curved line (rotation) on the non-cleft side in order to balance the lip height discrepancy. With this technique a more symmetrical lip height, philtral column width and nasal base symmetry can be achieved. The symmetrical curved line is made on the cleft side with small extension beneath the *nasal ala* in order to achieve the access to the nose (2, 3).

No other technique has withstood the test of time like Millard's innovative principle (4). The technique is anatomically logical; it permits individual modifications, therefore, it can be adapted to each form of cleft lip. The type of scar and the patient's skin dictate the treatment of the scar. Sometimes, the postoperative scar needs to be corrected. However, surgery is performed to fix the scar in cases where the scar does not respond to other noninvasive applications. Today the technique (Figure 1), with or without some modifications, is used by more than 85% of cleft surgeons around the world (5).

Case report

Was Ralph Millard the first surgeon to describe this technique?

We present a case of the patient with complete unilateral cleft lip and palate who underwent surgery in 1950, which had happened five years before the Millard's publication.

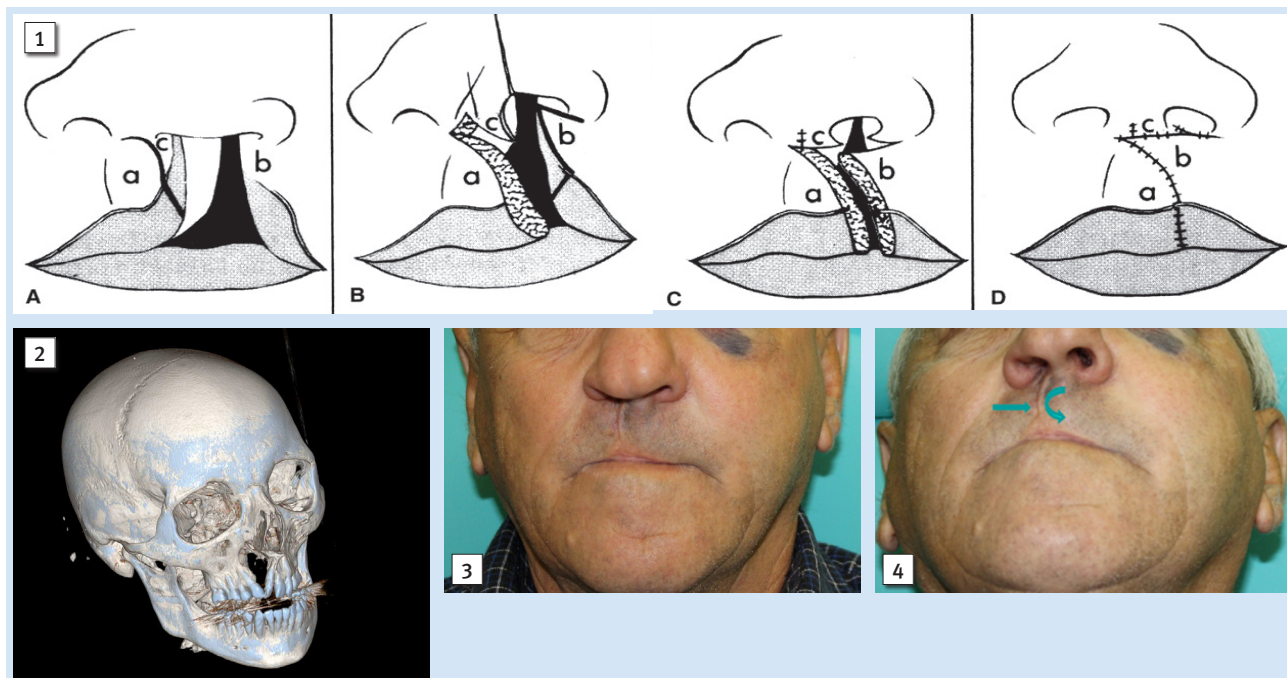
Recently, the patient was hospitalized at our emergency department due to zygomatic fracture. It was obvious that he had undergone the cleft lip and palate surgery. The bone cleft was also seen on MSCT scan when the fracture was diagnosed (Figure 2).

The scar on his lip was visible and it was similar to the rotation advancement line. The scar was hidden in the *philtrum* of the lip, and the line was curved on the medial side of the lip. It also seemed that the rotation was extended below the base of the *columella*. There was a clearly visible scar below the *ala nasi* of the cleft side which could form the advancement flap. Cheiloplasty was performed by Professor Šercer. We are enclosing a few photos which show the line of incision (Figure 3, 4).

The patient was born on July 5 in 1950 and he underwent the surgery when he was six months old. The surgery was performed by professor Šercer at "Sestre Milosrdnice Hospital" in Zagreb. We tried to get his medical records from the ENT Department, but they seemed to be lost. Yet, the time of the surgery and the surgeon were well known.

Discussion

After Millard's presentation of the rotation advancement technique there were some concerns about the shortness of the lip. Millard later changed the technique with the back-cut to enable more rotation and length of the medial flap. The rotation advancement technique has been followed with some



Slika 1A-D. Originalno oblikovanje klizno-rotirajućeg režnja koje je osmislio D. Ralph Millard u Koreji predstavljeno je na Prvom međunarodnom kongresu za plastičnu kirurgiju u Stockholmu 1955. godine (10)

Figure 1A-D The original rotation-advancement design conceived by D. Ralph Millard in Korea and presented at the First International Congress of Plastic Surgery in Stockholm in 1955 (10)

Slika 2. MSCT prikaz pacijenta

Figure 2 MSCT scan of the patient

Slika 3. Ožiljak na usni

Figure 3 Scar of the lip

Slika 4. Shema klizno-rotirajuće linije

Figure 4 Drawing of rotation advancement line

cjepe. Proširen rez u kolumeli, umetanje malog kožnog trokuta na strani koja nije zahvaćena rascjepom za produljenja ruba usnice na strani rascjepa, male geometrijske modifikacije na liniji rotacije ili promjene u subnazalnom rezu na strani rascjepa, samo su neke od njih. Dva režnja (rotacijski i klizni), kao što su bila u izvornom Millardovu opisu 1955., temelj su svih daljnjih tehnika modifikacija.

Profesor Ante Šercer rođen je 1896., a umro je 1968. Bio je jedan od osnivača otorinolaringologije u Hrvatskoj. Ubrzo nakon što je završio studij medicine u Pragu (Češka) i Grazu (Austrija), pohađao je specijalizirane tečajeve iz otorinolaringologije u Zagrebu, Beču i Pragu. Nakon povratka u domovinu radio je na odjelu ORL-a Sveučilišne klinike u Zagrebu od 1920. do 1945. godine, a od 1929. bio je voditelj odjela.

Danas je ime prof. Šercera sinonim za vodeću osobu hrvatske medicine i zdravstvene zaštite, bio je liječnik, učitelj i istraživač. Tijekom 1936./37. godine te 1943./45., bio je dekan Medicinskog fakulteta u Zagrebu. Bio je voditelj Odjela ORL-a u KBC-u Sestre milosrdnice od 1946. godine, koji je 1964. postao sveučilišna klinika. Bio je i osnivač Znanstvenog instituta za proučavanje i zaštitu uha i dišnih organa. Šercer je prvi hrvatski liječnik s međunarodnim priznanjem zbog tumačenja operacije deformacije nosne pregrade, otoskleroze i otkrivanja nazotorakalnog refleksa. Bio je vodeći kirurg u plastičnoj i rekonstruktivnoj kirurgiji nosa i uha, ne samo u Hrvatskoj nego i u ovom dijelu Europe (6).

modifications which have been made by numerous cleft surgeons. Extended incision in the *columella*, insertion of small skin triangle on the non-cleft side for the elongation of the lip on the cleft side or some other small geometric modification on the line of rotation or some changes in subalar incision on the cleft side are some of them. Two flaps (rotation and advancement) as it was described in the original Millard's publication in 1955 serve as basis for all further modification techniques.

Professor Ante Šercer was born in 1896 and he passed away in 1968. He was one of the founders of otorinolaringology in Croatia. Soon after completion of his medical studies in Prague (Czech Republic) and Graz (Austria), he attended the specialized courses in Otorinolaringology in Zagreb, Vienna and Prague. Having returned to his homeland, he worked at the Department of Ear, Nose and Throat Disease (ENT) University Clinic in Zagreb from 1920 to 1945, and from 1929 he was head of department.

Today, in Croatia, the name of professor Šercer is a synonym for a leading figure in the field of medicine, teaching and research. In 1936/37 and in 1943/45, he was director of "The Sestre Milosrdnice Hospital" in Zagreb. He was head of ENT Department in 1946 which was transformed into a University Clinic in 1964. He was also a founder of the scientific Institute for the Study and Protection of Ear and Respiratory Organs. Šercer was the first

Objavio je rad o operaciji rascjepa tijekom 1943. godine kada se koristio tehnikama poznatima u to doba (7). Njegov doprinos operaciji velofaringealne insuficijencije i plastičnoj kirurgiji nosa bio je značajan, ali vjerojatno nije dovoljno istaknuto njegovo ime. Bio je predvodnik operacije otvorene rinoplastike (dekortikacija) (8).

Knjigu o plastičnoj kirurgiji nosa, koju je napisao 1962. godine, treba smatrati njegovim najvažnijim djelom, a objavljena je na njemačkom (9). Bio je inicijator i glavni urednik *Hrvatske liječničke enciklopedije* koja je bila jedna od prvih takvih knjiga u svijetu (6).

Zaključak

Tri su osnovne tehnike za liječenje jednostranog rascjepa usne – ravna linija, geometrijska linija i klizno-rotirajuća tehnika. Klizno-rotirajući režanj, izvoran i odličan način za zatvaranje rascjepa usne, pripisuje se američkom kirurgu Ralphu Millardu, te je danas najčešće korištena metoda. Predstavili smo postoperativni rascjep usne pacijenta kojeg je operirao naš otorinolaringolog Ante Šerčer gotovo pet godina nego što je objavljen Millardov rad. Kiruršku tehniku kojom se koristio u ovom slučaju nije lako objasniti samo na temelju postoperativnog ožiljka od prije šezdeset i sedam godina, ali temeljitom analizom ožiljne linije može se zaključiti da je vrlo slična klizno-rotirajućoj metodi.

Croatian clinician with international reputation for interpretation of the formation of nasal septum deviation and otosclerosis. Also, he discovered the nasothoracic reflex. He was a leading surgeon in plastic and reconstructive surgery of the nose and ear not only in Croatia but also in this part of Europe (6).

He published scientific papers on cleft surgery in 1943 while he was using the techniques which were known at that time (7). His contribution to surgical management of velopharyngeal insufficiency and plastic surgery of the nose and ear is significant but probably not sufficiently associated with his name. He was an open rhinoplasty surgery pioneer (de-cortication) (8).

The book on plastic surgery of the nose, which was written by professor Šerčer in 1962, should be emphasized as his most important work. It was written in German (9). He initiated and was the editor in chief of a Croatian medical Encyclopedia, which was one of the first books of that kind in the world (6).

Conclusion

There are three basic techniques for unilateral cleft lip repair: straight line, geometric line and rotation advancement technique. The revolutionary rotation-advancement procedure for cleft lip repair is an original and excellent technique developed by the American surgeon Ralph Millard. Today, the rotation advancement technique is one of the most widely used methods. Our case report deals with postoperative cleft lip of the patient operated by the Croatian ENT specialist Ante Šerčer almost five years before Millard's publication. It is not easy to explain the surgical technique used in this case since it was based on the postoperative scar which had been made sixty-five years before this surgery. Yet, if the scar line is carefully analyzed, it can be observed that Šerčer's technique is very similar to the rotation advancement method.

Abstract

The early techniques of cleft lip repair involved the straight-line technique, the triangular flap technique or some kind of geometric line (triangular, quadrangular closure). A turning point in cleft lip surgery was in 1955 when doctor. Millard presented his method: the rotation-advancement technique or flap, at the First International Congress of Plastic Surgery in Stockholm. Today, the technique, with or without some modifications, is used by more than 85% of cleft surgeons around the world. We are presenting a patient with complete unilateral cleft lip and palate who underwent surgery sixty-five years ago. The scar on his lip was similar to rotation advancement line. Cheiloplasty was performed by Professor Šerčer in 1950, five years before Millard's publication. Professor Ante Šerčer was an internationally recognized Croatian scholar in the area of ear, nose and throat diseases. He also gave a significant contribution to surgical management of velopharyngeal insufficiency and plastic surgery of the nose and ear.

Received: November 14, 2016

Accepted: February 13, 2016

Address for correspondence

Marko Vuletić DMD,
Private practice, Žitna 8, 44000 Sisak,
Croatia.
Tel: +385 44 531 004,
Fax: +385 44 531 004,
vulesk@gmail.com

Key words

Cleft Lip; Cicatrix; Surgical Flaps; Operative Technique; Plastic Surgery

References

1. Salyer, KE; Marchac, A; Cheng, MS. Unilateral Cleft Lip/Nose Repair. In: Losee, JE; Kirschner RE - editors. *Comprehensive Cleft Care*. Columbus: The Mc Graw Hill Companies; 2009. p. 23-32.
2. Tollefson, TT; Sykes, JM. Cleft Lip Repair: Unilateral. In: Goudy, SL; Tollefson, TT - editors. *Complete Cleft Care – Cleft and Velopharyngeal Insufficiency Treatment in Children*. Stuttgart: Thieme Verlagsgruppe; 2015. p. 37-62.
3. Allen, GC; Banks, CA; Boss, EF. Cleft Lip Repair: Unilateral. In: Goudy, S; Tollefson, T - editors. *Complete Cleft Care*. Stuttgart: Thieme Verlagsgruppe; 2015. p. 37-9.
4. Stal S, Brown RH, Higuera S, Hollier LH Jr, Byrd HS, Cutting CB, et al. Fifty years of the Millard rotation-advancement: looking back and moving forward. *Plast Reconstr Surg*. 2009 Apr;123(4):1364-77.

5. Knežević P, Grgurević L, Uglešić V, Grgurević J. Modified Millard's technique in operations for unilateral cleft lip. *J Plast Surg Hand Surg*. 2012 Oct;46(5):326-9.
6. Padovan I. Život i djela Ante Šercera. Zagreb: Nakladni zavod Globus; 1997. p. 17.
7. Šercer A. Beitrage zur Technik der Lippen-Kiefer-Gaumenspaltenoperationen. *Archiv fur O.N.Kehlkopfheilkunde* 1943;153(3-4):319-42.
8. Šercer A. La decortication du nez et sa valeur pour la chirurgie cosmetique. *Rev Laryngol Otol Rhinol (Bord)*. 1957 Mar-Apr;78(3-4):161-8.
9. Šercer, A; Mundnich, K – editors. *Plastische Operationen an der Nase und an der Ohrmuschel*. Stuttgart: G. Thieme; 1962. p. 55-311.
10. Randall, P; Jackson, O. A Short History of Cleft Lip and Cleft Palate. In: Losee, JE; Kirschner, RE - editors. *Comprehensive Cleft Care*. Columbus: The McGraw-Hill Companies; 2009. p. 194.