

Significance of intraoperative findings in revision tympanomastoidectomy

Košec, Andro; Kelava, Iva; Ajduk, Jakov; Ries, Mihael; Trotić, Robert; Bedeković, Vladimir

Source / Izvornik: **American Journal of Otolaryngology, 2017, 38, 462 - 465**

Journal article, Accepted version

Rad u časopisu, Završna verzija rukopisa prihvaćena za objavljivanje (postprint)

<https://doi.org/10.1016/j.amjoto.2017.04.006>

Permanent link / Trajna poveznica: <https://urn.nsk.hr/urn:nbn:hr:105:666065>

Rights / Prava: [In copyright](#) / [Zaštićeno autorskim pravom.](#)

Download date / Datum preuzimanja: **2024-08-11**



Repository / Repozitorij:

[Dr Med - University of Zagreb School of Medicine
Digital Repository](#)





Središnja medicinska knjižnica

Košec A., Kelava I., Ajduk J., Ries M., Trotić R., Bedeković V. (2017)
Significance of intraoperative findings in revision
tympanomastoidectomy. American Journal of Otolaryngology, 38 (4).
pp. 462-5. ISSN 0196-0709

<http://www.elsevier.com/locate/issn/01960709>

<http://www.sciencedirect.com/science/journal/01960709>

<http://dx.doi.org/10.1016/j.amjoto.2017.04.006>

<http://medlib.mef.hr/2894>

University of Zagreb Medical School Repository

<http://medlib.mef.hr/>

Significance of Intraoperative Findings in Revision Tympanomastoidectomy

Andro Košec, MD^a, Iva Kelava, MD^a, Jakov Ajduk, MD, PhD^b, Mihael Ries, MD, PhD^b,
University Professor Robert Trotić, MD, PhD^c, University Professor Vladimir Bedeković, MD,
PhD^b

^a Department of Otorhinolaryngology and Head and Neck Surgery, University Hospital Center
Sestre milosrdnice, Vinogradska cesta 29, Zagreb, Croatia: andro.kosec@yahoo.com,
ivkel@yahoo.com

^b School of Medicine, University of Zagreb, Šalata 3b, Zagreb, Croatia: jakov.ajduk@gmail.com,
miskories@gmail.com, vladimir.bedekovic@kbcsm.hr

^c School of Dental Medicine, University of Zagreb, Gundulićeva 5, Zagreb, Croatia:
trotic@gmail.com

Author correspondence:

Andro Košec, MD

Department of Otorhinolaryngology and Head and Neck Surgery, University Hospital Center
Sestre milosrdnice, Vinogradska cesta 29, Zagreb, Croatia

Phone: +385 1 3787108, Fax: +385 13769067

e-mail: andro.kosec@yahoo.com

1. Abstract

Purpose: The study was designed to assess correlations between intraoperative findings in revision tympanomastoidectomy as predictors of cholesteatoma recurrence. **Materials and Methods:** A retrospective single-institution cohort of 101 patients who underwent surgical treatment for recurrent chronic otitis media in a tertiary referral otology center. **Results:** Out of 101 patients, 65 had canal wall up and 36 canal wall down revision surgery. There were 35 cholesteatoma recurrences. Sites most commonly associated with recurrent disease were residual facial ridge cells in 46 (45.5%), ossicular chain sites in 46 (45.5%) patients, posterior external auditory canal wall erosions in 38 (37.6%) patients and mastoid apex recurrence in 35 (34.7%) patients. Ossicular and posterior external auditory canal wall erosion and incomplete removal of mastoid apex cells correlate well with cholesteatoma recurrence accompanied by canal wall up surgery ($p=0.009$). Residual mastoid apex cells, posterior external auditory canal wall erosion and presence of residual facial ridge cells were identified as the strongest positive predictors of cholesteatoma recurrence, identifying high risk patients associated with canal wall down procedures. ($p=0.0036$) **Conclusions:** Correlations between intraoperative findings and cholesteatoma recurrence could improve preoperative and intraoperative planning and reduce the rates of postoperative failures¹ due to mismanagement of high risk areas.

Key words: revision tympanomastoidectomy; chronic otitis media; surgery; intraoperative; failure

2. Introduction

Chronic otitis media with cholesteatoma remains one of the most commonly surgically treated disorders in otology. Areas of recurrence after initial surgery can encompass disease limited to the tympanic cavity, but can also lead to extensive erosion of surrounding structures and temporal bone involvement. The main goals of revision surgery are to eliminate mucosal and bone disease while choosing the optimal surgical procedure plan. [1] Numerous published papers deal with two major surgical procedures that are used in achieving disease control: canal wall down (CWD) and canal wall up (CWU) procedures. Several factors have been described to contribute to postoperative failure after CWD surgery; small meatus, high facial ridge, dependent mastoid tip, granulation and poor cavity design. [2,3] Identifying and correcting residual disease factors converts discharging ears into dry, safe ears in most cases. However, few authors have investigated connections between intraoperative findings in revision surgery as predictors of cholesteatoma recurrence. Little literature is available in guiding the clinical decision making process in planning revision surgery. Improving preoperative and intraoperative understanding of recurrence patterns enables adequate control of the disease. The aim of this paper is to examine the intraoperative details of revision tympanomastoidectomy and analyze the patterns of cholesteatoma recurrence in the mastoid and tympanic cavity. It is our hypothesis that clinically useful patterns of cholesteatoma recurrence can be identified and that these patterns can help in deciding on the type of revision surgery.

3. Materials and Methods

This retrospective longitudinal cohort study and its protocol included 123 patients diagnosed with recurrent chronic otitis media and was approved by the University Hospital Centre Bioethical Board adhering to the Helsinki Declaration Revision of 1989. All patients who underwent canal wall up (CWU) or canal wall down (CWD) revision tympanomastoidectomy from January 1st, 2010 to December 31st, 2015 in our National Referral Centre for Otology were eligible for inclusion. The procedures were performed by an otologic team of 3 surgeons, with complete intraoperative notes obtained and analyzed. The patients were included consecutively, with demographic information, time and type of previous surgery, intraoperative anatomical and procedural details noted. All of the patients signed informed consent forms after evaluation by an otologist. Strict study protocol criteria excluded 22 patients due to incomplete documentation. Data for 12 sites of chronic otitis media with possible cholesteatoma recurrence were identified during revision surgery, documented by the same team of otologists. The large percentage of patients (80.3%) that had previous surgery at other institutions did not influence the quality of data obtained during the preparation of this manuscript. All of the patient's previous records were available, and the data were collected from uniform sources and intraoperative notes from our institution, created through a uniform manner of writing. Statistical analysis was performed using MedCalc software (Version 11.2.1 © 1993-2010. MedCalc Software bvba Software, Broekstraat 52, 9030 Mariakerke, Belgium), using standard descriptive statistics and frequency tabulation as indicated. Associations between variables were assessed using the Kruskal-Wallis test, chi-squared test and logistic regression with odds ratios (OR) with confidence intervals (CI) to test statistically significant correlations. All tests of statistical significance were performed using a two-sided 5% type I error rate.

4. Results

Patients' age ranged from 8 to 82 years with a mean value of 42.6 years. Of the total of 101 patients enrolled in the study, 56 (55.4%) were male and 45 (44.6%) female. There were 72 (71,3%) patients with only one previous surgery, and 29 (28.7%) patients with multiple previous surgeries, with an average of 2.5 surgeries per patient. The average time elapsed from previous surgery was 8 years. Of the 101 patients, 20 (19.8%) had been treated in our institution prior to revision surgery. The types of previous surgeries were tympanoplasties in 49 (48.5%) patients, tympanoplasties with ossicular chain reconstruction in 13 (12,9%) patients and CWU tympanomastoidectomies in 39 (38.6%) patients. The types of revision procedures were CWU tympanomastoidectomies in 65 (64.4%) patients and CWD tympanomastoidectomies in 36 (35.6%) patients. (Table 1) In the CWD revision procedure group, 7 patients underwent a previous CWU tympanomastoidectomy, while in 29 patients CWD surgery was performed outright due to extensive cholesteatoma recurrence. (Table 2)

The most common area of recurrent disease and debris retention were the residual facial ridge cells in 46 (45.5%) of patients and the ossicular chain in 46 (45.5%) patients, followed by cholesteatoma related erosion of the posterior external auditory canal wall in 38 (37.6%) patients, mastoid apex and antrum recurrence in 35 (34.7%) and 30 (29.7%) patients, respectively. (Table 3) Cholesteatoma recurrence was identified in 35 (34.7%) patients. Based on previously published areas of common recurrence, the patients were divided into 5 groups: 1. non-specific or normal finding, 2. residual facial ridge cells and ossicular chain recurrence, 3. posterior external auditory canal wall erosion, 4. mastoid recurrence, 5. tympanic cavity and mastoid recurrence. A significant correlation was shown between ossicular chain, posterior external auditory canal erosions, tympanic/mastoid cholesteatoma and CWD

tympanomastoidectomy ($p=0.02$, Kruskal-Wallis test). (Figure 1) Another positive correlation was shown between ossicular, posterior external auditory canal wall erosion, incomplete removal of tympanic/mastoid cells and increasing cholesteatoma recurrence ($p=0.009$, Kruskal-Wallis test). (Figure 2) Naturally, a positive correlation was noted between recurrent cholesteatoma and an increasing propensity toward CWD procedures ($p=0.001$, chi-squared test). A positive correlation was also found between rising age and recurrence ($p=0.028$, Kruskal-Wallis test). (Figure 3)

Outcomes in the logistic regression model were defined as recurrence of cholesteatoma and need for CWD procedure. When intraoperative sites of suspected cholesteatoma recurrence were analyzed, mastoid apex cells (OR 4.65, CI 0.69-31.22), posterior external auditory canal wall erosion (OR 2.42, CI 0.76-7.67), mastoid erosion (OR 2.01, CI 0.4-10.4) and residual facial ridge cells (OR 1.54, CI 0.49-4.85) were identified as the strongest positive predictors of cholesteatoma recurrence. Negative predictors of cholesteatoma recurrence were found to be tympanic perforation (OR 0.34, CI 0.11-1.05), dura exposition (OR 0.35, CI 0.07-1.81) and hypotympanum inflammation (OR 0.44, CI 0.05-3.91) ($p=0.040$, logistic regression). (Table 4) After analyzing the same intraoperative sites for correlation with performing CWD surgery, mastoid apex cells (OR 10.55, CI 1.44-77.4), posterior external auditory canal wall erosion (OR 4.3, CI 1.23-14.97) and mastoid erosion (OR 1.2, CI 0.23-6.4) were identified as positive predictors leading to CWD surgery. In contrast, tympanic perforation (OR 0.34, CI 0.1-1.1), chronic inflammation tissue in the attic (OR 0.65, CI 0.08-5.3) and antrum (OR 0.57, CI 0.12-2.6) were shown to correlate positively with CWU surgery ($p=0.0036$, logistic regression). (Table 5)

5. Discussion

A successful CWD surgical procedure in chronic otitis media should result with a dry postoperative cavity, with reported general failure rates ranging from 6 to 45%, and cholesteatoma recurrence in 5-49% of patients. [1,4,5] Published studies list the high facial ridge and inadequate meatoplasty as major factors leading to failure and revision surgery. Surgical failure is more frequent in patients with more severe disease, with residual tegmental, apical and sinodural cells causing prolonged ear discharge after both CWU and CWD initial procedures. [6,7] Recommendations for recurrent disease management encourage removal of all cells that do not drain into the middle ear. [1,2,6,8] The philosophy in revision surgery presented in this study was to remove cholesteatoma, sequestration and areas of re-infection while preserving the posterior external auditory canal wall, provided it had not been removed during previous surgery. Patients were followed-up by otoendoscopy and computed tomography in regular intervals, and a revision operation was scheduled if the findings suggested possible cholesteatoma recurrence. In the CWD revision procedure group, 7 patients underwent a previous CWU tympanomastoidectomy, while in 29 patients CWD surgery was performed outright due to extensive cholesteatoma recurrence. This is a strategy that has been known to ensure adequate surgical management of recurrent otitis media with cholesteatoma. [2,3,4] The CWD technique includes exenteration of residual mastoid cells, especially in the sinodural angle, saucerization of the mastoid cavity, exposure of the attic, lowering the facial ridge and wide meatoplasty with partial cavity obliteration, resulting in a trouble-free cavity in 83-96% of cases. [5,9] The most common area of recurrent disease in our patient population were the residual perifacial cells in both CWU and CWD procedures. Other areas merit attention as well, especially ossicular chain, posterior external auditory canal wall erosions and residual mastoid apex cells. The most

common areas of disease recurrence are similar in published literature, indicating that systematic surgical mismanagement is a significant factor behind many of the revision cases. That is particularly stressed in papers discussing the role of a high facial ridge that leads to facial recess, hypotympanum and caudal mastoid debris retention. [6,10] Using inside-out (subcortical) mastoidectomy or failure to address disease around the head of the malleus may also promote recurrence and granulation formation. [1] Staging the procedure may augment functional results, but the majority of our patients were not generally interested in multiple-stage surgery due to previous surgical failure, especially if the contralateral ear was not affected.

Out of 101 revision cases, 35 (34.7%) had recurrent cholesteatoma. Some authors report that 84.8% of all cholesteatomas found in initial surgeries are located in the epitympanum, and only 8% of cholesteatomas found in revision tympanomastoidectomies are located in the mastoid, concluding that intraoperative surgical findings cannot predict the pattern of recurrence. [11] This might be due to the absence of paired patient data samples in large studies evaluating initial and revision surgery intraoperative details. However, intraoperative findings in revision tympanomastoidectomy can be valuable in planning the extent of surgery and evaluating possible areas of cholesteatoma recurrence. Surgical technique quality is often labeled as a major factor influencing postoperative outcome rather than type of surgery alone. [12] A high incidence of residual cholesteatoma disease may be caused by inadequate preoperative and intraoperative surgical planning and failure to explore vital areas of high risk for residual disease. That, in turn, leads to a higher percentage of CWD procedures in revision surgery. [1,4,13] Large studies on revision surgery have not established significant correlations between surgical failure and intraoperative findings. [13] There have been reports linking tympanic facial canal dehiscence and lateral semicircular canal fistulas as well as posterior auditory canal bony erosion and stapes

destruction, advising care in approaching the facial nerve tympanic segment. [14,15,16,17] Ossicular chain erosion has been identified in 15-62% of patients with chronic otitis media without cholesteatoma, and a correlation with posterior tympanic perforation was shown. [18] Otoendoscopic techniques could potentially reduce the need for CWD procedures in revision surgery and offer excellent visual access to areas of frequent recurrence, but have not shown to decrease the overall cholesteatoma recurrence rate so far. [19]

Our results show that grouping areas of common recurrence patterns helps to identify patients with high risk of cholesteatoma recurrence. Certain novel connections between areas of recurrence may serve as early indicators of recurrence and lead the surgeon to areas of cholesteatoma involvement that might otherwise be overlooked. (Figures 1 and 2) They also indicate that additional exploration of high risk areas is advisable, especially in older patients that have a significantly higher rate of mastoid recurrence. This is most likely due to increased disease duration and undergoing several previous surgeries in the mastoid. (Figure 3)

Defining outcomes in revision surgery as cholesteatoma recurrence on one side and need for CWD procedures on the other enables a better appraisal of individual risk, since not every cholesteatoma recurrence requires a CWD procedure. Logistic regression models identified residual mastoid apex cells, posterior external auditory canal wall erosion, mastoid erosion and residual cells along the facial ridge as the most reliable predictors of cholesteatoma recurrence. All of these areas need examining for possible disease when noting any one of them is involved. This is a clinically useful finding that has not been reported before with statistical significance. (Table 3) In addition, the same predictors were found to correlate very well with a higher propensity toward CWD surgery. The logistic regression model also identified tympanic perforation, chronic inflammation tissue in the attic and mastoid antrum as negative predictors

for CWD surgery. These factors correlate with cholesteatoma recurrence limited to the tympanic cavity, requiring a less radical procedure. [20] (Table 4) Similar results have not been previously reported, and this study offers novel data on clinically useful patterns of cholesteatoma recurrence that may affect intraoperative decisions. The absence of available data supporting clinical decision making is often stressed, making novel data and risk stratification and prediction models of vital importance in planning and performing revision surgery.

6. Conclusion

In revision chronic otitis media surgery, expert clinical judgment and technical ability of the surgeon are important, augmented by intraoperative planning using novel data on high risk areas. Using patterns of cholesteatoma recurrence may lead to increased control of the disease in revision surgery. In addition, understanding the correlations between sites of recurrence can be helpful in deciding on the type of revision surgery.

Conflict of Interest Statement and Acknowledgements

This research did not receive any specific grant from funding agencies in the public, commercial, or not-for-profit sectors.

7. References:

- [1] Veldman JE, Braunius WW. Revision surgery for chronic otitis media: a learning experience. Report on 389 cases with long-term follow-up. *Ann Otol Rhinol Laryngol*. 1998;107:486–91.
- [2] Kasenõmm P. Intraoperative findings of revision canal wall-down tympanomastoid surgery. *Acta Otolaryngol*. 2013;133:826–32.
- [3] Park KT, Song JJ, Moon SJ, Lee JH, Chang SO, Oh SH. Choice of approach for revision surgery in cases with recurring chronic otitis media with cholesteatoma after the canal wall up procedure. *Auris Nasus Larynx*. 2011;38:190–5.
- [4] O'Leary S, Veldman JE. Revision surgery for chronic otitis media: Recurrent-residual disease and hearing. *J Laryngol Otol*. 2002;116(12):996-1000.
- [5] Cho YS, Hong SD, Chung KW, Hong SH, Chung WH, Park SH. Revision surgery for chronic otitis media: Characteristics and outcomes in comparison with primary surgery. *Auris Nasus Larynx*. 2010;37:18-22.
- [6] Nadol JB. Causes of failure of mastoidectomy for chronic otitis media. *Laryngoscope*. 1985;95:410-3.
- [7] Kriskovich M, Shelton C. *Surgical treatment of chronic otitis media and cholesteatoma*. In: Canalis RF, Lambert PR. *The Ear: Comprehensive Otology*. Philadelphia: Lippincott Williams and Wilkins; 2000: 447 – 65.

- [8] Bhatia S, Karmarkar S, DeDonato G, Mutlu C, Taibah A, Russo A, et al. Canal wall down mastoidectomy: causes of failure; pitfalls and their management. *J Laryngol Otol.* 1995;109:583–9.
- [9] Yung M, Tassone P, Momouldis I, Vivekanandan S. Surgical management of troublesome mastoid cavities. *J Laryngol Otol.* 2011;125:221–6.
- [10] Bercin S, Kutluhan A, Bozdemir K, Yalciner G, Sari N, Karamese O. Results of revision mastoidectomy. *Acta Otolaryngol.* 2009;129:138–41.
- [11] Syms MJ, Luxford WM. Management of cholesteatoma: status of the canal wall. *Laryngoscope* 2003;113:443–8.
- [12] Faramarzi A, Motasaddi-Zarandy M, Khorsandi MT. Intraoperative Findings in Revision Chronic Otitis Media Surgery. *Arch Iranian Med.* 2008;11:196–9.
- [13] Megerian CA, Cosenza MJ, Meyer SE. Revision tympanomastoid surgery. *Ear, Nose & Throat Journal.* 2002;81:718.
- [14] Gülüstan F, Aslan H, Songu M, Başoğlu MS, Katılmış H. Relationships between facial canal dehiscence and other intraoperative findings in chronic otitis media with cholesteatoma. *Am J Otolaryngol.* 2014;35:791–5.
- [15] Selesnick SH, Lynn-Macrae AG. The incidence of facial nerve dehiscence at surgery for cholesteatoma. *Otol Neurotol.* 2001;22:129–32.
- [16] Ozbek C, Tuna E, Ciftci O, Yazkan O, Ozdem C. Incidence of fallopian canal dehiscence at surgery for chronic otitis media. *Eur Arch Otorhinolaryngol.* 2009;266:357–62.

- [17] Adad B, Rasgon BM, Ackerson L. Relationship of the Facial Nerve to the Tympanic Annulus: A Direct Anatomic Examination. *Laryngoscope*. 1999;109:1189-92.
- [18] Albera R, Dagna F, Filippini C, Albera A, Canale A. Ossicular Chain Lesions in Tympanic Perforations and Chronic Otitis Media without Cholesteatoma. *J Int Adv Otol*. 2015;11: 143-6.
- [19] Ayache S, Tramier B, Strunski V. Otoendoscopy in Cholesteatoma Surgery of the Middle Ear: What Benefits Can Be Expected? *Otol Neurotol*. 2008;29:1085-90.
- [20] Kaylie DM, Gardner EK, Jackson CG. Revision chronic ear surgery. *Otolaryngol Head and Neck Surg*. 2006;134:443-50.

Author Contributions: All authors had full access to all of the data in the study and take responsibility for the integrity of the data and the accuracy of the data analysis. Study concept and design was drafted by all of the authors, as was the acquisition, analysis, and interpretation of data. Drafting of the manuscript and critical revision of the manuscript for important intellectual content was done by all of the authors. Statistical analysis was performed by Košec. No funding was obtained. Administrative, technical, or material support was given by all of the authors. Study supervision done by Ries, Trotić and Bedeković.

Tables and Legends

Table 1. Distribution of previous surgical procedures.

<i>Previous procedures</i>	
Tympanoplasty	49 (48.5)
Tympanoplasty with ossicular chain reconstruction	13 (12.9)
Canal wall up tympanomastoidectomy	39 (38.6)
<i>Total</i>	101

Table 2. Distribution of revision tympanomastoidectomies with cholesteatoma recurrences observed during revision surgery.

	<i>N of patients</i> (%)	<i>N of cholesteatoma</i> <i>recurrences noted during</i> <i>revision surgery (%)</i>
<i>Revision procedures</i>		
Canal wall up tympanomastoidectomy	65 (64.4)	6 (17.1)
Canal wall down tympanomastoidectomy	36 (35.6)	29 (82.9)
<i>Total</i>	101	35

Table 3. Distribution of intraoperative findings from 12 intraoperatively noted sites related to disease recurrence in CWD and CWU revision tympanomastoidectomies.

Intraoperative finding	CWU (N=65)	CWD (N=36)	Total (N=101)
	(%)	(%)	(%)
Tympanic perforation	39 (60)	10 (27.8)	49 (48.5)
Residual perifacial cells	24 (36.9)	22 (61.1)	46 (45.5)
Ossicular chain erosion	31 (47.7)	15 (41.7)	46 (45.5)
Posterior external auditory canal wall erosion	20 (30.8)	18 (50)	38 (37.6)
Residual mastoid apex cells	17 (26.2)	18 (50)	35 (34.7)
Antrum inflammation	18 (27.7)	12 (33.3)	30 (29.7)
Attic inflammation	16 (24.6)	10 (27.8)	26 (25.7)
Dehiscent facial nerve canal	12 (18.5)	13 (36.1)	25 (24.8)
Mastoid erosion and residual cells	11 (16.9)	12 (33.3)	23 (22.8)
Residual sinodural angle cells	12 (18.5)	9 (25)	21 (20.8)
Hypotympanum inflammation	10 (15.4)	6 (16.7)	16 (15.8)
Dura exposition	8 (12.3)	8 (22.2)	16 (15.8)

Table 4. Intraoperative findings as predictors of cholesteatoma recurrence in revision tympanomastoidectomy.

	<i>Odds ratio</i> <i>(confidence interval)</i>	<i>Significance</i> <i>(p value)</i>
<i>Positive predictors of outcome</i>		
Residual mastoid apex cells	4.65 (0.69-31.22)	<i>p</i> =0.040, logistic regression
Posterior external auditory canal wall erosion	2.42 (0.76-7.67)	
Mastoid erosion and residual cells	2.01 (0.4-10.4)	
Residual facial ridge cells	1.54 (0.49-4.85)	
<i>Negative predictors of outcome</i>		
Tympanic perforation	0.34 (0.11-1.05)	
Dura exposition	0.35 (0.07-1.81)	
Hypotympanum inflammation	0.44 (0.05-3.91)	

Table 5. Intraoperative findings as predictors of need for performing a CWD procedure in revision tympanomastoidectomy.

	<i>Odds ratio</i> <i>(confidence interval)</i>	<i>Significance</i> <i>(p value)</i>
<i>Positive predictors of outcome</i>		
Residual mastoid apex cells	10.55 (1.44-77.4)	<i>p</i> =0.0036, logistic regression
Posterior external auditory canal wall erosion	4.3 (1.23-14.97)	
Mastoid erosion and residual cells	1.2 (0.23-6.4)	
<i>Negative predictors of outcome</i>		
Tympanic perforation	0.34 (0.1-1.1)	
Attic inflammation	0.65 (0.08-5.3)	
Antrum inflammation	0.57 (0.12-2.6)	

Figure Legends

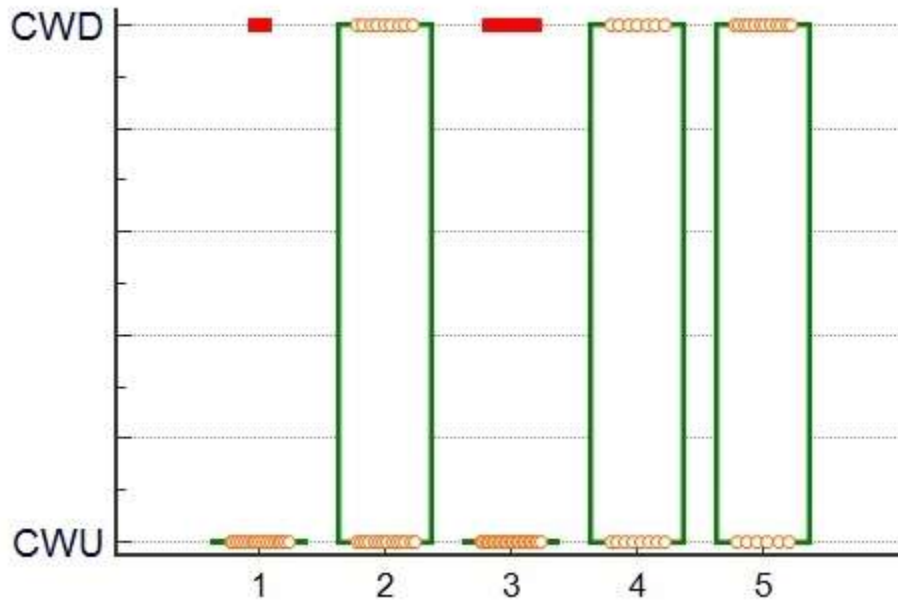


Figure 1. Positive correlation between ossicular chain and posterior external auditory canal erosions, tympanic and mastoid chronic otitis findings and CWD tympanomastoidectomy ($p=0.02$, Kruskal-Wallis test). (1 - non-specific or normal finding, 2 - residual facial ridge cells recurrence, 3 - ossicular and posterior external auditory canal wall erosion, 4 - mastoid recurrence, 5 - tympanic cavity and mastoid recurrence)

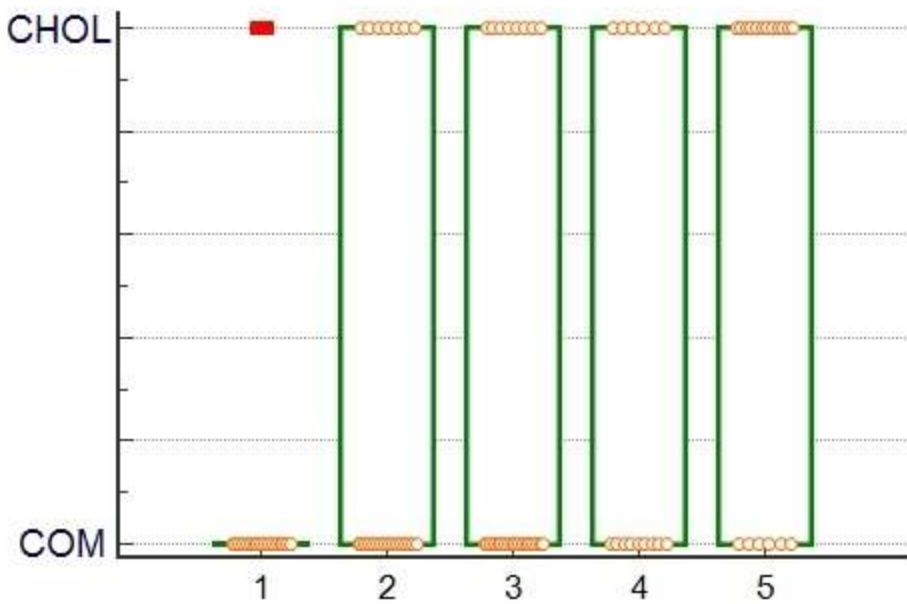


Figure 2. Positive correlation between cholesteatoma recurrence and incomplete removal of tympanic cavity and mastoid cells ($p= 0.009$, Kruskal-Wallis test). (CHOL – cholesteatoma, COM – chronic otitis media findings, 1 - non-specific or normal finding, 2 - residual facial ridge cell recurrence, 3 - ossicular and posterior external auditory canal wall erosion, 4 - mastoid recurrence, 5 - tympanic cavity and mastoid recurrence)

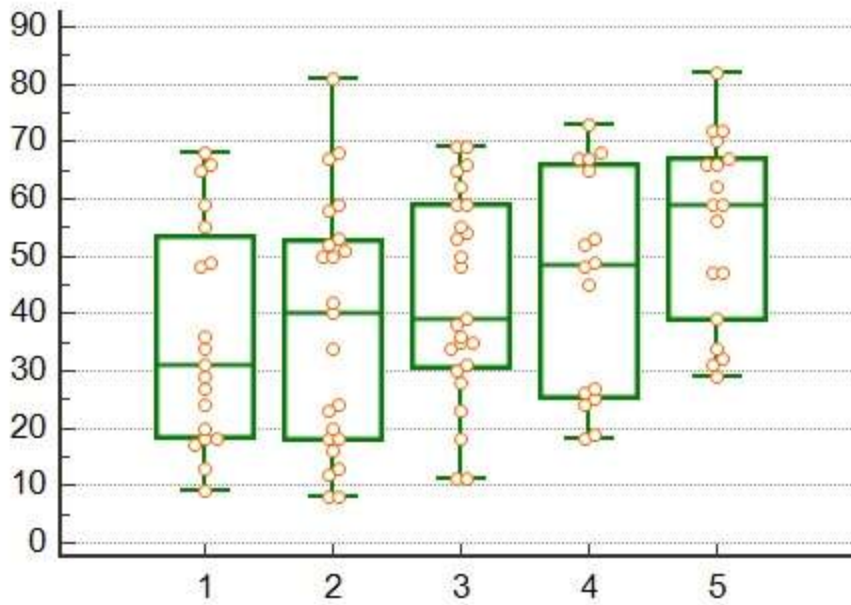


Figure 3. Positive correlation between rising age (in years) and disease recurrence in the mastoid ($p=0.028$, Kruskal-Wallis test). (1 - non-specific or normal finding, 2 - residual facial ridge cell recurrence, 3 - ossicular and posterior external auditory canal wall erosion, 4 - mastoid recurrence, 5 - tympanic cavity and mastoid recurrence)