

Diameters and bone thickness at the margin of the foramen magnum in dry skulls from pediatric population: a cross-sectional anatomical study

Raguž, Marina; Hrabač, Pero; Sedmak, Dora; Gjurašin, Miroslav; Kovačić, Nataša

Source / Izvornik: **Child's Nervous System, 2017, 33, 819 - 823**

Journal article, Accepted version

Rad u časopisu, Završna verzija rukopisa prihvaćena za objavljivanje (postprint)

<https://doi.org/10.1007/s00381-017-3374-5>

Permanent link / Trajna poveznica: <https://um.nsk.hr/um:nbn:hr:105:793762>

Rights / Prava: [In copyright](#)/[Zaštićeno autorskim pravom.](#)

Download date / Datum preuzimanja: **2025-03-15**



Repository / Repozitorij:

[Dr Med - University of Zagreb School of Medicine Digital Repository](#)





Središnja medicinska knjižnica

Raguž M., Hrbač P., Sedmak D., Gjurašin M., Kovačić N. (2017)
***Diameters and bone thickness at the margin of the foramen magnum
in dry skulls from pediatric population: a cross-sectional anatomical
study. Child's Nervous System, 33 (5). pp. 819-23. ISSN 0256-7040***

<http://www.springer.com/journal/381>

<http://link.springer.com/journal/381>

The final publication is available at Springer via
<https://doi.org/10.1007/s00381-017-3374-5>

<http://medlib.mef.hr/2901>

University of Zagreb Medical School Repository

<http://medlib.mef.hr/>

Title: Diameters and bone thickness at the margin of the foramen magnum in dry skulls from pediatric population: A cross-sectional anatomical study

Marina Raguz^{1,2}, Pero Hrabac³, Dora Sedmak^{1,3}, Miroslav Gjurasin⁴, Natasa Kovacic^{1,3}

1 Department of Anatomy and Clinical anatomy, University of Zagreb School of Medicine

2 Department of Neurosurgery, University Hospital Dubrava, Zagreb

3 Croatian Institute for Brain Research, University of Zagreb School of Medicine

4 Department of Neurosurgery, Children's Hospital Zagreb

Corresponding author:

Marina Raguz, Department of Anatomy and Clinical anatomy, University of Zagreb School of Medicine, Salata 11 Zagreb HR-10000, Croatia, marina.raguz@mef.hr, Phone: + 385 1 4566 953, Fax: + 385 1 4590 195

Acknowledgments:

We thank Prof. Vedran Katavić for the critical reading of the manuscript, and his constructive input.

Abstract

Purpose The purpose of the study was to estimate the size and bone thickness at the margin of the foramen magnum in a pediatric population.

Methods Sixty occipital bone specimens from the collection of macerated skulls at the Department of Anatomy, University of Zagreb, were examined and measured using a vernier scale/caliper. For the purpose of analysis, specimens were divided into two age groups: 1-6 years, and 7-18 years of age (before and after the fusion of ossification centers in the occipital bone). We measured the following: antero-posterior and transverse diameters of the foramen magnum, bone thicknesses at the basion, opisthion, 2 paramedial points on the anterior and posterior margins, and at the occipito-squamous junction.

Results Data presented in this study show that diameters of the foramen magnum increase with age, whereas bone thickness shows variable behavior depending on the measured area.

Conclusions Increases in diameters in specimens from the younger age group, and their absence in specimens from older subjects reflect the growth pattern of the basilar part of occipital bone. Variability of bone thickness at the margin of the foramen magnum and lack of its association with age of the subjects may be attributed to various factors, and may potentially affect the clinical presentation of compression syndromes at the level of foramen magnum.

Keywords

bone thickness, foramen magnum, posterior cranial fossa

Introduction

The occipital bone encloses the posterior cranial fossa and consists of the occipital squama, which develops intramembranously, and the basal part, developing mostly from cartilage [2, 7, 9]. It appears on month 3 of gestation, as irregular ossification centers, which start to fuse between 2nd and 3rd postnatal years, to form a single occipital bone by the age of 7 [2, 11].

The basilar part of the occipital bone contains a large oval opening, the foramen magnum (FM), that allows for the passage of the spinal cord, anterior and posterior spinal arteries and veins, vertebral arteries, and spinal roots of CN XI, the accessory nerve [4, 14]. Variations in the size and shape of the basilar part of the occipital bone, including the FM, reflect the influence of both, the genetic and environmental regulators of bone development and metabolism [3, 6, 12].

Morphometric data describing normal adult FM morphology have been previously reported [1, 13]. However, bone thickness at the margin of the FM, has previously not been assessed.

The aim of the present study is to measure size and bone thickness at the margin of the FM in dry cadaver bones from a pediatric population, and assess their relation to age and sex.

Materials and Methods

The study included 60 occipital bones (30 male and 30 female, 1-18 years of age) from the collection of macerated isolated skull bones at the Department of Anatomy, University of Zagreb School of Medicine, collected between 1940 and 1970 [5]. The ethical approval was obtained from the Research Ethics Committee of the University of Zagreb School of Medicine.

Specimens were divided into 2 groups according to their age; specimens from subjects aged 1 to 6 years (including those aged 6 years, before the fusion of ossification centers); and specimens from subjects aged 7 to 18 years (including those aged 7 years, after the fusion of ossification centers).

Using a vernier scale/caliper, we measured the antero-posterior (AP) and transverse (T) diameters of the FM, and bone thickness at the margin of the FM (Fig. 1). The AP diameter was measured from the basion to the opisthion. The T diameter was measured as the distance between the lateral margins of the FM on the line vertically intersecting the midpoint of the AP diameter. The bone thicknesses were measured at the basion, B (anterior margin), opisthion, O (posterior margin), and two additional paramedial points on the anterior (B1, B2) and posterior (O1, O2) margins of the FM, positioned between the lateral and the medial quarter of the transverse diameter. Thickness of the occipital bone was also measured at a point located 2 cm caudally from the opisthion (OC), corresponding to the occipito-squamous junction, slightly beneath the external occipital protuberance (Fig. 1). All measurements were made by the same researcher, and repeated three times, using the mean value for further statistical analysis.

For the statistical analysis, distribution was assessed by the Kolmogorov-Smirnov test, confirming normal distributions for all 9 variables. For normally distributed variables, we used t-test for comparison between groups. Due to significant deviation of age from normal distribution and smaller sample size in separated age groups, we used a non-parametric (Spearman)

correlation. Statistical analysis was performed using MedCalc Statistical Software version 12.5.0 (MedCalc Software bvba, Ostend, Belgium; <https://www.medcalc.org>).

Results

The AP diameter of the FM was found to be clearly associated with age (Table 1, Fig. 2) in subjects younger than 6 years. Both, AP and T diameters were not associated with age in subjects older than 7 years (Fig. 2).

The association of bone thickness with age was less clear. Bone thickness at the basion (B) was not associated with age (Table 1, Fig. 2). Bone thickness was clearly positively associated with age at paramedial points of basion (B1/B2) only in the age group 0-6 (Table 1).

On the contrary, bone thickness at the opisthion (O), was clearly associated with age of the subjects (Fig. 2). Interestingly, lack of association in the age group 0-6, points to greater bone deposition in the period after the fusion of ossification centers. In contrast to median point, thickness at paramedial points of the posterior margin (O1, O2) was positively associated with age among all subjects (Table 1), but when subgroups were separately analyzed, the association was clearly detectable only in subjects aged 0-6 years (Table 1).

We next assessed the influence of sex on diameters and bone thicknesses at the margin of the FM. Comparisons of measured variables revealed significantly lower AP diameters of the FM in female skulls, whereas all other parameters failed to reach a statistically significant difference between sexes (Fig. 3). When we separately assessed the associations of measured parameters with age in male and female subjects, we found that AP diameters, and bone thicknesses at the opisthion (O) were consistently related to age in both sexes (Table 2). However, the basion thicknesses seemed to be affected by sex, as they were clearly negatively associated with age in female skulls (Table 2). Additionally, the transverse diameter of FM in skulls of male subjects was not related to age (Table 2).

Discussion

The cross-sectional data presented in this study confirm the expected increase in diameters of the FM with age, whereas bone thicknesses are variable, and are clearly associated with age only in the posterior part of the FM.

The prominent increase of the diameters in the specimens from the younger (0-6) age group and its absence in older subjects (7-18) is an expected finding, taking into account the fact that sutures of the occipital bone close at the age of 7 [9, 11]. The finding of significantly shorter AP diameters of the FM in female skulls is in accord with the well established sex dimorphism [13]. Bone thicknesses at the margin of the FM showed wide variability, especially at the opisthion and paramedial points on posterior side of FM (range approx. 4 mm). Similar variability in thickness of the occipital bone was reported for the area around the external occipital protuberance [8, 15, 16]. This may be ascribed to individual variations due to the influence of constitutional factors (body weight and height, strength and volume of the surrounding muscles), as well as the presence or absence of potential systemic conditions affecting bone growth (metabolic disorders, nutritional status). We could not control for such confounding factors, as the skull collection dates from the period between 1940 and 1970, and no further data on the subjects are available beyond their age. However, taking into account the fact that variability in diameters and bone thickness measured in the current study is comparable to the variability described by similar studies [15, 16], we can stipulate that bone thickness is potentially more sensitive to the influence of individual constitutional or metabolic factors, than the diameters of FM, which show less variability.

A clear association of thickness with age was found only on the posterior margin of the FM (O, O1, O2), which showed greatest individual variations, supporting the conclusion that bone deposition in this area occurs continuously to adulthood.

A potential clinical application of these findings may be in compression syndromes, e.g. the Chiari's malformation type I [1, 14], where bone thickness can affect the clinical presentation by modifying the length of the compressed segment. This should be addressed by further studies in patients, by a parallel assessment of bone thicknesses at the margin of the FM, degrees of tonsillar protrusion and clinical presentations.

Conflict of interest statement

On behalf of all authors, the corresponding author states that there is no conflict of interest.

References

- 1.) Boulez AO, Sorter K, Geyer CA, Gado MH (1985) Position of cerebellar tonsils in the normal population and in patients with Chiari malformation: a quantitative approach with MR imaging. *J Comput Assist Tomogr* 9:1033-1036
- 2.) Bernard S, Loukas M, Rizk E, Oskouian R, Delashaw J, Tubbs R (2015) The human occipital bone: review and update on its embryology and molecular development. *Childs Nerv Syst* 31:2217–2223
- 3.) Caldemeyer KS, Boaz JC, Wappner RS, Moran CC, Smith RR, Quets JP (1995) Chiari I malformation: association with hypophosphatemic rickets and MR imaging appearance. *Radiology* 195:602–604
- 4.) Grey H (2008) *Gray's anatomy*, 20th edn. Bartleby, New York, pp 23-28
- 5.) Judas M, Petanjek Z, Kostovic I (2011) Jelena Krmpotic Nemanic (1921–2008): contributions to human neuroanatomy. *Coll Antropol* S1:345–349
- 6.) Kuether TA, Piatt JH (1998) Chiari malformation associated with vitamin D-resistant rickets: case report. *Neurosurgery* 42:1168–1171
- 7.) Matsumura G, England MA, Uchiumi T, Kodama G (1994) The fusion of ossification centers in the cartilaginous and membranous parts of the occipital squama in human fetuses. *J Anat* 185:295-300
- 8.) Naderi S, Usal C, Tural AN, Korman E, Mertol T, Arda MN (2001) Morphologic and radiologic anatomy of the occipital bone. *J Spinal Disord* 14:500-3
- 9.) Shapiro R, Robinson F (1976) Embryogenesis of human occipital bone. *AJR Am J Roentgenol* 126:1063-8
- 10.) Smoker WR (1994) Craniovertebral junction: normal anatomy, craniometry, and congenital anomalies. *Radiographics*. 14:255-77
- 11.) Sperber GH (2001) *Craniofacial development*. Hamilton, London, p 94

- 12.) Tubbs RS, Wellons JC III, Smyth MD, Bartolucci AA, Blount JP, Oakes WJ, Grabb PA (2003) Children with growth hormone deficiency and Chiari I malformation: a morphometric analysis of the posterior cranial fossa. *Pediatr Neurosurg* 38:324–328
- 13.) Tubbs RS, Griessenauer CJ, Loukas M, Shoja MM, Cohen-Gadol AA (2009) Morphometric analysis of the foramen magnum: an anatomic study. *Neurosurgery* 66:385-388
- 14.) Tubbs RS, Benzie AL, Rizk E, Chern JJ, Loukas M, Oakes WJ (2015) Histological study of the occipital bone from patients with Chiari I malformation. *Childs Nerv Syst* 32:351-3
- 15.) Wang YL, Xu HM, Wang XY, Li Y, Shen ZH, Zhou KL, Zhou F, Jin HM, Chen JX, Kong QY (2015) A Computed Tomographic Morphometric Study of the Pediatric Occipital Bone Thickness: Implications for Pediatric Occipitocervical Fusion. *Spine (Phila Pa 1976)* 15;40:1564-1571
- 16.) Zipnick RI, Merola AA, Gorup J, Kunkle K, Shin T, Caruso SA, Haheer TR (1996) Occipital morphology. An anatomic guide to internal fixation. *Spine (Phila Pa 1976)* 1;21:1719-1730

Table 1. Association of diameters and bone thicknesses at the margin of the foramen magnum with age

	All		Age ≤6		Age ≥7	
	ρ	P	P	P	ρ	P
AP	<i>0,404</i>	<i>0,001</i>	<i>0,652</i>	<i>0,000</i>	<i>0,097</i>	<i>0,609</i>
T	<i>0,409</i>	<i>0,001</i>	<i>0,382</i>	<i>0,037</i>	<i>0,264</i>	<i>0,159</i>
B	-0,182	0,165	0,201	0,287	-0,089	0,641
B1	-0,027	0,841	<i>0,363</i>	<i>0,049</i>	-0,264	0,158
B2	<i>0,301</i>	<i>0,019</i>	<i>0,398</i>	<i>0,030</i>	-0,182	0,336
O	<i>0,476</i>	<i>0,000</i>	0,153	0,421	<i>0,418</i>	<i>0,021</i>
OC	0,209	0,108	0,178	0,346	0,255	0,174
O1	<i>0,432</i>	<i>0,001</i>	<i>0,468</i>	<i>0,009</i>	<i>0,381</i>	<i>0,038</i>
O2	<i>0,466</i>	<i>0,000</i>	<i>0,376</i>	<i>0,040</i>	0,220	0,243

Non-parametric (Spearman) correlation was used, statistically significant correlations ($p < 0.05$) are shown in italics. AP, antero-posterior diameter; B, bone thickness measured at the basion; B1 (B2), bone thickness measured at paramedial points of the anterior margin of the FM; O, bone thickness measured at the opisthion; O1 (O2), bone thickness measured at paramedial points of the posterior margin of the FM; OC, bone thickness measured 2 cm posterior to the opisthion; T, transverse diameter

Table 2. Association of diameters and bone thicknesses at the margin of the foramen magnum with age and sex

	f		M	
	ρ	P	P	P
AP	<i>0,508</i>	<i>0,004</i>	<i>0,391</i>	<i>0,033</i>
T	<i>0,554</i>	<i>0,001</i>	0,30 ρ 6*	0,101*
B	-0,400*	0,028*	0,036	0,851
B1	-0,015	0,938	-0,049	0,799
B2	0,129*	0,496*	<i>0,456</i>	<i>0,011</i>
O	<i>0,425</i>	<i>0,019</i>	<i>0,521</i>	<i>0,003</i>
OC	0,144	0,449	0,289	0,121
O1	<i>0,481</i>	<i>0,007</i>	<i>0,367</i>	<i>0,046</i>
O2	<i>0,451</i>	<i>0,012</i>	<i>0,480</i>	<i>0,007</i>

Non-parametric (Spearman) correlation was used, statistically significant correlations ($p < 0.05$) are shown in italics. *correlation coefficients influenced by sex; AP, antero-posterior diameter; B, bone thickness measured at the basion; B1 (B2), bone thickness measured at paramedial points of the anterior margin of the FM; O, bone thickness measured at the opisthion; O1 (O2), bone thickness measured at paramedial points of the posterior margin of the FM; OC, bone thickness measured 2 cm posterior to the opisthion; T, transverse diameter

Figure legends

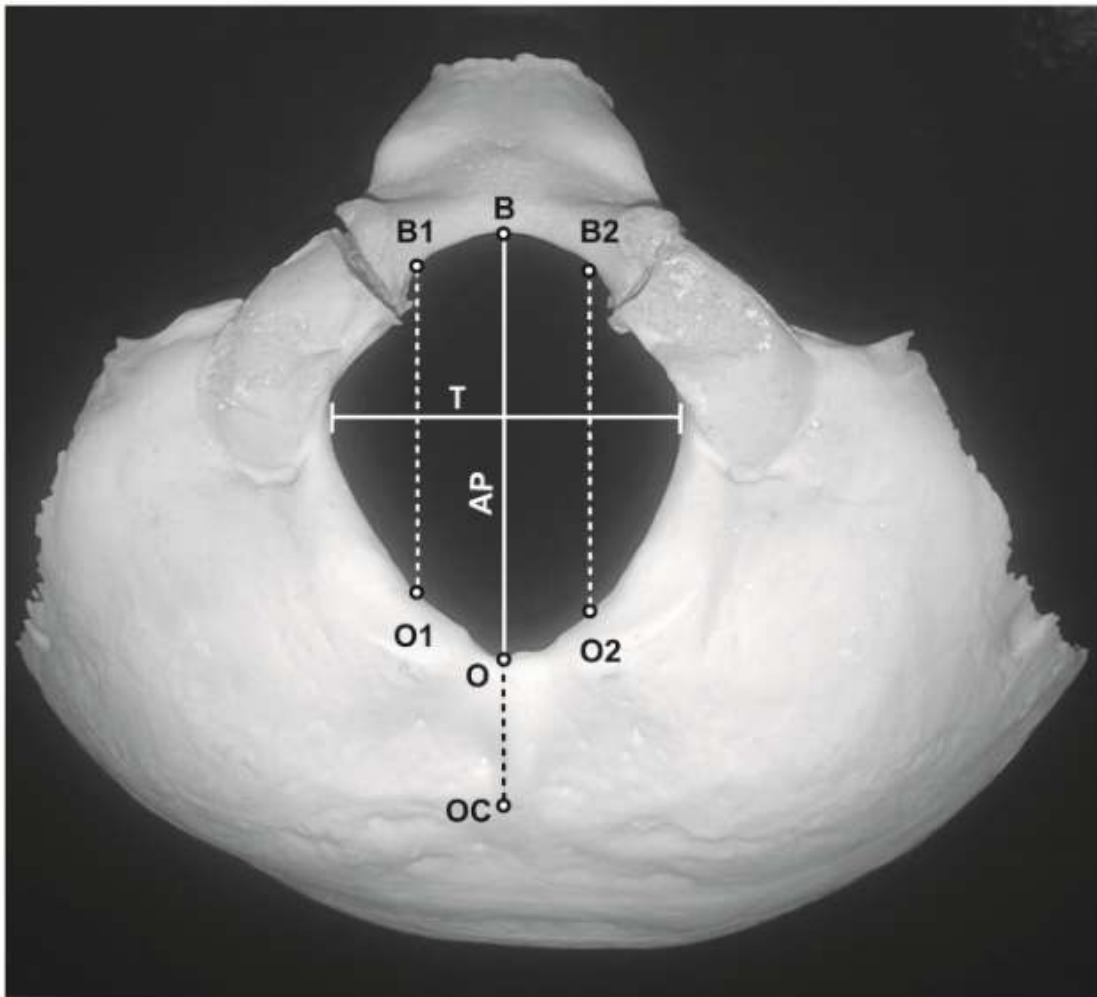


Figure 1. Diameters and measurement points at the margin of the foramen magnum (FM) and the basilar portion of the occipital bone. AP, antero-posterior diameter; B, measurement point at the basion; B1 (B2), paramedial measurement points on the anterior margin of the FM; O, measurement point at the opisthion; O1 (O2), paramedial points on the posterior margin of the FM; OC, measurement point located 2cm posterior to opisthion; T, transverse diameter.

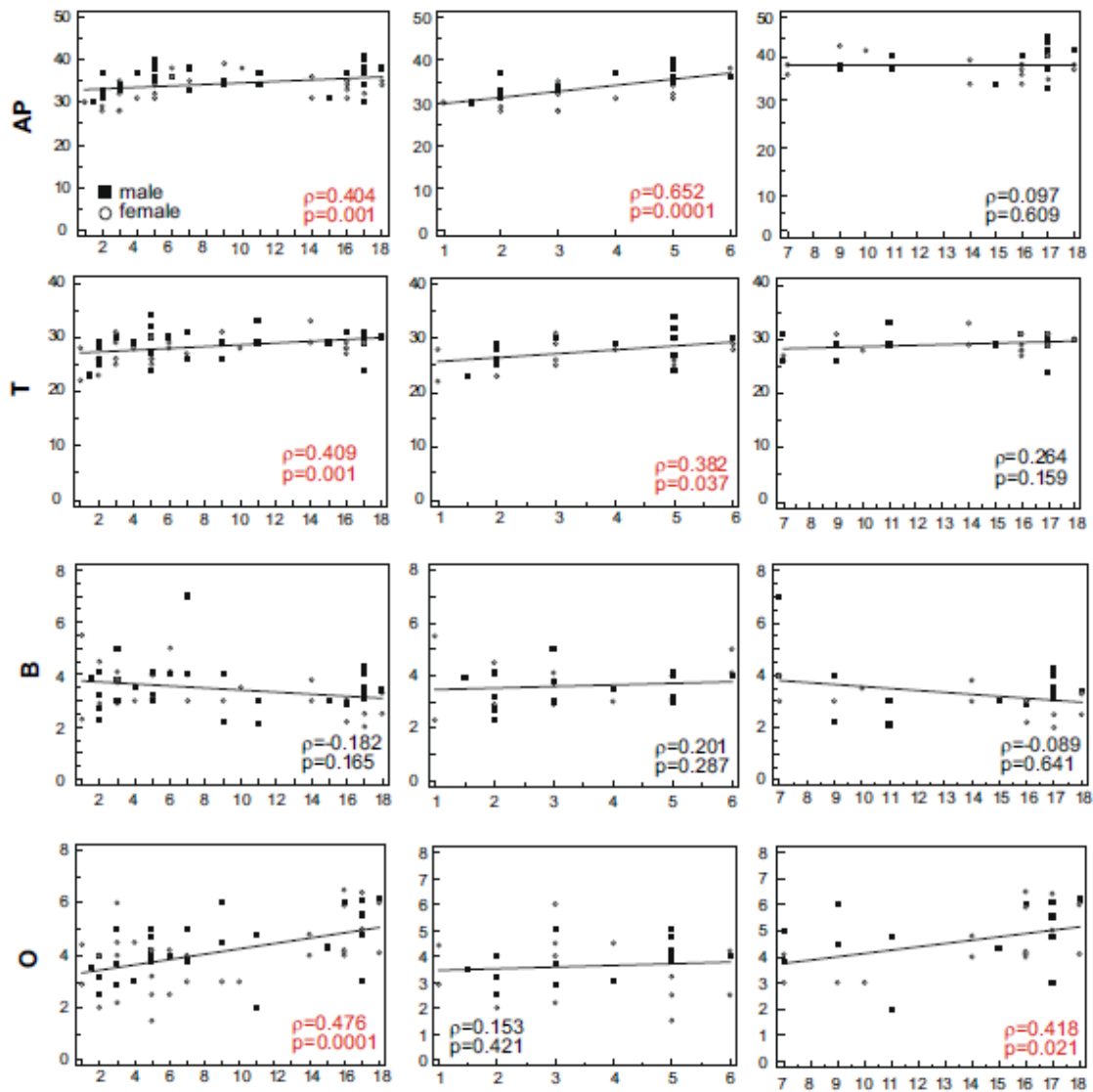


Figure 2. Representative scatter plots of variables showing different pattern of correlation with age depending on the observed age group. Left column, all subjects, middle column, subjects aged 6 years and less; right column, subjects aged 7-18 years. Spearman's correlation coefficient (ρ) and significance (p) values are included in plots. AP, antero-posterior diameter (mm); B, bone thickness measured at the basion (mm); O, bone thickness measured at the opisthion (mm); T, transverse diameter (mm).

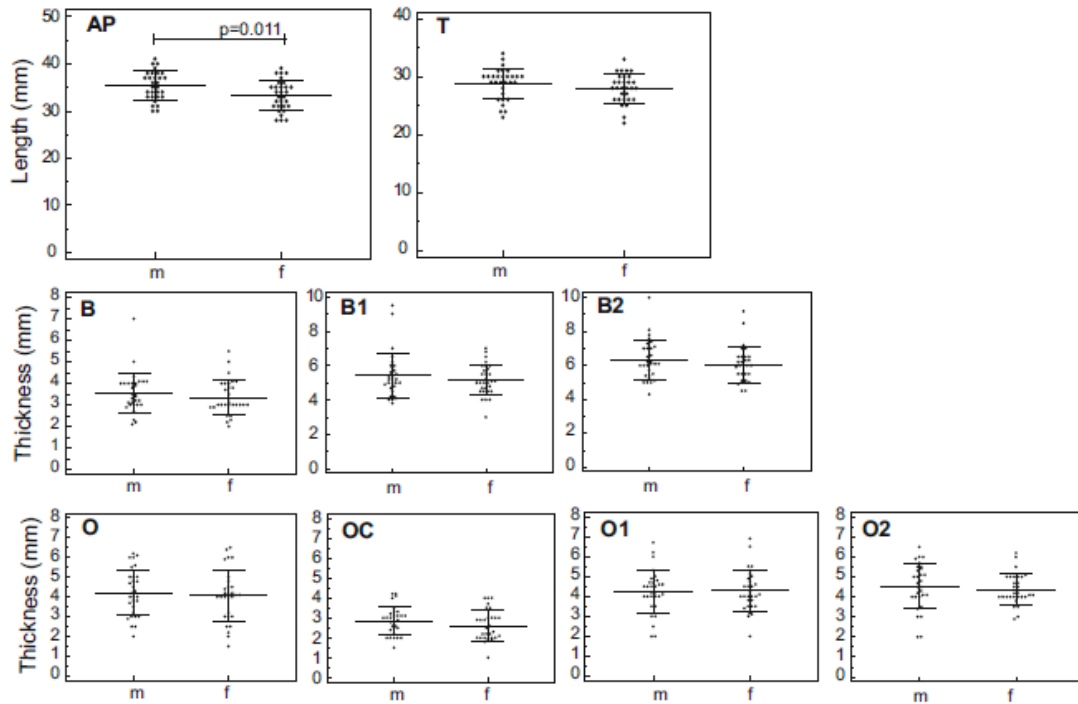


Figure 3. Diameters and bone thicknesses in male and female subjects. AP, antero-posterior diameter (mm); B, bone thickness measured at the basion (mm); B1 (B2), bone thickness measured at paramedial points of the anterior margin of the FM (mm); O, bone thickness measured at the opisthion (mm); O1 (O2), bone thickness measured at paramedial points of the posterior margin of the FM (mm); OC, bone thickness measured 2 cm posterior to the opisthion (mm); T, transverse diameter (mm). Horizontal line, mean value; error bars, standard deviation.