

Carcinoma of left colon presenting as mechanical obstruction in a patient with osteogenesis imperfecta type III

Augustin, Goran; Jelinčić, Željko; Majerović, Mate; Štefančić, Ljiljana

Source / Izvornik: **Journal of Inherited Metabolic Disease, 2007, 30, 109 - 110**

Journal article, Accepted version

Rad u časopisu, Završna verzija rukopisa prihvaćena za objavljivanje (postprint)

<https://doi.org/10.1007/s10545-006-0438-1>

Permanent link / Trajna poveznica: <https://um.nsk.hr/um:nbn:hr:105:508156>

Rights / Prava: [In copyright](#)/[Zaštićeno autorskim pravom.](#)

Download date / Datum preuzimanja: **2024-08-28**



Repository / Repozitorij:

[Dr Med - University of Zagreb School of Medicine
Digital Repository](#)





Središnja medicinska knjižnica

Augustin, G., Jelinčić, Ž., Majerović, M., Štefančić, Lj. (2007) *Carcinoma of left colon presenting as mechanical obstruction in a patient with osteogenesis imperfecta type III*. Journal of Inherited Metabolic Disease, 30 (1). pp. 109-110.

The original publication is available at www.springerlink.com

<http://www.springerlink.com/content/yt804440270130gh/>

<http://dx.doi.org/10.1007/s10545-006-0438-1>

<http://medlib.mef.hr/291>

University of Zagreb Medical School Repository

<http://medlib.mef.hr/>

Carcinoma of left colon presenting as mechanical obstruction in a patient with osteogenesis imperfecta type III

Images in metabolic medicine

G. Augustin, Z. Jelincic, M. Majerovic, LJ. Stefancic

Goran Augustin, MD (corresponding author)

Department of Surgery, Division of Abdominal Surgery, University Hospital Center Zagreb

Address: Marohniceva 6, 10000 Zagreb, Croatia

E-mail: gaugustin@inet.hr

Phone: 00385915252372

Zeljko Jelincic, MD

Department of Surgery, Division of Abdominal Surgery, University Hospital Center Zagreb

Address: Kispaticева 12, 10000 Zagreb, Croatia

Mate Majerovic, MD, Ass. Prof.

Department of Surgery, Division of Abdominal Surgery, University Hospital Center Zagreb

Address: Kispaticева 12, 10000 Zagreb, Croatia

Ljiljana Stefancic, MD

Department of Anesthesiology, University Hospital Center Zagreb

Address: Kispaticева 12, 10000 Zagreb, Croatia

Word counts: 244

Number of figures: 3

Any of colour pictures may be used for the front cover of the issue in which the article appears

IMAGES IN METABOLIC MEDICINE

A 44-year-old premenopausal white woman with osteogenesis imperfecta (OI) type III was admitted for signs of colon obstruction (Fig. 1). Plain abdominal radiographs revealed dilated loops of colon and small intestine. Single-contrast barium enema (Fig. 2) delineated the anal canal and distal rectum with contrast stopping at the pelvic inlet. On operation dilated colon and rectum were identified up to the peritoneal fold with significant pelvic stenosis as a cause of obstruction. Further examination revealed a mass on the splenic flexure of the colon (Fig. 3). The Hartmann procedure (resection of the colon containing the tumor with formation of colostomy) was performed. Intraoperative bleeding was more prominent and could be due to underlying connective tissue alterations rather than a primary platelet disorder (Hathaway and Solomons 1972). Wound healing was normal but stomal prolapse of 40 cm was found. It was unlikely to be attributed to technical error because an experienced colorectal surgeon undertook the initial operation. Prolapse could have been due to loss of tensile strength of the connective tissue. Scott and Stris reported that surgical scars in OI individuals tend to stretch under traction and are apparently weaker than those of normal individuals (Scott and Stris 1953). The prolapsed segment was resected and a new stoma created. This is the first known case of OI with mechanical obstruction within the colon itself. This case emphasizes that obstruction in patients with OI is almost always due to progressive pelvic stenosis but colorectal evaluation is necessary because of potential underlying malignant disease.

References

Hathaway WE, Solomons CC (1972) Platelet function and pyrophosphates in osteogenesis imperfecta. *Blood* **39**: 500-509.

Scott D, Stris G (1953) Osteogenesis imperfecta tarda: a study of 3 families with special reference to scar formation. *Acta Med Scand* **145**: 237-240.

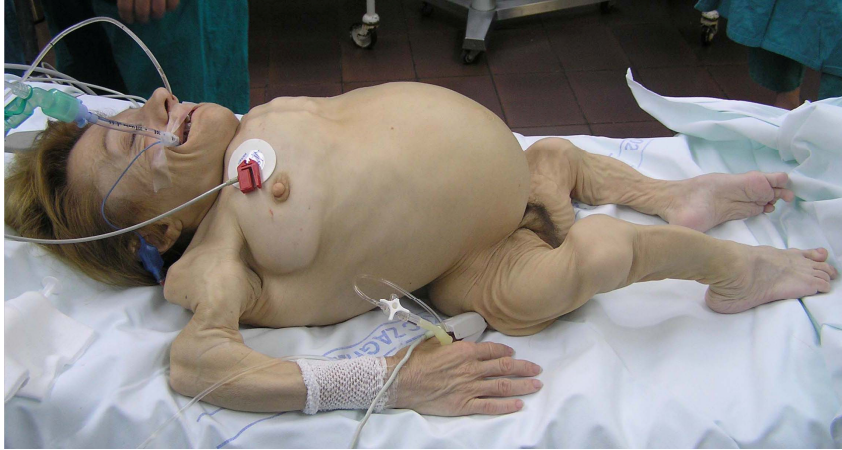

Fig. 1 Abdominal distension in a 44 years old woman with colon obstruction and osteogenesis imperfecta type III

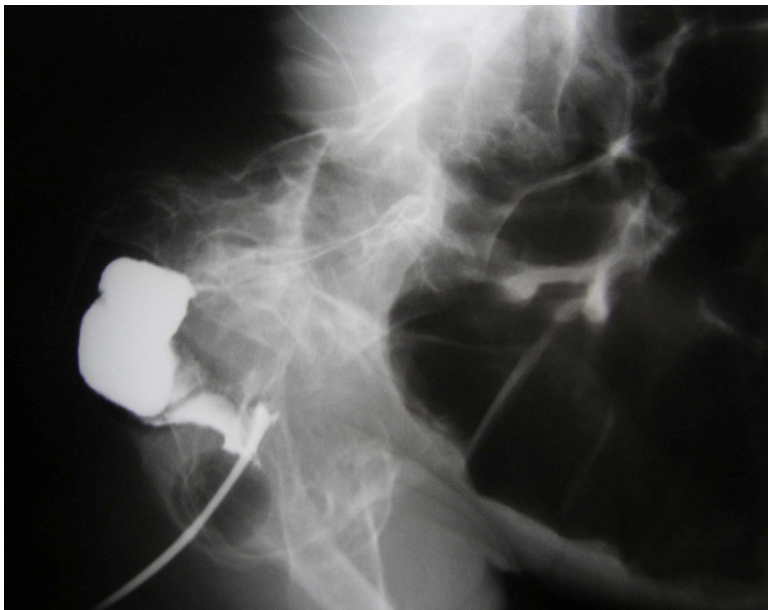


Fig. 2 Single-contrast barium enema show Foley catheter and contrast delineating anal canal and distal rectum with the stop of contrast

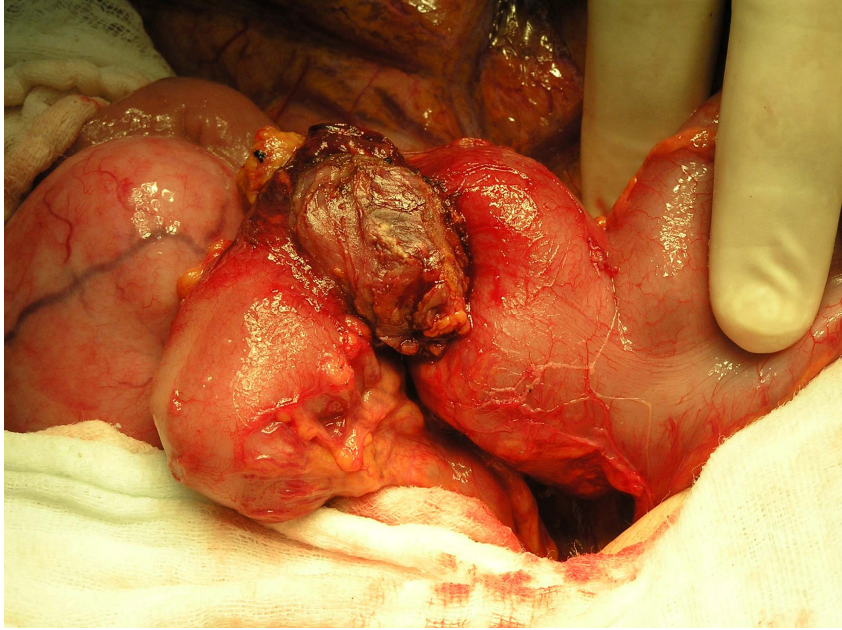


Fig. 3 Photograph showing obstructing lesion of splenic flexure of the colon as a cause of large bowel obstruction. Note that colonic segment distal to this lesion has similar diameter as colon proximal to this lesion which is a result of pelvic stenosis at the level of the rectum