

# Intracranial epidural haematoma following surgical removal of a giant lumbosacral schwannoma: a case report and literature review.

---

Nemir, Jakob; Peterković, Vjerislav; Trninić, Ines; Domazet, Ivan; Barić, Hrvoje; Vukić, Miroslav

Source / Izvornik: **Pediatric Neurosurgery, 2018, 53, 89 - 93**

Journal article, Accepted version

Rad u časopisu, Završna verzija rukopisa prihvaćena za objavljivanje (postprint)

<https://doi.org/doi: 10.1159/000481916>

Permanent link / Trajna poveznica: <https://um.nsk.hr/um:nbn:hr:105:701465>

Rights / Prava: [In copyright](#)/[Zaštićeno autorskim pravom.](#)

Download date / Datum preuzimanja: **2024-08-21**



Repository / Repozitorij:

[Dr Med - University of Zagreb School of Medicine](#)  
[Digital Repository](#)





## Središnja medicinska knjižnica

**Nemir J., Peterković V., Trninić I., Domazet I., Barić H., Vukić M.**  
**(2018) *Intracranial epidural haematoma following surgical removal of a giant lumbosacral schwannoma: a case report and literature review.***  
***Pediatric Neurosurgery*, 53 (2). pp. 89-93. ISSN 1016-2291**

<https://www.karger.com/journal/home/224273>

<http://dx.doi.org/10.1159/000481916>

<http://medlib.mef.hr/2929>

University of Zagreb Medical School Repository

<http://medlib.mef.hr/>

**Intracranial Epidural Haematoma Following Surgical Removal of a Giant Lumbosacral Schwannoma: A Case Report and Literature Review**

**Jakob Nemir<sup>a\*</sup>, Vjerislav Peterković<sup>a</sup>, Ines Trninić<sup>b</sup>, Ivan Domazet<sup>a</sup>, Hrvoje Barić<sup>a</sup>, Miroslav Vukić<sup>a</sup>**

<sup>a</sup>Department of Neurosurgery, University Hospital Center Zagreb, Zagreb University School of Medicine, Zagreb, Croatia

<sup>b</sup>Department of Neurosurgery, General Hospital Dubrovnik, Dubrovnik, Croatia

\*correspondence to: Hrvoje Barić, MD

University Hospital Center Zagreb, Zagreb University School of Medicine, Zagreb  
Croatia, Kispaticeva 12, 10 000 Zagreb (Croatia)

E-mail: hrvoje.baric@kbc-zagreb.hr

## **Abstract**

Postoperative intracranial epidural hematoma (EDH) is an extremely rare complication following spinal surgery, with only a handful of cases described in the literature. We report the case of a 16-year-old girl who underwent a successful subtotal resection of a giant lumbosacral schwannoma (L2-S2 level). Recovery from general anaesthesia was uneventful; however, her neurological status deteriorated rapidly within 24 hours after surgery. A head computed tomography scan revealed a large right frontoparietal EDH with midline shift. An immediate frontotemporoparietal osteoplastic craniotomy and evacuation of the EDH were performed. At one year, the patient had regained full neurological recovery with no radiological signs of growth of the residual tumour.

**Key Words:** Child · Epidural hematoma · Spinal Schwannoma

## **Introduction**

Intracranial epidural hematoma (EDH) generally occurs after head trauma or as a complication of cranial surgery. Spontaneous intracranial EDH can occur in patients who underwent a cranial decompression, or have pericranial infections, coagulation disorders, dural vascular malformations, and cranial neoplasms [1]. Spontaneous (non-traumatic) intracranial EDH is a known but uncommon life-threatening postoperative complication of spinal surgery. We searched the literature for such cases and identified only four reports, of which three were on adolescents. All cases of intracranial EDH after spinal surgery shared incidental dural tears (IDT) and cerebrospinal fluid (CSF) leakage, which are not uncommon in spine surgery [2, 3]. We describe the fifth case of spontaneous EDH following spinal surgery and the first case with lumbosacral pathology. We present a review of the literature and discuss possible causes, prevention, early diagnosis, and treatment of this rare postoperative complication.

## **Case report**

### *History, clinical examination and workup*

A sixteen-year-old girl with a lumbosacral (L2-S2 level) tumour was admitted to our department for elective surgery. Her symptoms started two years earlier with progressively worsening lower back pain resistant to medication. Six months prior to admission she developed numbness of the gluteal region running into the posterior compartment of the thighs. She had a history of orthopaedic surgery to the spine for thoracolumbar scoliosis. Her medical history was otherwise unremarkable. Preoperative neurological examination revealed bilateral knee flexion contractures, limited lower limb range of motion, hypotrophy of the left extensor digitorum brevis muscle and left gastrocnemius muscle and bilateral hypotrophy and contracture of gluteal muscles. Absent triceps surae reflex and sensory loss in the posterior aspect of the left leg were also verified. The patient did not report any bowel or bladder function loss and preoperative coagulation studies were normal. Electromyoneurography (EMNG) revealed a severe left side L5, S1, and S2 proximal radicular lesion and a mild left L4 and right L5 and S1 radicular lesion. A magnetic resonance imaging (MRI) of the thoracolumbar spine revealed a large intradural tumour extending from L2-S2, which was T1 isointense, T2 hyperintense, and had heterogeneous contrast enhancement with a partial central hypointensity. Subarachnoid space was reduced in the area surrounding the tumour, and CSF was absent. The vertebral laminae adjacent to the tumour were thinned (Fig. 1). Her pre- and postoperative laboratory tests, including coagulation tests, were normal.

### *Surgery*

The patient was operated under general anaesthesia in prone position via a posterior approach with the head positioned in a foam head rest. Preincision intraoperative neuromonitoring was performed, including somatosensory-evoked (SSEPs) and motor-evoked potentials (MEPs). After an X-ray confirmation of the spinal level, a midline skin incision and laminectomy extending from L2 to S2 were performed. Midline durotomy was made and CSF released for local decompression, upon which a large intradural tumor incorporating spinal nerves and extending to S1 and S2 foramina bilaterally was visualized. Signs of dural thinning due to tumour compression were evident. First, the tumour was debulked using a Cavitron Ultrasonographic Surgical Aspirator (CUSA) and then dissected from neural tissue. Subtotal tumour resection was achieved with a small tumor remnant extending deep into the S1 and S2 foramina. Duroplasty was performed using Neuro-Patch<sup>®</sup> and fibrin glue, respectively, and a Hemovac<sup>®</sup> drain was placed into the epidural space. Intraoperative SSEPs and MEPs showed no change compared to baseline. The wound was closed in anatomic layers. Intraoperative blood loss was minimal and there were no complications during or immediately after the procedure. Postoperatively, the patient was admitted to the intensive care unit (ICU), where she recovered neurologically intact.

#### *Complication and management*

Twenty-four hours after surgery the patient was noted as being drowsy and somnolent with an inadequate verbal response. An urgent head computed tomography (CT) scan revealed a large frontoparietal EDH (6 cm x 3 cm) (Fig. 2). The patient underwent an immediate frontotemporoparietal osteoplastic craniotomy and EDH evacuation. A postoperative CT scan showed no residual hematoma or other intracranial complications (Fig. 3) and patient recovered completely.

#### *Follow-up*

Histological, immunohistochemical, and ultrastructural analysis of the spinal tumour sample revealed a schwannoma composed predominantly of Antoni B tissue. First postoperative lumbar MRI performed two months postoperatively revealed a small tumour remnant in the S1-S2 extracanalicular region (Fig. 4). Follow-up evaluation revealed no new deficits on neurological examination. Second postoperative MRI performed one year postoperatively revealed no growth of the residual tumour, postoperative complications or possible signs of a tumour in other regions.

## Discussion

In most cases, EDH is a consequence of head trauma. In-bending of the skull due to a traumatic impact leads to a skull fracture, which can cause epidural bleeding from lacerated meningeal vessels, fractured edges, torn venous sinuses or diploic veins. The decision to operate is based primarily on the patient's Glasgow Coma Score (GCS), pupillary abnormalities, and CT parameters, especially clot thickness, hematoma volume, midline shift, and the status of the basal cisterns. Several published studies have discussed the aetiology of postoperative epidural hematoma. Main possible causes of this unusual phenomenon are pericranial infections (e.g. frontal sinusitis, maxillary sinusitis, otitis media, and craniofacial infections), coagulation disorders, dural vascular malformations and cranial neoplasms [4, 5]. Spinal surgery is associated with a wide range of intraoperative complications including wrong-level surgery, nerve root lesion, vascular injury, and dural tearing [6]. Dural tears are common complications of spinal surgery, with reported incidence rates from 1-17%, which can lead to CSF leakage [6].

In this report we describe a rare complication of spinal tumour surgery. This is the first report of intracranial EDH following surgical removal of giant lumbosacral schwannoma most likely caused by a CSF leak. To the best of our knowledge, only three similar cases of EDH after intradural spinal surgery were reported thus far (Table 1). First is a case of a 15-year-old girl who developed bilateral acute supratentorial epidural hematomas after a resection of a thoracic intradural metastasis via a T4-T5 laminotomy [7]. Second is a case of a 14-year-old girl with bilateral epidural hematomas which occurred after cervical schwannoma surgery [2]. Third is a case of a 14-year-old girl who developed bilateral intracranial EDHs after excision of a C4 subdural schwannoma [8]. In the case of our patient, there were no underlying conditions known to be associated with a risk of postoperative intracranial EDH [2]. A well-known consequence of procedures such as lumbar puncture, myelography, spinal anaesthesia, cranial and spinal surgery is CSF volume depletion which can cause intracranial hypotension (IH). Although IH is a benign clinical condition, sometimes it can lead to serious complications such as acute intracranial subdural hematoma, subarachnoid haemorrhage, and cerebral or cerebellar hemorrhagic infarction. Exact aetiology of intracranial bleeding due to intracranial hypotension is unknown; however, it is plausible that loss of CSF causes a significant drop in intracranial pressure, leading to enlargement of dural venous sinuses, increase in the gradient between intravascular pressure and CSF pressure and, finally, tearing of bridging veins due to caudal brain displacement [9]. It remains unclear which factors and to which extent contribute to development of intracranial EDH after spinal tumour removal; however, the common pattern in all four cases described thus far include a large CSF leak, CSF blockage, female gender, and young age. For some reason, intracranial EDH following spine surgery occurs only in female adolescents. The pathogenesis of EDH in our patient remains unclear. It seems plausible, although highly speculative, that

the CSF leak was aggravated by the Hemovac<sup>®</sup> drain and that the length of duration of the surgery caused a significant IH which in turn caused the ED [9]. ED can occur due to a CSF leak during or after any type of spinal surgery which involves dural tearing or intradural manipulation. Our aim was to report a rare case of EDH following removal of a giant lumbosacral schwannoma. The possibility of EDH should be considered in any patient with unexplainable neurological deterioration who underwent a procedure with a large intra- or postoperative CSF leak.

### **Conclusion**

Postoperative intracranial EDH is a rare but possible complication after spinal tumor surgery. Postoperative neurological deterioration in adolescent patients should raise suspicion of intracranial EDH in case of which an emergent surgical evacuation is mandatory.

### **Ethics Statement**

Written informed consent was obtained from the guardians of the patient for publication of this case.

### **Disclosure Statement**

All authors declare no support from any organisation for the submitted work and relationships or activities that could appear to have influenced the report.

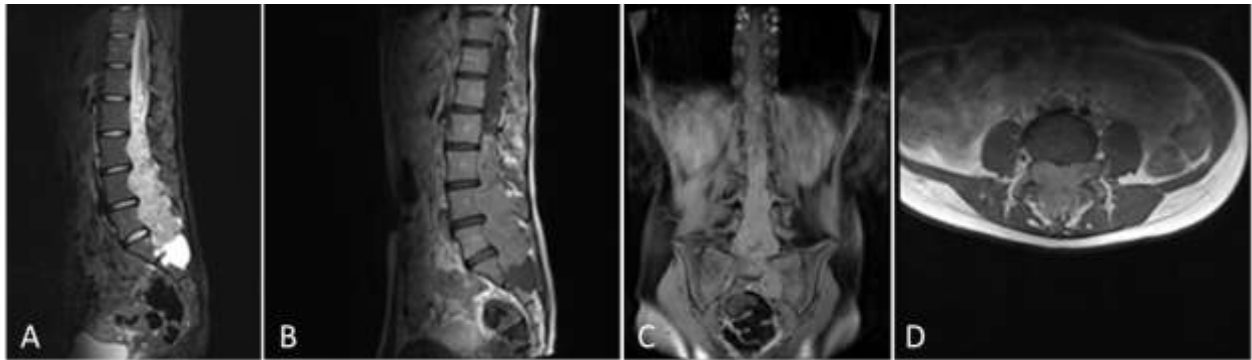


## References

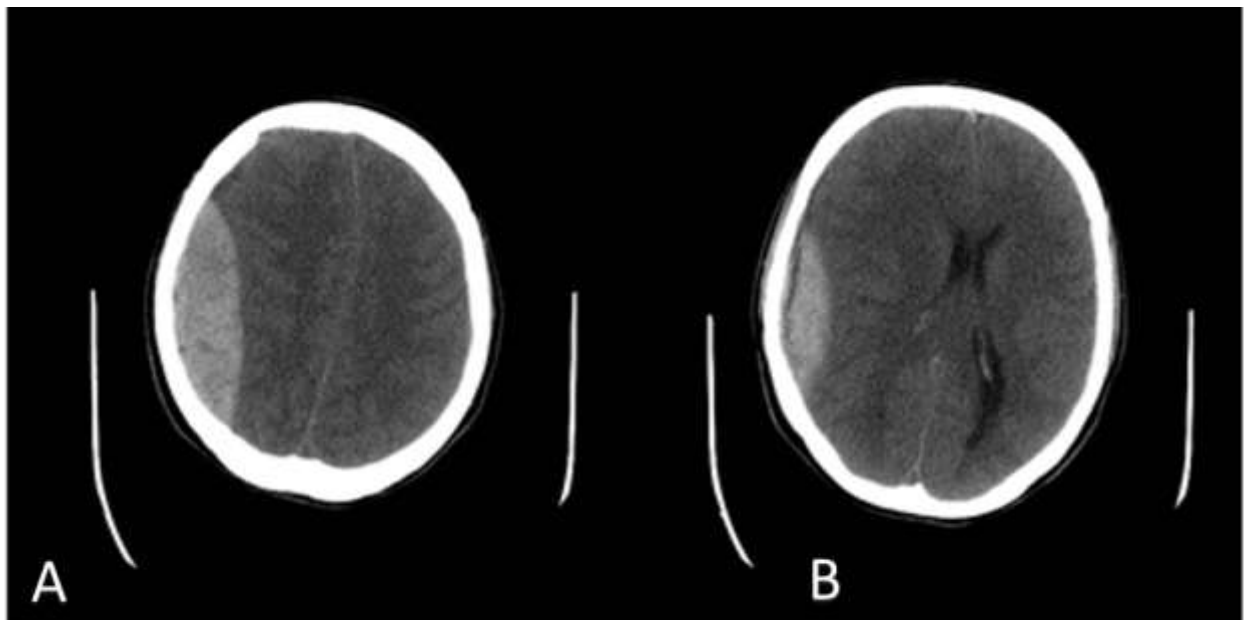
1. Zheng FX, Chao Y: Spontaneous intracranial extradural hematoma: case report and literature review. *Neurol India*. 2009;57:324-326.
2. Li ZJ, Sun P, Dou YH, Lan XL, Xu J, Zhang CY, Wang JP: Bilateral supratentorial epidural hematomas: a rare complication in adolescent spine surgery. *Neurol Med Chir (Tokyo)*. 2012;52:646-648.
3. Khalatbari MR, Khalatbari I, Moharamzad Y: Intracranial hemorrhage following lumbar spine surgery. *Eur Spine J*. 2012;21:2091-2096.
4. Griffiths SJ, Jatavallabhula NS, Mitchell RD: Spontaneous extradural hematoma associated with craniofacial infections: case report and review of the literature. *Br J Neurosurg*. 2002;16:188-191.
5. Hassan MF, Dhamija B, Palmer JD, Hilton D, Adams W: Spontaneous cranial extradural hematoma: case report and review of literature. *Neuropathology*. 2009;29:480-484.
6. Beier AD, Soo TM, Claybrooks R: Subdural hematoma after microdiscectomy: a case report and review of the literature. *Spine J*. 2009;9:E9-E12.
7. Surash S, Bhargava D, Tyagi A: Bilateral extradural hematoma formation following excision of a thoracic intradural lesion. *J Neurosurg Pediatr*. 2009;3:137-140.
8. Ma X, Zhang Y, Wang T, Li G, Zhang G, Khan H, Xiang H, Chen B: Acute intracranial hematoma formation following excision of a cervical subdural tumor: a report of two cases and literature review. *Br J Neurosurg*. 2014;28:125-130.
9. Grahovac G, Vilendecic M, Chudy D, Srdoc D, Skrlin J: Nightmare complication after lumbar disc surgery – cranial non-traumatic acute epidural hematoma. *Spine (Phila Pa 1976)*. 2011;36:E1761-1764.

## Figure legends

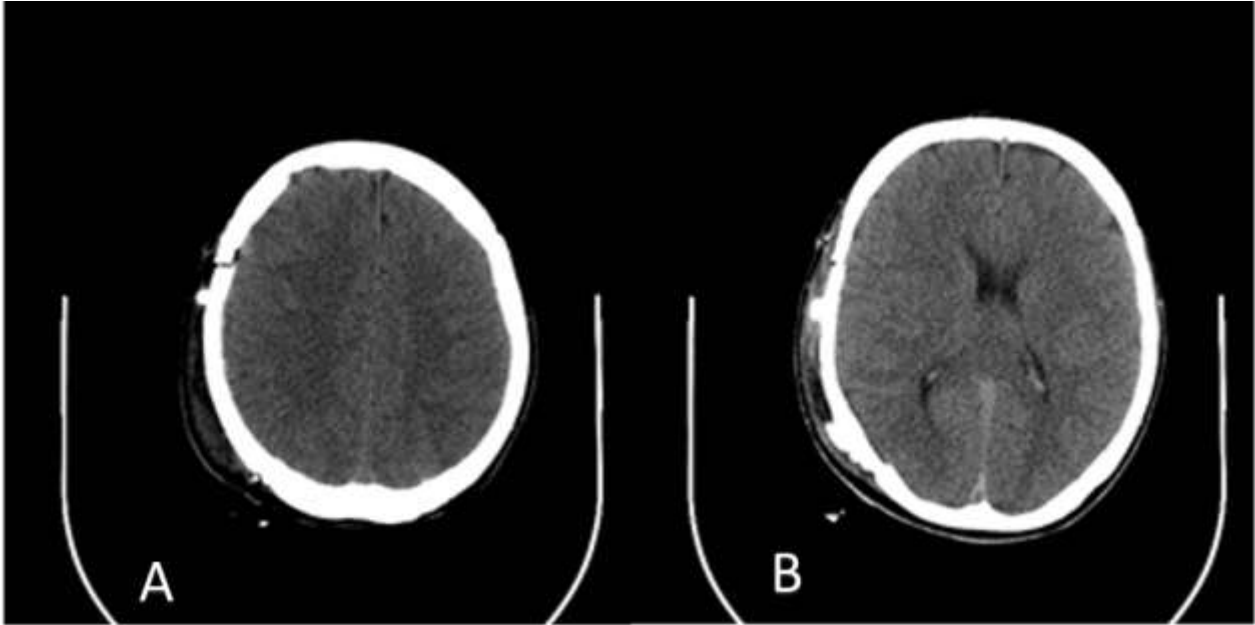
**Fig. 1. a, b** Preoperative MRI. Sagittal plane T1 and T2 images showing a large schwannoma extending from L2-S2; contrast-enhanced images show a large heterogeneous mass with partial central hypointensity. **c, d** Coronal and axial plane contrast-enhanced T1 images showing lateral tumour extension.



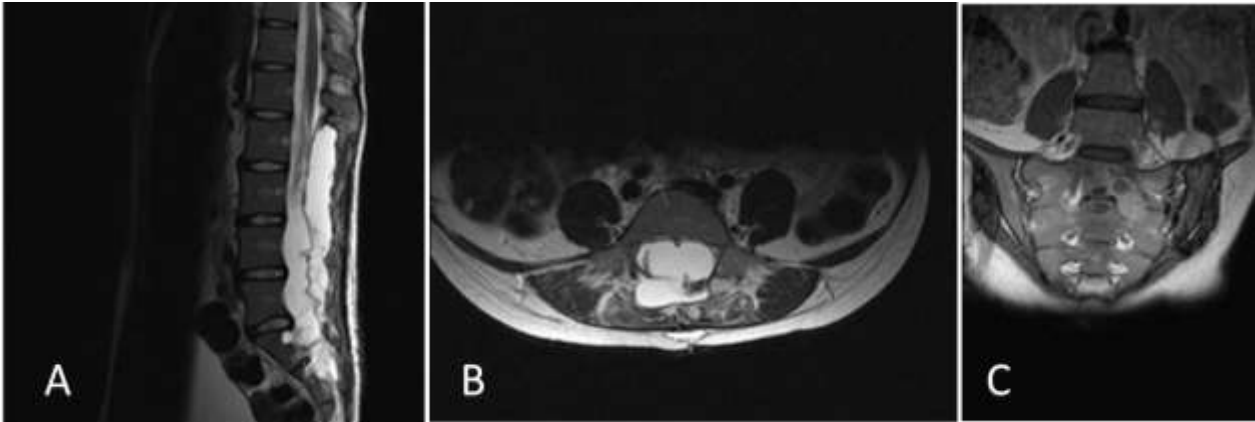
**Fig. 2. a, b** Preoperative CT images showing a right-sided frontoparietal epidural haematoma with mass effect.



**Fig. 3. a, b** Postoperative CT images showing no residual hematoma, or other intracranial complications.



**Fig. 4. a, b** Postoperative MRI. Sagittal and axial T2 images showing the excision cavity and residual CSF collection. **c** Coronal T1 contrast-enhances image showing a small tumor remnant in the S1-S2 extracanalicular region.



**Table 1.** Cases of intracranial epidural hematoma following spinal intradural surgery

Subject no.	First author, year, reference	Subject sex, age (years)	Spinal pathology	EDH location	Note
1	Surash, 2009 [7]	female, 15	T4-T5 extramedullary metastatic medulloblastoma	Bilateral (frontal right, frontoparietal left)	Medulloblastoma of the posterior fossa removed four years earlier
2	Li, 2012 [2]	female, 14	C4 schwannoma	Bilateral parietal	Otherwise healthy
3	Ma, 2014 [8]	female, 14	C4 schwannoma	Bilateral parietal	Otherwise healthy
4	Nemir, 2017	female, 16	L2-S2 schwannoma	Right frontoparietal	Previous surgery for thoracolumbar scoliosis