

Histopathological changes in tracheal mucosa following total laryngectomy

Rosso, Marinela; Prgomet, Drago; Marjanović, Ksenija; Pušeljić, Silvija; Tićac, Robert; Mihaljević, Ivan

Source / Izvornik: **Collegium Antropologicum, 2016, 40, 123 - 126**

Journal article, Published version

Rad u časopisu, Objavljena verzija rada (izdavačev PDF)

Permanent link / Trajna poveznica: <https://um.nsk.hr/um:nbn:hr:105:879363>

Rights / Prava: [In copyright](#)/[Zaštićeno autorskim pravom.](#)

Download date / Datum preuzimanja: **2025-02-18**



Repository / Repozitorij:

[Dr Med - University of Zagreb School of Medicine
Digital Repository](#)



Histopathological Changes in Tracheal Mucosa Following Total Laryngectomy

Marinela Rosso¹, Drago Prgomet¹, Ksenija Marjanović², Silvija Pušeljić³, Robert Tićac⁴ and Ivan Mihaljević⁵

¹ University Hospital Center Osijek, Department of Otorhinolaryngology and Head and Neck Surgery, Osijek, Croatia

² University Hospital Center Osijek, Institute for Pathology and Forensic Medicine, Osijek, Croatia

³ University Hospital Center Osijek, Clinic for Pediatrics, Osijek, Croatia

⁴ University Hospital Center Rijeka, Department of Otorhinolaryngology and Head and Neck Surgery, Rijeka, Croatia

⁵ University Hospital Center Osijek, Clinical Institute of Nuclear Medicine and Radiation Protection, Osijek, Croatia

ABSTRACT

The aim of this study was to determine the long term histopathologic changes in tracheal mucosa after a total laryngectomy, and to find out the relationship between the progression of histopathologic changes in tracheal mucosa and the duration of breathing through the tracheostomy. Tracheal mucosal biopsies were taken from a total of 35 patients, of both sexes, who underwent a total laryngectomy for laryngeal carcinoma at least one year prior. Histologic specimens of tracheal mucosa were stained with hematoxylin and eosin and examined under light microscopy. Almost all of the patients demonstrated histopathologic changes or abnormalities. Based on the results, histological findings were grouped into seven categories: normal respiratory epithelium, mild, moderate and advanced basal cell hyperplasia, squamous metaplasia, and slight and moderate and dysplasia. The time elapsed since surgery was calculated for each histopathological change separately. In laryngeal carcinoma patients, after a total laryngectomy histopathologic changes occur in tracheal mucosa. The mildest histopathological changes are found in the patients who had a longer period between the operation and the examination.

Key words: total laryngectomy, tracheal biopsy, laryngeal cancer, tracheostomy, trachea

Introduction

Total laryngectomy results in a permanent disconnection of the upper and lower airways. Due to this disconnection, upper airways are bypassed, and nasal function in breathing is lost. The conditioning, humidifying and filtering of inhaled air is no longer possible^{1,2}. The absence of upper airway function in people who breathe through the tracheostomy causes various problems: frequent coughing, excess sputum production, crusting, loss of breath, and frequent forced expectoration and cleaning of the lower respiratory tract^{3,4}. These problems increase during the first six months following the laryngectomy, and then tend to stabilize. Frequently, there is an increase of respiratory symptoms in winter^{5,6}. Tracheal mucosa consists of a pseudostratified, ciliated, columnar epithelium with three types of epithelial cells: columnar, goblet and basal cells, and a very elastic lamina propria.

A tracheostomy can cause morphological changes of the lower respiratory tract. In the early postoperative period,

mechanical factors, chemical irritation and infections represent the main causes of tracheobronchial mucosal changes. Postoperative adjuvant oncological treatment further causes histopathological changes. The radiation dose of 1.000 cGy causes inhibition of ciliary activity and permanent damage of the tracheal epithelium⁷. Histopathological changes of tracheal mucosa were correlated with the history of smoking, age, occupation, and site of residence too. Vitamin A deficiency can also result in the replacement of a normal respiratory epithelium with a squamous epithelium⁸⁻¹⁰.

Anatomical and histological changes after a total laryngectomy and tracheostomy can cause a morphological and functional changes in the lower respiratory tract¹¹.

The aim of this study was to determine long term histopathologic changes in tracheal mucosa after a total laryngectomy, and to find out the relationship between the progression of histopathologic changes in tracheal mucosa and the duration of breathing through the tracheostomy.

Materials and Methods

Tracheal mucosal biopsies were taken from a total of 35 patients of both sexes. All of them have underwent a total laryngectomy for laryngeal carcinoma at least one year prior. All patients had received radiotherapy postoperatively. They were heavy smokers. None of the patients had continued to smoke following the laryngectomy. Patients with a history of chronic lung disease before the laryngectomy were excluded from this trial. Biopsies were taken in winter.

The patient’s trachea was sprayed with an anesthetic solution of 10% lidocaine, and with the patient sitting upright, a preliminary fibrobronchoscopy was performed.

Tracheal mucosa biopsies were obtained under direct vision with biopsy forceps, from proximal one third of the trachea, about 4 cm beneath the tracheal stoma. The size of the biopsy specimens was 2-3 mm. Biopsy specimens were fixed in 10% buffered formaldehyde. The samples were dehydrated and embedded in paraffin blocks. Serial 4-7 µm thick tissues were cut and stained with hematoxylin and eosine and examined by a light microscope. Sections were photographed with a photomicroscope.

Statistics

Analyses of clustered data were performed using SPSS version 17.0 (SPSS Inc., Chicago, IL, USA), and the MedCalc version 11.0 (MedCalc Software, Mariakerke, Belgium).

Descriptive statistics included mean and standard deviation (SD) for continuous variables and proportions for categorical variables. Receiver operating characteristic curves were generated and analyzed for the area under the curve for the time elapsed since the laryngectomy by the presence of histological changes.

Results

The study included 35 laryngectomized patients, of whom 1 (2.9%) were women and 34 (97.1%) men, aged

TABLE 1
PATIENT POPULATION (N=35)

Patient characteristics	
Sex – male, N (%)	34 (97.1%)
Sex – female, N (%)	1 (2.9%)
Age, year (X±SD)	63.4±7.2
Years of smoking (X±SD)	38.1±8.9
Daily cigarette consumption (X±SD)	27.0±7.1
Early disease stage, N (%)	1 (2.9%)
Advanced disease stage, N (%)	34 (97.1%)

Continuous variables are represented as mean ± standard deviation

more than 50 years. All of them were heavy smokers. At the time of the diagnosis almost all of them (except one) had advanced (stage III or IV) disease (Table 1).

Based on our results, the histological findings in tracheal mucosa after a laryngectomy and permanent tracheostomy were grouped into seven categories: normal epithelium, mild, moderate and advanced basal cell hyperplasia, squamous metaplasia, and slight and moderate and dysplasia. The time elapsed since surgery was calculated for each histopathological change separately (Table 2).

Complementary ROC analysis was performed for the period from the operation to the examination (follow up period) by the presence of histological changes, and was verified by a field under the curve AUC of 0.65, sensitivity of 95%, specificity of 35%, and the optimal threshold value for time tracking (cut off) histological change is ≤6 years, 95% CI 0.47 to 0.81, z=1.61, p=0.107 (Figure 1).

We found no transformation or milder histologic changes (normal epithelium and basal cell hyperplasia) in patients who underwent a laryngectomy earlier (10-12 years before). One patient who underwent a total laryngectomy 28 years earlier had a normal histologic finding of the tracheal mucosa. We found more serious changes (squamous metaplasia and dysplasia) in patients with a shorter

TABLE 2
PRESENCE OF HISTOPATHOLOGICAL MUCOSAL FINDINGS AND PERIOD BETWEEN THE LARYNGECTOMY AND EXAMINATION FOR EACH FINDING

Findings	N (%) (N=35)	Period between the laryngectomy and examination (years)			
		X±SD	median	minumum	maximum
Normal epithelium	6 (17)	6.0±1.4	6	5	7
Mild basal cell hyperplasia	2 (6)	4.1±1.6	5	1	6
Moderate basal cell hyperplasia	5 (14)	4.0±1.7	5	2	5
Advanced basal cell hyperplasia	2 (6)	4.3±2.2	5	1	6
Squamous metaplasia	12 (34)	4.3±2.1	5	1	7
Slight dysplasia	5 (14)	4.4±1.9	5	1	6
Moderate dysplasia	3 (9)	5.3±1.5	5	4	7
Total	35 (100)				

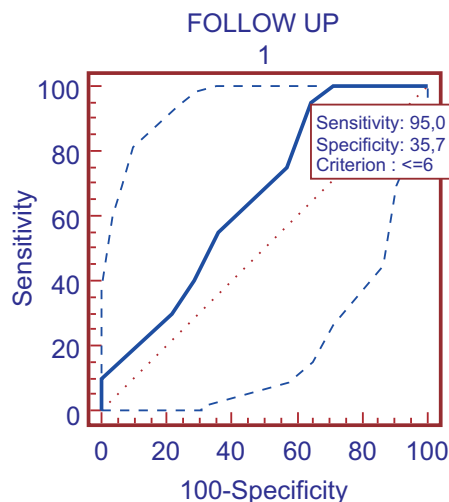


Fig. 1. ROC curve analysis of sensitivity, specificity, and limits for the time that has elapsed since the laryngectomy by the presence of histological changes.

time period (an average of four years) between the operation and the examination.

The study included 35 laryngectomized patients, and based on a limited number of subjects we can notice that the mildest histological changes were in patients who had a longer period between the operation and the examination (10 and more years, average 14).

Discussion

Basal cell hyperplasia is a multiplication of the layers of the basal cell zone. We followed Auerbach's (1956) grading: mild (3-4 layers), moderate (4-6 layers) and advanced (more layers)¹². Squamous metaplasia indicates a change from the ciliated mucous-secreting epithelium to a stratified squamous epithelium. Mild dysplasia (grade I) shows proliferation or hyperplasia of cells of the basal and parabasal layers which does not extend beyond the lower third of the epithelium. Cytological atypia is generally slight with only mild pleomorphism of cells or nuclei. Mitoses are not prominent, and when present are usually basally located and normal. Architectural changes are minimal. Moderate dysplasia (grade II) demonstrates a proliferation of atypical cells extending into the middle one-third of the epithelium. The cytological changes are more severe than in mild dysplasia. Increased and abnormal mitoses may be present. However stratification and maturation are relatively normal. In severe dysplasia (grade III) there is abnormal proliferation from the basal layer into the upper third of the epithelium. Cytological and architectural changes can be very prominent. There is marked pleomorphism often with abnormally large nuclei. Prominent and suprabasal mitoses are usually evident and abnormal tripolar or star-shaped forms may be seen¹³.

Irritation of the tracheal mucosa due to bypasses of the natural air-conditioning function of the upper respi-

ratory tract, a reduced filtering of solid particles and aerosols and inhalation of unhumidified and unheated air results in changes of the normal tracheal epithelium in a vast majority of patients. Manifestations of mucosal dehydration and variable quality of stoma care also play a part¹⁴.

In our study, in twenty-nine of thirty-five (83%) patients normal tracheal epithelium was changed. Basal cell hyperplasia of some degree was found in nine cases. In two of them it was mild, in five moderate, and in two advanced. Squamous metaplasia was most often encountered. It was present in twelve of the thirty-five cases. The lamina propria beneath the metaplastic epithelium often shows evidence of chronic inflammation: lymphocytes infiltration, fibrosis and increased vascularity. It is generally agreed that squamous metaplasia involving the lower respiratory tracts represents an abnormal finding. Keratinisation of the squamous epithelium has not been noted. Dysplasia was found in eight cases. Five of them were slight, and three moderate. The degree of dysplasia is the best guide to potential progression of epithelial lesions, but dysplasia itself may not always be a reliable marker. Squamous metaplasias, varying degrees of dysplasia and carcinomas in situ (CIS) are generally regarded as immediate precursor lesions of invasive carcinoma, and it should allow a clear separation between patients who need follow up and treatment to prevent progression towards malignancy and those for whom no treatment is needed¹³.

We found areas showing intense proliferative changes, but in none of them we were satisfied that all the criteria of severe dysplasia or carcinoma-in-situ have been fulfilled.

Chronic inflammatory changes were present in 31 patients. Inflammation of the tracheobronchial tree has long been known to cause alterations in lining epithelium.

All of the above changes may be interpreted as being in response to abnormal stimulation. The difficulty lies in determining the nature of the stimulus.

The interval of time required for the development of these changes is unknown. In this series the interval between the laryngectomy and biopsy varied from 2 to 28 years.

We must mention that patients who have had one cancer are much more prone to develop a second primary in different sites. Patients with head and neck carcinomas are at high risk for developing second primary lung cancer, and in laryngeal carcinoma patients an increased incidence of metaplasia and dysplasia of the tracheobronchial mucosa might be a predisposing factor in carcinoma of the lung¹⁵.

Conclusion

In the recent past, the main attention of postlaryngectomy rehabilitation has been given to voice rehabilitation, and relatively little attention has been paid to pulmonary rehabilitation according to the literature. The present ob-

servations are sufficient to show that stoma breathing can take place in the tracheal mucosa of laryngectomized subjects. Lung diseases are the second leading cause of mor-

tality in laryngectomized patients. There is a need for further research with the aim of improving lung health in laryngectomees.

REFERENCES

1. MASSON ACC, FOUQUET ML, GONCALVES AJ, Pro-Fono R. *Atual. Cient*, 20 (2008) 141. DOI: 10.1590/S0104-56872008000300001. — 2. SCHEENSTRA RJ, MULLER SH, VINCENT A, HILGERS FJM, *Head Neck*, 33 (2011) 117. DOI: 10.1002/hed.21408. — 3. ACKERSTAFF AH, HILGERS FJM, BALM AJM, VAN ZANDWIJK N, *Clin. Otolaryngol.*, 22 (1995) 547. DOI: 10.1111/j.1365-2273.1995.tb01599.x. — 4. SAYED SI, MANIKANTAN K, KHODE S, ELMIYEH, KAZI R, *G Ital Med Lav Ergon*, 31 (2009) 21. — 5. ACKERSTAFF AH, HILGERS FJM, MEEUWIS CA, KNEGT PPM, WEENINK C, *Clin. Otolaryngol.*, 24 (1999) 491. DOI: 10.1046/j.1365-2273.1999.00298.x. — 6. HILGERS FJM, ACKERSTAFF AH, AARONSON NK, SCHOUWENBURG PF, VAN ZANDWIJK N, *Clin. Otolaryngol.*, 15 (1990) 421. DOI: 10.1111/j.1365-2273.1990.tb00494.x. — 7. ROESSLER F, GROSSENBACHER R, WALT H, *Laryngoscope*, 98 (1988) 1261. DOI: 10.1288/00005537-198811000-00020. — 8. HAMILTON JD, SEPP A, BROWN TC, MACDONALD FW, *Can Med Assoc J*, 77 (1957) 177. — 9. BERTRAM JF, ROGERS AW, *Br Med J*, 283 (1981) 1567. DOI: org/10.1136/bmj.283.6306.1567. — 10. KNUDTSON KP, *Am J Clin Pathol*, 33 (1960) 310. — 11. GRIFFITH TE, FRIEDBERG SA, *Ann Otol Rhinol Laryngol*, 73 (1964) 883. — 12. CUNNINGHAM GJ, WINSTANLEY DP, *Ann R Coll Surg Engl*, 24 (1959) 323. — 13. FLESKENS S, SLOOTWEG P, *Head Neck Oncol*, 11 (2009) 22. DOI: 10.1186/1758-3284-1-11. — 14. CASTRO MA, DEDIVITIS RA, MACEDO AG, *Acta Otorhinolaryngol Ital*, 31 (2011) 243. — 15. SPECTOR JG, SESSIONS DG, HAUGHEY BH, CHAO KSC, SIMPSON J, PEREZ CA, *Laryngoscope*, 111 (2001) 1079. DOI: 10.1097/00005537-200106000-00028.

M. Rosso

University Hospital Center Osijek, Department of Otorhinolaryngology and Head and Neck Surgery, J. Huttlera 4, 31000 Osijek, Croatia
e-mail: rossom@net.hr

HISTOPATOLOŠKE PROMJENE TRAHEALNE SLUZNICE NAKON TOTALNE LARINGEKTOMIJE

SAŽETAK

Cilj ovog istraživanja bio je utvrditi kasne histopatološke promjene sluznice traheje nakon totalne laringektomije, te usporediti stupanj progresije histoloških promjena sluznice traheje u odnosu na vrijeme trajanja disanja kroz traheostomu. Biopsijski uzorci sluznice traheje uzeti su od ukupno 35 ispitanika oba spola, kojima je zbog karcinoma larinksa učinjena totalna laringektomija najmanje godinu dana prije istraživanja. Histološki preparati obojeni su hemalaun-eozinom i pregledani svjetlosnim mikroskopom. Gotovo u svih ispitanika došlo je do histopatoloških promjena ili abnormalnosti. Temeljem dobivenih rezultata, histološki nalaz sluznice traheje grupiran je u sedam kategorija: normalni respiratorni epitel, blaga, umjerena i jaka hiperplazija bazalnih stanica, pločasta metaplazija i blaga i umjerena displazija. Vrijeme proteklo od operacije izračunato je za svaku patohistološku promjenu posebno. Kod bolesnika oboljelih od karcinoma larinksa, nakon totalne laringektomije dolazi do histopatoloških promjena sluznice traheje. Najblaže histopatološke promjene nađene su u bolesnika kod kojih je prošlo duže vremensko razdoblje između operacije i istraživanja.