

Colonic duplication in an adult who presented with chronic constipation attributed to hypothyroidism

Kekez, Tihomir ; Augustin, Goran; Hrstić, Irena; Smuđ, Dubravko;
Majerović, Mate; Jelinčić, Željko; Kinda, Emil

Source / Izvornik: **World Journal of Gastroenterology, 2008, 14, 644 - 646**

Journal article, Accepted version

Rad u časopisu, Završna verzija rukopisa prihvaćena za objavljivanje (postprint)

<https://doi.org/10.3748/wjg.14.644>

Permanent link / Trajna poveznica: <https://urn.nsk.hr/urn:nbn:hr:105:068956>

Rights / Prava: [In copyright](#)/[Zaštićeno autorskim pravom.](#)

Download date / Datum preuzimanja: **2024-08-02**



Repository / Repozitorij:

[Dr Med - University of Zagreb School of Medicine
Digital Repository](#)





Središnja medicinska knjižnica

Kekez, T., Augustin, G., Hrstić, I., Smuđ, D., Majerović, M., Jelinčić, Ž., Kinda, E.
(2008) *Colonic duplication in an adult who presented with chronic constipation attributed to hypothyroidism*. World journal of gastroenterology, 14 (4). pp. 644-646.

<http://www.wjgnet.com/1007-9327/14/644.asp>

<http://medlib.mef.hr/327>

University of Zagreb Medical School Repository

<http://medlib.mef.hr/>

Ms No.wjg/2007/010639

CASE REPORT

Colonic duplication in adult presented as chronic constipation attributed to hypothyroidism

Running title: **Colonic duplication in adults**

Authors: Tihomir Kekez, Goran Augustin, Irena Hrstic, Dubravko Smud, Mate Majerovic, Zeljko Jelincic, Emil Kinda

Author affiliations:

Tihomir Kekez
Department of Surgery, Division of Abdominal Surgery
Clinical Hospital Center Zagreb
Kispaticeva 12
10000 Zagreb, Croatia

Goran Augustin
Department of Surgery, Division of Abdominal Surgery
Clinical Hospital Center Zagreb
Kispaticeva 12
10000 Zagreb, Croatia

Irena Hrstic
Department of Internal medicine, Division of Gastroenterology
Clinical Hospital Center Zagreb
Kispaticeva 12
10000 Zagreb, Croatia

Dubravko Smud
Department of Surgery, Division of Abdominal Surgery
Clinical Hospital Center Zagreb
Kispaticeva 12
10000 Zagreb, Croatia

Mate Majerovic
Department of Surgery, Division of Abdominal Surgery
Clinical Hospital Center Zagreb
Kispaticeva 12
10000 Zagreb, Croatia

Zeljko Jelincic
Department of Surgery, Division of Abdominal Surgery
Clinical Hospital Center Zagreb
Kispaticeva 12
10000 Zagreb, Croatia

Emil Kinda, MD
Department of Surgery, Division of Abdominal Surgery
Clinical Hospital Center Zagreb

Kispaticeva 12
10000 Zagreb, Croatia

Correspondence to: Goran Augustin, Stupnička 6 10000 Zagreb, Croatia.
augustin.goran@gmail.com

Telephone: +385915252372 Fax: +38512421845
Received: October 24, 2007 Revised: November 27, 2007

Abstract

Gastrointestinal duplications are uncommon congenital abnormality in 80% of cases and manifest before the age of 2. Ileal duplication is the most common while colonic duplication, either cystic or tubular, occurs in 10-15% of cases and remains asymptomatic and undiagnosed in most cases. Mostly occurring in pediatric patients, colonic duplication is encountered in adults only in a few cases. The most common clinical manifestations are abdominal pain and intestinal obstruction. Rarely, such duplications present with signs of acute abdomen or acute bleeding. This study reports a case of colonic duplication in adult presented with chronic constipation. Complete diagnostic workup was made in several occasions during 8-years period but no pathology was found and chronic constipation was attributed to hypothyroidism caused by long standing Hashimoto thyroiditis. Multislice CT made because of abdominal distension defined colonic pathology but definite diagnosis of duplication of transversal colon was made at operation. The cystic duplication and the adjacent part of the ascending and transversal colon were excised en-block. The study implies that colonic duplication, though uncommon, should be included in the differential diagnosis of chronic constipation even when precipitating factors for constipation, such as hypothyroidism are present.

Key words: Colonic duplication; Constipation; Abdominal distension; Hypothyroidism

INTRODUCTION

Duplications are rare congenital cystic or tubular abnormalities of the gastrointestinal tract that occur anywhere from the mouth to the anus. Despite a variety of early descriptions, Ladd coined the term *alimentary tract duplications* in 1937, which more effectively described the clinical and pathologic aspects of these lesions^[1]. Their etiology is of embryonic origin and several theories have been proposed. However, none of these theories alone is able to explain the full diversity of these lesions. Although they can present at any age, more than 80% of the cases present before the age of 2 as an acute abdomen or bowel obstruction^[2]. Colorectal duplications occur in 13% of these cases^[3]. If encountered incidentally, these lesions should be surgically addressed to avoid any future complications^[4,5].

We report a case of colonic duplication in adult woman presented with distended abdomen and chronic constipation attributed to long standing hypothyroidism.

CASE REPORT

A 42-year old woman was admitted to division of gastroenterology with symptoms of significant abdominal distension and chronic constipation. The patient had a medical history

of chronic constipation from the early childhood which was not striking until 1991 when, during gestation, significant gaseous bowel distention was found. Complete diagnostic workup was made to find the cause for constipation but all findings were normal. The constipation was attributed to hypothyroidism caused by long standing Hashimoto thyroiditis treated with thyroid hormone replacement. In 1999 the symptoms progressed and again complete diagnostic workup was made. The diagnosis was elongated colon (dolichocolon). During these 8 years the patients used cathartics, different types of tea and manual stool evacuation. There were periods of 7 days without stool evacuation. The patient got used to irregular bowel habits and after 1999 did not went to regular controls. Finally in the last few months in 2006 she noticed significant abdominal distension and consulted the gastroenterologist. Complete laboratory findings, including proteins, albumins, IgA, IgM, IgG, T3, T4 and TSH were normal. ECG and esophagogastroduodenoscopy were normal. Plain X-rays of the abdomen showed extremely dilated intestinal loop presumably colon with fecal masses without signs of obstruction (Figure 1). Colonoscopy revealed normal mucosa with few biopsies showing chronic nonspecific colitis. Anal manometry showed: lower mean resting pressure (50 mm Hg), normal squeeze pressure (200 mm Hg), normal rectal sensation, rectal compliance and recto-anal inhibitory reflex. Conclusion was that there were no elements for Hirschprung's disease and that internal anal sphincter showed slight hypofunction. Multislice CT with peroral contrast showed enormously dilated intestinal loop from diaphragm to pelvis, measuring 36 cm in length with the diameter of 11 cm occupying complete abdominal cavity in the midline (Figure 2). Stomach, rectum and genitourinary tract were normal. There were no enlarged lymph nodes. The patient was transferred to Department of surgery and indicated exploratory laparotomy revealed colonic duplication of transversal colon with no other intra-abdominal pathology (Figure 3). Duplication was separated by sharp dissection from the left half of the transversal colon but shared common wall with the right half of the transversal colon. The duplication ended blindly at the splenic flexure and had opening that communicated with normal colon at the hepatic flexure (Figure 4). Finally, right hemicolectomy was made. The patient functioned well postoperatively and few months after the procedure did not have any stool evacuation difficulties as encountered preoperatively.

DISCUSSION

Gastrointestinal duplications are rare congenital anomalies which are in 80% of the patients detected prenatally or in the first 2 years of life, but can remain undetected until older age^[6]. The clinical picture varies according to location, size, and other factors such as the presence of ectopic mucosa within the duplication, communication with adjacent bowel, or inflammation. The duplications are classified according to their location (ileum 30%, ileocecal valve 30%, duodenum 10%, stomach 8%, jejunum 8%, colon 7%, rectum 5%), shape: cystic ($\geq 80\%$) or tubular^[7]. The most common clinical manifestations are abdominal pain and intestinal obstruction. Rarely, such duplications present with signs of acute abdomen or acute bleeding^[8]. Pyloric and duodenal duplications can mimic hypertrophic pyloric stenosis or a choledochal cyst^[5,9,10]. An ovarian cyst should be considered in female patients, and adolescent patients can sometimes have a presumptive diagnosis of Crohn's disease. Ultrasound is the imaging modality of choice for the evaluation of an abdominal mass in the neonate. Approximately 30% of the intestinal duplications are diagnosed prenatally^[11]. Additional imaging procedures are often required: barium enema, CT scan, radionuclide scan (HIDA scan for choledochal cyst and pertechnetate scan for Meckel's diverticulum). However, gastric, duodenal, and rectal duplications can lead to a diagnostic dilemma.

Chronic constipation as a presenting symptom of intestinal duplication in the adult present specific diagnostic problem because of wide variety of etiologic factors. The cause of constipation is usually multifactorial. Secondary constipation could be caused by low fiber

diet, anal fissures, thrombosed hemorrhoids, strictures, and tumors, hypercalcemia, hypokalemia, hypothyroidism, diabetes mellitus, pregnancy, stroke, Hirschsprung disease, Parkinson disease, multiple sclerosis, spinal cord lesion, Chagas disease, and familial dysautonomia, scleroderma, amyloidosis, and mixed connective-tissue disease and use of different drugs. Functional constipation could be caused by repressed defecatory urge, irritable bowel syndrome, idiopathic megacolon or megarectum, idiopathic slow transit constipation, chronic intestinal obstruction, anismus, solitary rectal ulcer, intussusception, descending perineum, rectocele or ineffective straining.

Intestinal duplications often require urgent surgical intervention. Secretion of ectopic gastric mucosa causes ulceration of the intestinal mucosa, which can lead to massive bleedings or bowel perforation^[12]. Gastric mucosa was found in 50.8% of cystic duplications and was present in all locations, including the colon and rectum with somewhat lower frequency of 33%^[3].

Colorectal duplications represent 13% of all duplications^[3]. Tubular duplications of the colon, may appear in a double-barreled or Y-shaped form^[13,14]. These congenital anomalies have a double muscular layer and epithelium similar to the rest of the colon^[13,15]. The clinical signs include constipation, vomiting, volvulus, perforation, and, most commonly, intestinal obstruction owing to the blind end of the duplication compressing the normal bowel^[13,14,16]. If there are no other associated malformations, tubular duplications of the colon are often not discovered until there is surgical treatment for the complications.

Most authors recommend that once the diagnosis is made, an elective surgical procedure should be performed to avoid complications and to perform the procedure in an optimal state of the patient, but few think that only symptomatic duplications should be surgically treated. The recommended surgical procedure is excision of the duplication. Intestinal duplications are located on the mesenteric side adjacent to normal bowel. Some duplications and the adjacent normal bowel share part of the muscular coat and the intestinal straight arteries. Thus, resection of both normal and duplicated bowels with intestinal anastomosis is a usual surgical treatment^[17]. Sometimes it is possible to resect them without compromising the adjacent bowel vascularization. Although there have been some malignant changes reported in adults^[18], colorectal duplications are in themselves benign lesions. For this reason, surgical excision should not be radical but complete resection of the duplication along with the part of colon involved should be made^[4]. Although rare, colorectal duplications are one possible cause of chronic constipation and, when discovered, should be surgically treated before complications arise. According to previous studies, surgical resection should extend at least 2 cm from the opening of the duplication because substantial fibrotic changes near the opening of the duplication were found^[4,13]. Prognosis is good because of localized disease and benign nature of the disease^[4].

REFERENCES

- 1 **Ladd WE**. Duplications of the alimentary tract. *South Med J* 1937; **30**: 363-371
- 2 **Macpherson RI**. Gastrointestinal duplications: clinical, pathologic, etiologic, and radiologic considerations. *Radiographics* 1993; **13**: 1063-1080 PMID: 8210590
- 3 **Puligandla PS**, Nguyen LT, St-Vil D, Flageole H, Bensoussan AL, Nguyen VH, Laberge JM. Gastrointestinal duplications. *J Pediatr Surg* 2003; **38**: 740-744 PMID: 12720184
- 4 **Holcomb GW**, Gheissari A, O'Neill JA Jr. Surgical management of alimentary tract duplications. *Ann Surg* 1989; **209**: 167-174 PMID: 2916861
- 5 **Cavar S**, Bogovic M, Luetic T, Antabak A, Batinica S. Intestinal duplications--experience in 6 cases. *Eur Surg Res* 2006; **38**: 329-332 PMID: 16785732

- 6 **Anderson MC**, Silberman WW, Shields TW. Duplications of the alimentary tract in the adult. *Arch Surg* 1962; **85**: 94–108 PMID: 13861258
- 7 **Stern LE**, Warner BW. Gastrointestinal duplications. *Semin Pediatr Surg* 2000; **9**: 135–140 PMID: 10949423
- 8 **Fotiadis C**, Genetzakis M, Papandreou I *et al.* Colonic duplication in adults: report of two cases presenting with rectal bleeding. *World J Gastroenterol* 2005; **11**: 5072-5074 PMID: 16124070
- 9 **Merrot T**, Anastasescu R, Pankevych T, Tercier S, Garcia S, Alessandrini P, Guys JM. Duodenal duplications: clinical characteristics, embryological hypotheses, histological findings, treatment. *Eur J Pediatr Surg* 2006; **16**: 18–23 PMID: 16544221
- 10 **Lavine JE**, Harrison M, Heyman MB: Gastrointestinal duplications causing relapsing pancreatitis in children. *Gastroenterology* 1989; **97**: 1556–1558 PMID: 2684724
- 11 **Foley PT**, Sithasanan N, McEwing R, Lipsett J, Ford WD, Furness M. Enteric duplications presenting as antenatally detected abdominal cysts: is delayed resection appropriate? *J Pediatr Surg* 2003; **38**: 1810–1813 PMID: 14666474
- 12 **Wardell S**, Vidican DE. Ileal duplication cyst causing massive bleeding in a child. *J Clin Gastroenterol* 1990; **12**: 681–684 PMID: 2266247
- 13 **Correia-Pinto J**, Tavares ML, Monteiro J, *et al.* Neonatal perforation of Y-shaped sigmoid duplication. *J Pediatr Surg* 2001; **36**: 1422-1424 PMID: 11528620
- 14 **Espalieu P**, Balique JG, Cuilleret J. Tubular colonic duplications. A case report and literature review. *Anat Clin* 1985; **7**: 125-130 PMID: 4041270
- 15 **Shin KS**, Lee NH, Kim SY. An unusual case of colonic duplication causing chronic constipation in a child. *J Pediatr Surg* 1999; **34**: 1410-1412 PMID: 10507440
- 16 **Ryckman FC**, Glenn JD, Moazam F. Spontaneous perforation of a colonic duplication. *Dis Colon Rectum* 1983; **26**: 287–289 PMID: 6839901
- 17 **Grosfeld JL**, O’Neill JA, Clatworthy HW Jr. Enteric duplications in infancy and childhood. *Ann Surg* 1970; **172**: 83-90 PMID: 5425820
- 18 **Heiberg ML**, Marshall KG, Himal HS. Carcinoma arising in a duplicated colon. *Br J Surg* 1973; **60**: 981-982 PMID: 4764750

Figure 1 Plain X-ray of the abdomen showing dilated intestinal loop occupying more than half of abdominal cavity filled with fecal masses.

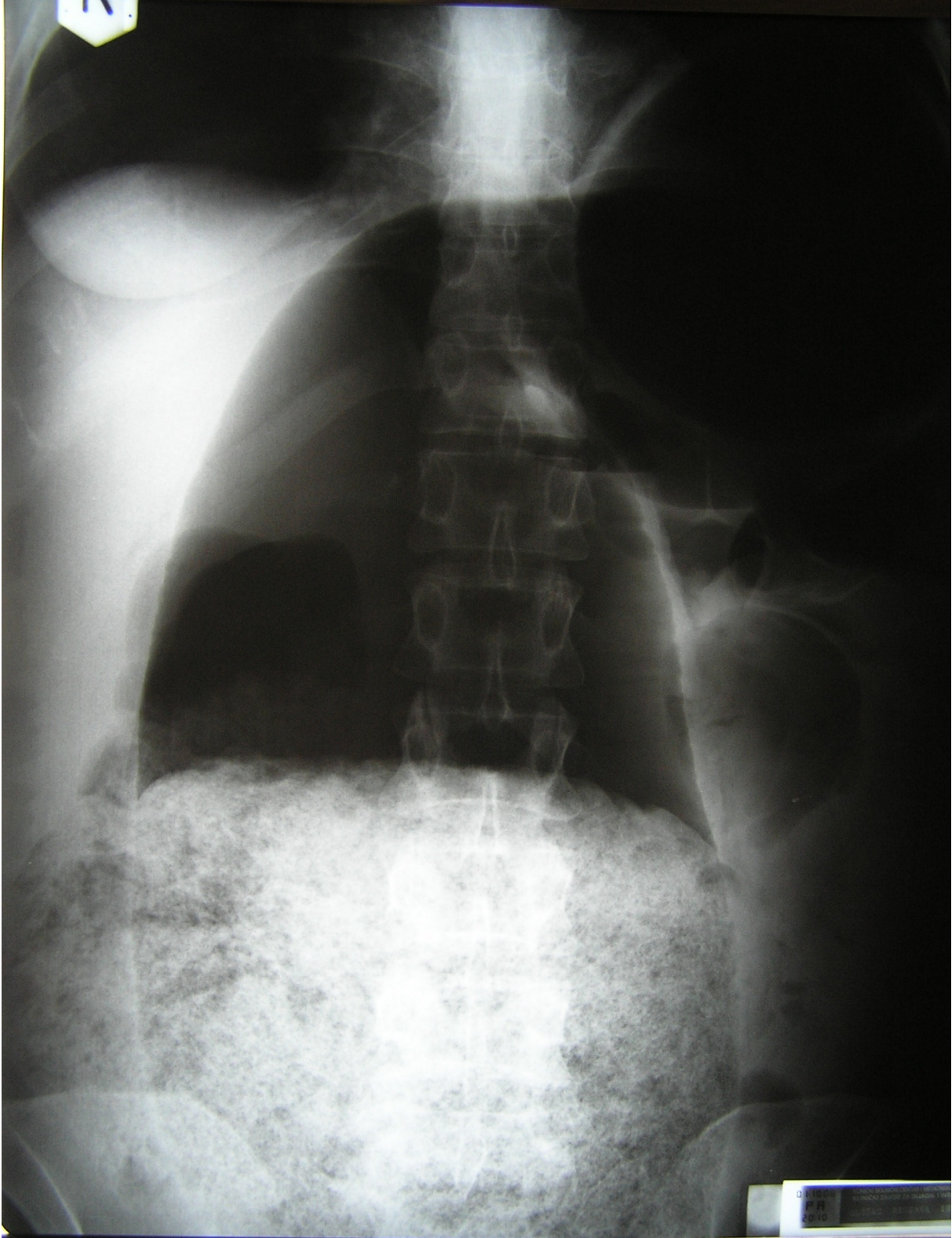


Figure 2 Abdominal CT showing dilated intestine from the diaphragm to the pelvis, measuring 36 cm in length with diameter of 11 cm dislocating normal intestine laterally.

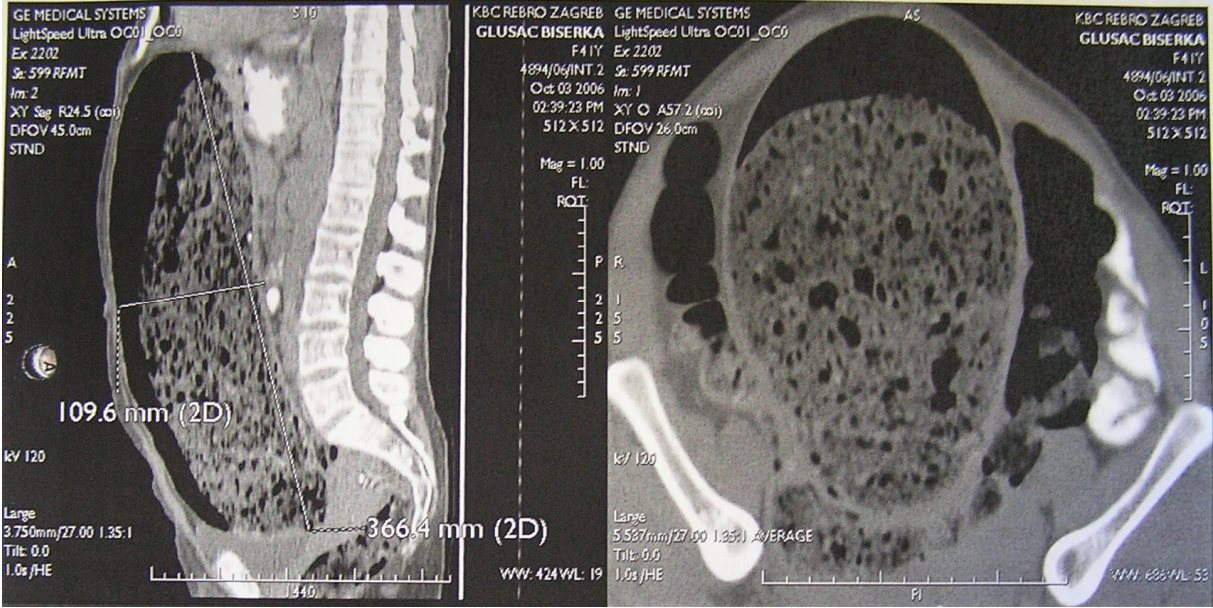


Figure 3 Operative view of normal transversal colon and the distended tubular colonic duplication.

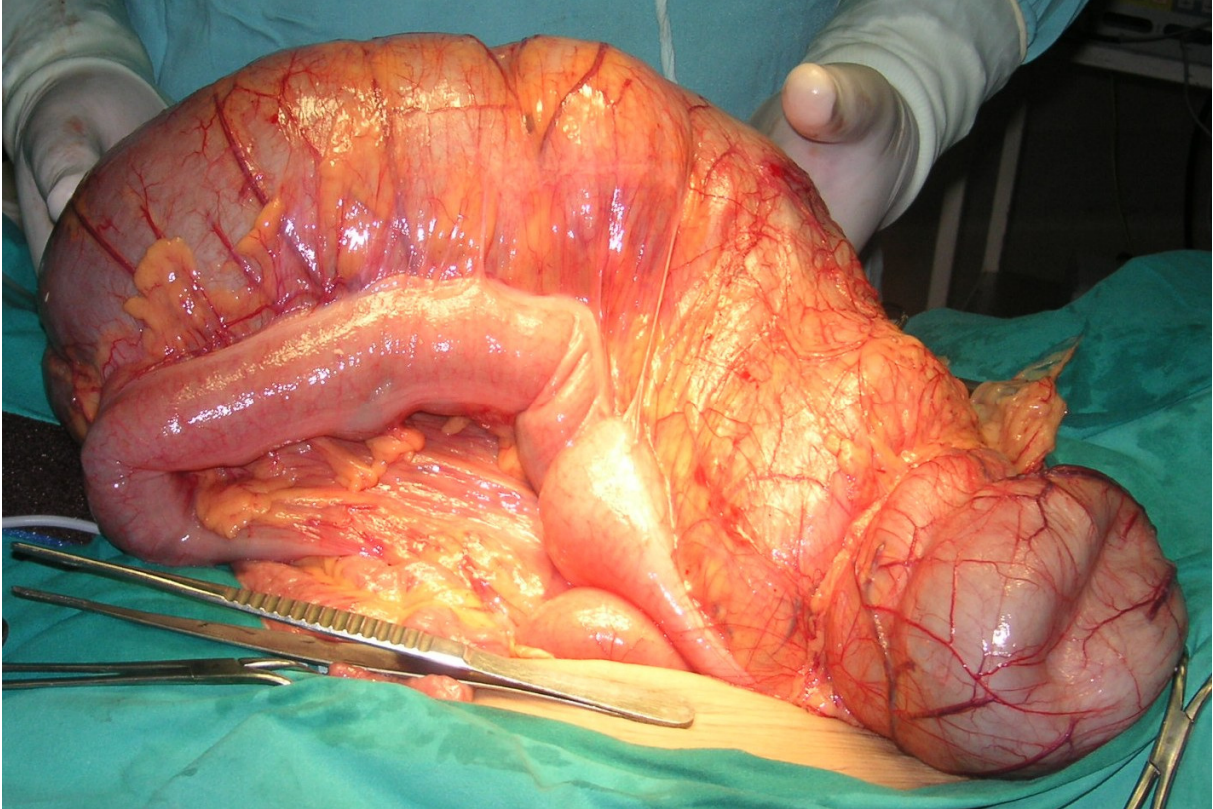


Figure 4 Surgical specimen showing part of the normal ascending and transversal colon together with a tubular duplication with all layers of colonic wall dividing these structures.

