

Etomidate in neuroanesthesia for aneurysmal clipping in child with confirmed allergies to general anesthetics

Stambolija, Vasilije; Miklić Bublic, Martina; Lozić, Marin; Paladino, Josip; Šcap, Miroslav

Source / Izvornik: **Surgical Neurology International, 2018, 9, 200 - 200**

Journal article, Published version

Rad u časopisu, Objavljena verzija rada (izdavačev PDF)

https://doi.org/doi:10.4103/sni.sni_159_18

Permanent link / Trajna poveznica: <https://um.nsk.hr/um:nbn:hr:105:651131>

Rights / Prava: [In copyright](#)/[Zaštićeno autorskim pravom.](#)

Download date / Datum preuzimanja: **2024-12-01**



Repository / Repozitorij:

[Dr Med - University of Zagreb School of Medicine
Digital Repository](#)



Case Report

Etomidate in neuroanesthesia for aneurysmal clipping in child with confirmed allergies to general anesthetics

Vasilije Stambolija, Martina Miklic Bublic, Marin Lozic, Josip Paladino¹, Miroslav ŠcapDepartment of Anesthesiology, Reanimatology and Intensive Care, Division of Neuroanesthesia, University Hospital Centre Zagreb, Zagreb, Croatia,
¹Department of Neurosurgery, University Hospital Centre Zagreb, Zagreb, CroatiaE-mail: *Vasilije Stambolija - vasilije.stambolija@gmail.com; Martina Miklic Bublic - mmbublic@gmail.com; Marin Lozic - marloz40@yahoo.com;
Josip Paladino - josip.paladino@gmail.com; Miroslav Šcap - miroslav.scap@zg-t-com.hr

*Corresponding author

Received: 28 May 18 Accepted: 28 August 18 Published: 03 October 18

Abstract

Background: Etomidate may be given in continuous infusion for maintenance of general anesthesia, although that practice is rarely seen due to beliefs that it has possibility of interfering with cortisol synthesis. However, etomidate is sometimes preferable choice as it has least influence on hemodynamics and rarely causes allergic reactions.

Case Description: We describe a case of 13-year-old boy with aneurysm of left middle cerebral artery, planned for aneurysmal clipping, and previously treated for ruptured aneurysm of right middle cerebral artery. As he was tested and proved allergic to most of the anesthetic drugs, and stable hemodynamic conditions were of most importance during planned neurosurgery, general anesthesia was maintained with etomidate infusion. He was prepared with metilprednisolon, antihistaminic, and ranitidine before the surgery. Cortisol and adrenocorticotrophic hormone levels were measured on three consecutive postoperative days. Only cortisol value, in the morning the day after the surgery, was below reference range, with the values back to normal until that evening. He was dismissed from the intensive care unit with Glasgow Coma Score 15.

Conclusion: Etomidate may be a choice for neuroanesthesia in specific group of people. We have good experience with our algorithm for continuous infusion of etomidate, with serum cortisol values in the reference range, if corticosteroids were not given before the surgery. Administration of metilprednisolon may diminish influence of perioperative stress on cortisol synthesis inhibition.

Key Words: Allergy, aneurysmal clipping, continuous infusion, cortisol, etomidate, neuroanesthesia

Access this article online

Website:www.surgicalneurologyint.com**DOI:**

10.4103/sni.sni_159_18

Quick Response Code:

INTRODUCTION

Etomidate is known as general anesthetic with least influence on hemodynamics. In neuroanesthesia, it has beneficial effect as it also diminishes intracerebral pressure (ICP) and maintains cerebral perfusion pressure (CPP).^[2] That is of greatest importance in urgent situations like in traumatic brain injury where etomidate may reduce ICP without influencing mean

This is an open access journal, and articles are distributed under the terms of the Creative Commons Attribution-NonCommercial-ShareAlike 4.0 License, which allows others to remix, tweak, and build upon the work non-commercially, as long as appropriate credit is given and the new creations are licensed under the identical terms.

For reprints contact: reprints@medknow.com

How to cite this article: Stambolija V, Bublic MM, Lozic M, Paladino J, Šcap M. Etomidate in neuroanesthesia for aneurysmal clipping in child with confirmed allergies to general anesthetics. Surg Neurol Int 2018;9:200.

<http://surgicalneurologyint.com/Etomidate-in-neuroanesthesia-for-aneurysmal-clipping-in-child-with-confirmed-allergies-to-general-anesthetics/>

arterial pressure and enhance CPP, even in pediatric population.^[1] Etomidate may be potentially harmful due to its influence on cortisol synthesis. It is believed that continuous infusion of etomidate has even higher impact on cortisol synthesis.

In spite of the fact that continuous etomidate infusion is usually being avoided, there are research that support use of continuous etomidate infusion for maintenance of general anesthesia. Liu *et al.* suggest maintenance of anesthesia with etomidate infusion in spinal surgery for enabling higher amplitudes when transcranial electrical motor-evoked potentials are recorded.^[7] Continuous etomidate infusion is also recommended for anesthesia in treatment of severe burns^[5] as well as in cardiac surgery.^[3]

Perioperative and surgical stress may overcome cortisol inhibition caused by etomidate^[3] and adrenal insufficiency after continuous infusion of etomidate was not observed in different studies.^[3,5-7]

For patients with allergies, etomidate is beneficial causing the least allergic reactions on induction to general anesthesia.

On induction and maintenance of anesthesia for aneurysmal clipping, it is essential to avoid high oscillations in blood pressure and to maintain neuroprotection.

CASE REPORT

We present a case of a 13-year-old boy, admitted to hospital for planned neurosurgical procedure of clipping aneurysm of left middle cerebral artery (arteria cerebri media [ACM]). He was previously hospitalized for urgent embolization and reembolization of ruptured right ACM (5/2017 and 6/2017). During reembolization, he developed allergic reaction with severe rash after induction of anesthesia. For that reason, clinical allergological testing on different anesthetic drugs was done. After clinical testing, the patient was proved allergic

to midazolam, propofol, fentanyl, sufentanil, sevofluran, thiopental, rocuronium, and vecuronium.

Before new planned aneurysmal clipping, he was prepared with metilprednisolon, antihistaminic, and ranitidine. Preoperative morning cortisol levels were slight higher (742 nmol/L) and adrenocorticotrophic hormone (ACTH) was lower than range (<0.2 pmol/L).

Because of patient's allergy to different drugs used for induction and maintenance of general anesthesia, and due to high demands for hemodynamic stability for aneurysmal clipping, anesthesia was performed with continuous infusion of etomidate and remifentanyl, with scalp block and without use of neuromuscular blocking agents. We had previous good experience with continuous etomidate infusion for total intravenous infusion (total intravenous anesthesia [TIVA]) in neurosurgical patients; so, we decided to use etomidate in this case also.

Our protocol for anesthesia maintenance with etomidate infusion is dose of 100 mcg/kg/min for the first 5 min after anesthesia induction, followed by 60 mcg/kg/min for the next 25 min and then 10 mcg/kg/min until the end of the surgery. The protocol is based on recommendations from other research,^[4] and our clinical experience.

Enhanced anesthetic monitoring was used, with invasive blood pressure and entropy of encephalogram (Datex-Ohmeda S/5 Entropy Module), and the doses of etomidate used in this case enable isoelectric EEG for the time of clipping the aneurysm or burst suppression ratio greater than 70%. The surgery lasted for 4 h. There were no complications, hemodynamic, or any other sequellae during surgical procedure, and afterward, he was placed in neurosurgical intensive care unit (ICU) analgosedated and mechanically ventilated. The patient was awake and extubated 1 h after admittance to ICU and Glasgow Coma Score (GCS) was 15.

Levels of cortisol and ACTH were measured during next three consecutive days. Only one measured cortisol

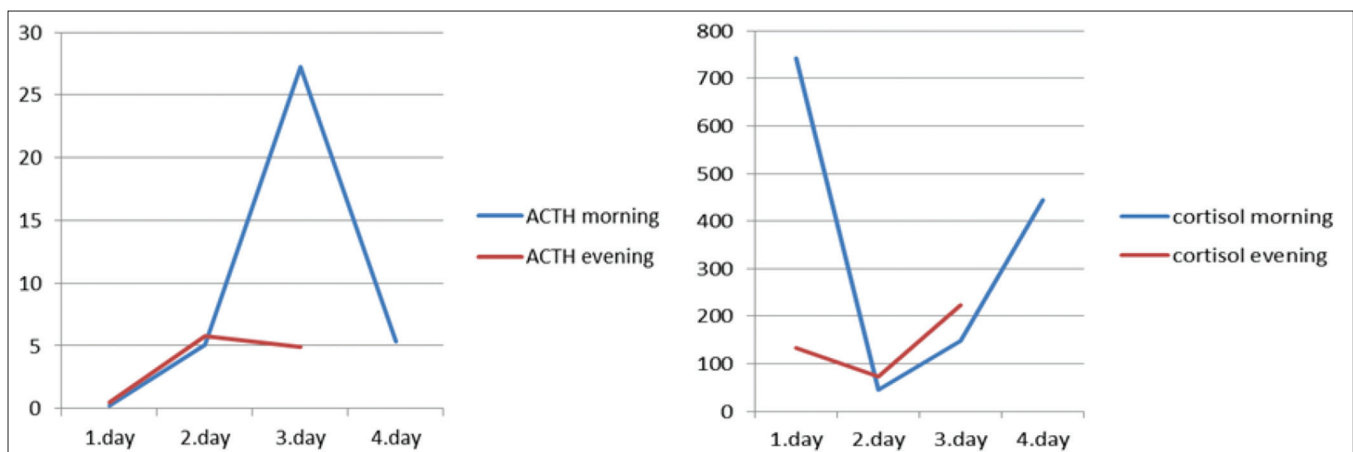


Figure 1: Cortisol and ACTH morning and evening values

value, in the morning the day after the surgery, was below reference range, and the values were back to normal until that evening [Figure 1].

The explanation is more difficult due to the fact that the patient was prepared for the surgery with methylprednisolone because of his allergies which may diminish influence of perioperative stress on cortisol synthesis. ACTH returned to normal after the second day. He was dismissed from ICU on the second day with GCS 15.

DISCUSSION

Etomidate may be a choice for neuroanesthesia in specific group of people, when need for neuroprotection and possible severe allergic reaction surpasses possible detrimental effects of etomidate. We have good previous experience with etomidate in continuous infusion, with serum cortisol values in the reference range, if corticosteroids were not given before the surgery. Some studies even question benefit of high postoperative cortisol values, as they may be related to delayed ischemic neurologic deficit.^[8]

Declaration of patient consent

The authors certify that they have obtained all appropriate patient consent forms. In the form the patient(s) has/have given his/her/their consent for his/her/their images and other clinical information to be reported in the journal. The patients understand that their names and initials will not be published and due efforts will be made to conceal their identity, but anonymity cannot be guaranteed.

Financial support and sponsorship

Nil.

Conflicts of interest

There are no conflicts of interest.

REFERENCES

1. Bramwell KJ, Haizlip J, Pribble C, VanDerHeyden TC, Witte M. The effect of etomidate on intracranial pressure and systemic blood pressure in pediatric patients with severe traumatic brain injury. *Pediatr Emerg Care* 2006;22:90-3.
2. Cold GE, Dahl BL. *Topics in Neuroanaesthesia and Neurointensive Care: Experimental and Clinical Studies Upon Cerebral Circulation, Metabolism and Intracranial Pressure*. Berlin: Springer-Verlag Berlin Heidelberg; 2002.
3. Crozier TA, Schlaeger M, Wuttke W, Kettler D. TIVA with etomidate-fentanyl versus midazolam-fentanyl. The perioperative stress of coronary surgery overcomes the inhibition of cortisol synthesis caused by etomidate-fentanyl anesthesia. *Anaesthesist* 1994;43:605-13.
4. Fragen RJ, Avram MJ, Henthorn TK, Caldwell NJ. A pharmacokinetically designed etomidate infusion regimen for hypnosis. *Anesth Analg* 1983;62:654-60.
5. Guo Z, Pang L, Jia X, Wang X, Su X, Li P, et al. Intraoperative target-controlled infusion anesthesia application using remifentanyl hydrochloride with etomidate in patients with severe burn as monitored using narcotrend. *Burns* 2015;41:100-5.
6. LaRochelle JM, Desselles B, Rossi JL. Continuous-infusion etomidate in a patient receiving extracorporeal membrane oxygenation. *J Pediatr Pharmacol Ther* 2017;22:65-8.
7. Liu HY, Zeng HY, Cheng H, Wang MR, Qiao H, Han RQ, et al. Comparison of the effects of etomidate and propofol combined with remifentanyl and guided by comparable BIS on transcranial electrical motor-evoked potentials during spinal surgery. *J Neurosurg Anesthesiol* 2012;24:133-8.
8. Vergouwen MD, van Geloven N, de Haan RJ, Kruyt ND, Vermeulen M, Roos YB, et al. Increased cortisol levels are associated with delayed cerebral ischemia after aneurysmal subarachnoid hemorrhage. *Neurocrit Care* 2010;12:342-5.