

Reconstructing the life of a Roman soldier buried in Resnik near Split, based on the anthropological analysis of his skeleton

Šlaus, Mario; Domić Kunić, Alka; Pivac, Tara; Adamić Hadžić, Anita

Source / Izvornik: *Collegium Antropologicum*, 2018, 42, 287 - 294

Journal article, Published version

Rad u časopisu, Objavljena verzija rada (izdavačev PDF)

Permanent link / Trajna poveznica: <https://urn.nsk.hr/urn:nbn:hr:105:252223>

Rights / Prava: [In copyright](#)/[Zaštićeno autorskim pravom.](#)

Download date / Datum preuzimanja: **2024-07-23**



Repository / Repozitorij:

[Dr Med - University of Zagreb School of Medicine Digital Repository](#)



Reconstructing the Life of a Roman Soldier Buried in Resnik near Split, Based on the Anthropological Analysis of His Skeleton

Mario Šlaus¹, Alka Domić Kunić², Tara Pivac¹, Anita Adamić Hadžić¹

¹Anthropological Centre, Croatian Academy of Sciences and Arts, Zagreb, Croatia

²Department of Archaeology, Croatian Academy of Sciences and Arts, Zagreb, Croatia

ABSTRACT

Continuous heavy physical labor and the habitual performance of specific actions during everyday activities affects bone and modifies its morphology, particularly if these activities were time consuming and began at an early age. Analysis and interpretation of these changes provides a unique view into the quality of life, the quantity and type of labor, as well as the risks associated with specific occupations or activities. Here we present the results of an anthropological analysis of a skeleton excavated from the antique necropolis in Resnik. Recovered archaeological finds from the grave (a socketed spear head) suggest that the buried individual was in some way related to the Roman army, possibly as a legionary or as a beneficiary. Osteological data from the skeleton was compared to a theoretical and idealized representation of a perfect Roman soldier, as reported by Vegetius Renatus in his work "Summary of military skill" (Epitome rei militaris), in order to reconstruct the life of a real Roman legionary who served in the Roman province of Dalmatia at the end of the 2nd c. AD. The skeleton provides information on general living conditions in the 2nd c. AD, as well as on the specific risks associated with military life. General living conditions include parasitic infestations and subsequent anemia that resulted in numerous viral and bacterial infections, while specific risks related to military life include numerous osteological indicators of physical stress and heavy physical labor. The presences of two remodeled antemortem fractures show that the risk of traumatic injuries was high in Roman soldiers.

Key words: paleopathology, osteological markers of physical stress, trauma analysis, Roman soldier, Croatia

Introduction

Anthropologists have long recognized that the morphology of bone and teeth is modified in individuals who subject their body to everyday arduous physical stress and perform specific, repetitive actions for long periods of time and from a young age. These changes are so obvious that people noted them long before biological anthropology developed as a science. Shakespeare's contemporaries poked fun at weavers because of the chronic ischiatic bursitis many of them suffered from. This painful inflammatory process which in older medical literature is sometimes referred to as "weaver's bottom syndrome" leaves osteologically visible changes in the form of bilateral new hypertrophic bone on the ischial tuberosities. It is the result of long-term (on average more than twelve hours a day) sitting with one leg crossed over the other, that the work carried out on primitive looms required. Probably because of this Shakespeare called the weaver in his comedy "Midsummer night's dream" – Bottom.

Continuous heavy physical labor such as carrying of heavy loads, many types of agricultural work, as well as numerous other activities related to construction work leaves clearly visible changes on bone. Analysis and interpretation of these changes provides insight into the quality of life that a person had, as well as to the quantity of physical stress he was exposed to and the risks that different occupations or activities carried. The latter is particularly important in archaeological contexts as here we are rarely afforded the opportunity to deduce the precise occupation or activity an individual engaged in. A recently excavated skeleton from the small Antique necropolis from Resnik is an exception to this rule. The recovered archaeological material suggests this individual was a soldier, most likely a legionary or beneficiary detached from his legion. Anthropological analysis of his skeleton therefore provides a unique opportunity to reconstruct the life of a Roman soldier from the 2nd c. AD.

During its 1300 years of existence the Roman army changed and evolved. These changes were reflected not only in the organization of the army and the bureaucratic apparatus associated with its functioning, but also in the quality of life and the specific tasks its soldiers performed. One of the best known Antique sources for life in the Roman legion is the work of Publius Flavius Vegetius Renatus' "Summary of military skill" (*Epitome rei militaris*) written at the end of the 4th or the beginning of the 5th c. AD¹. In this military treatise Vegetius, who was not a soldier himself and therefore did not write from personal military experience, combines different information from all periods of the Roman army with the intent of showing what needs to be done in order to revert the Roman army to its former power and glory. This idealized and theoretical representation of a perfect Roman soldier will be compared with the osteological data gathered from the skeleton of the Roman soldier from Resnik in order to reconstruct the quality of life of a real Roman soldier that served in the Roman province of Dalmatia at the end of the 2nd c. AD and see if, and to what degree it differed from Vegetius' ideal perception of a Roman soldier.

Materials and Methods

The small Antique necropolis in Resnik was excavated in 2007. The excavation was carried out by Ivanka Kamenjarin from the Museum of the Town of Kaštela. Eight graves containing the osteological remains of 27 individuals: 11 males, 8 females and 8 subadults, were discovered. The osteological material was carefully collected in individually labeled paper bags, transported to the Laboratory of the Anthropological centre of the Croatian Academy of Sciences and Arts, and carefully cleaned with soft brushes under a weak flow of water, so as not to damage the bone.

The material analyzed in this report comes from grave No. 7. This was a simple inhumation buried directly into earth, with no evidence of grave architecture,

that contained the well preserved skeleton of an adult male (Fig. 1). The skeleton is placed with feet pointing north and the head pointing south. Archaeological material discovered in the grave includes Roman pottery, a Roman coin, a zoomorphic fibula and a socketed spear head. The length of the spear head is 19.5 cm while its cross-section is circular at the beginning and quadratic, with a maximum width of 2.3 cm, at the end. After conservation the Roman coin was identified as an *as* or *dupondius* of Faustina, the wife of Antoninus Pius the Roman Emperor from 138 -161 AD.

The presence of the spear head strongly suggests that the buried individual was in some way related to the Roman army. Because Roman legions are not present in the province of Dalmatia from the end of the 1st c. AD, this individual was probably a beneficiary with previous military service in a Roman legion, most likely on the Roman limes on the Danube. Legionaries with ten or more years of military experience who showed aptitude were seconded from their legion as *beneficiarii consulares* to other provinces where they fulfilled the role of local police officers and superintended the process of collecting taxes². Their life before that was identical to that of all other legionaries.

Results

The skeleton interred in grave No. 7 is that of an adult male aged between 35 to 40 years. Sex and age-at-death were determined using methods described in standard anthropological literature³⁻⁵. All observed pathologies were recorded according to criteria proposed by Ortner⁶. The height of the individual was estimated at 165 (+/- 3.9) cm based on the regression formulae for the femur developed by Trotter & Gleser⁷. The following pathological features are noted in the skeleton.

This individual has deep linear enamel hypoplastic (LEH) defects on the anterior sides of the maxillary incisor crowns. These defects develop during childhood (at

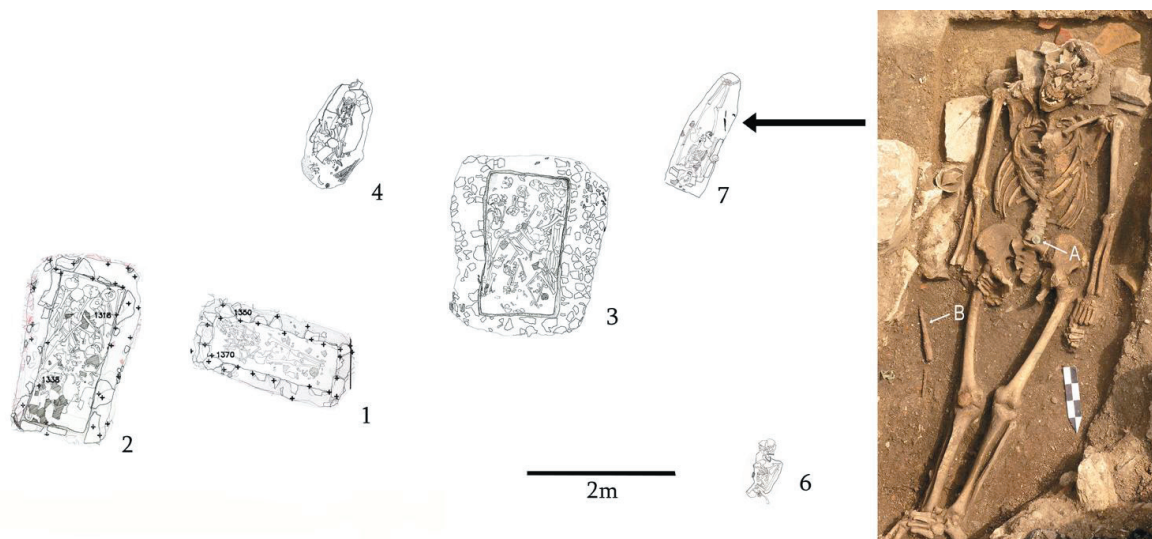


Fig. 1. Plan of the Resnik cemetery with Grave number 7 highlighted. A – Roman coin; B - socketed spear head.

the time that the tooth crowns are being formed, or in this case between the second to fourth years).

LEH or chronological aplasia is generally defined as any macroscopic defect in the enamel surface⁸. The defects appear as band like depressions (linear enamel hypoplasia), or as pits, and have long been used as a nonspecific indicator of systemic physiological stress⁹⁻¹⁰.

Clinical and epidemiological studies have associated LEH with a wide variety of systemic diseases, neonatal disturbances and nutritional deficiencies with among them, importantly, parasitism¹¹, and infectious diseases¹².

The individual from Resnik also exhibits clearly visible porotic changes on both parietal bones of the skull (Fig. 2. A). These changes result from porotic hyperostosis¹³⁻¹⁷. Numerous causal factors have been suggested for porotic hyperostosis including metabolic diseases such as scurvy and rickets, cancer, pressure from binding and carrying, and anemia^{6,15,18-20}. Regardless of the cause, most researchers today concur that porotic hyperostosis is the osseous result of marrow hyperplasia (Trancho, 1987; Stuart-Macadam, 1991; Mittler and Van Gerven, 1994; Larsen, 1997; Fairgrieve and Molto, 2000; but see Ortner et al; 1999; 2001; Schultz, 2001)^{16-17,21-26}.

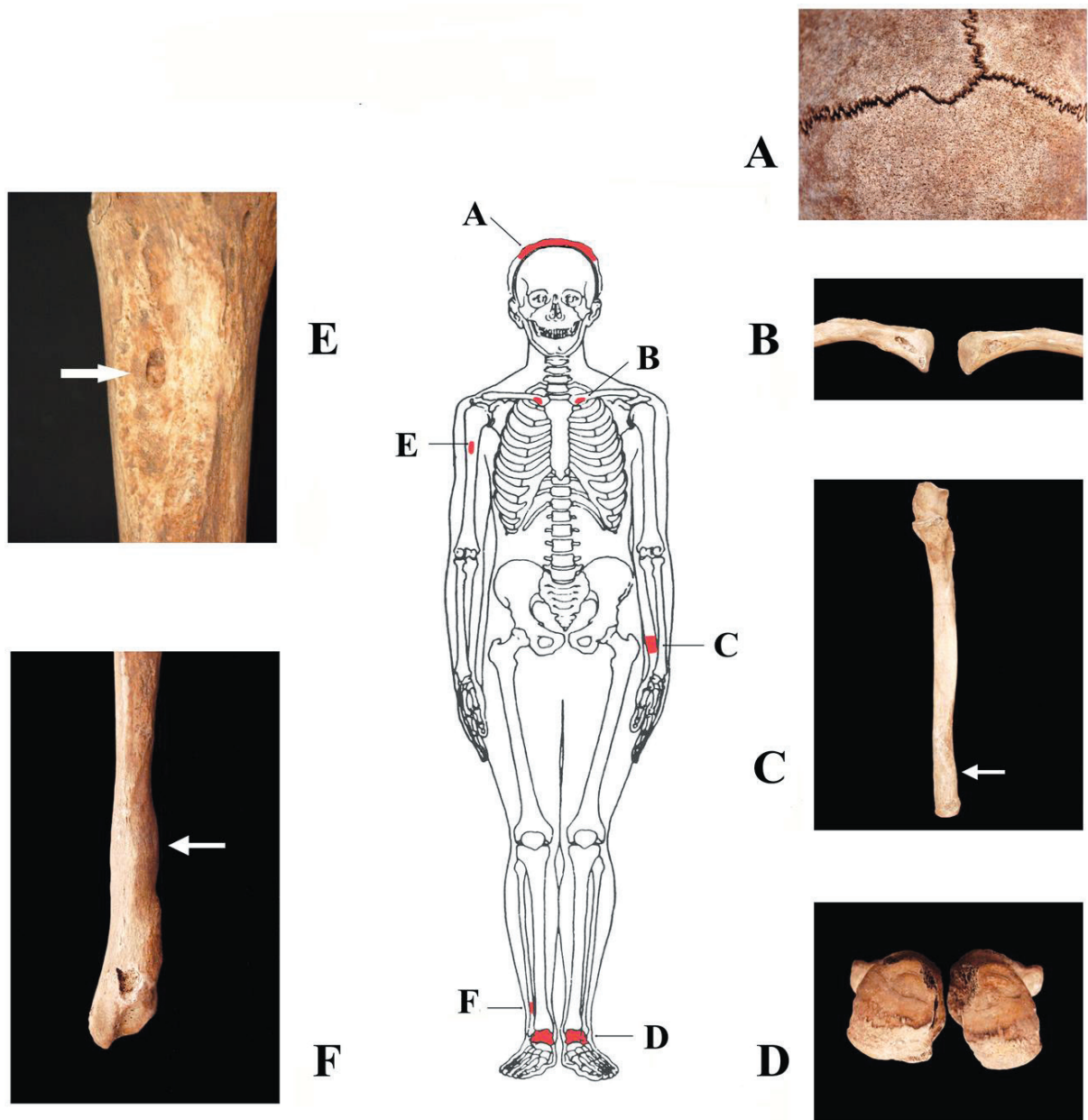


Fig. 2. Pathological changes in the skeleton of the Roman soldier from Resnik. A – Porotic changes on the skull vault; B – large rhomboid fossae on medial clavicles; C – antemortem parry fracture on distal left ulna; D – bilateral new hypertrophic bone at attachment sites of the Achilles tendons; E – benign cortical defect on proximal right humerus; F – antemortem fracture on distal right fibula.

Marrow hyperplasia and its potential skeletal manifestations porotic hyperostosis and cribra orbitalia result from various disease processes. Possible but rare causes include renal osteodystrophy, hereditary spherocytosis, and cyanotic congenital heart disease^{6,19-20, 27}. More common causes consist of genetically inherited forms of anemia such as thalassemia and sickle-cell anemia, and acquired iron-deficiency anemia^{6,23,28-29}. Cumulative evidence from numerous bioarchaeological studies worldwide has resulted in a general consensus linking porotic hyperostosis in archaeological skeletal samples with acquired iron deficiency anemia²³.

The skeleton from Resnik also exhibits healed bilateral periostitis on the tibiae and fibulae.

Non-specific periostitis is a basic inflammatory response that develops because of non-specific bacterial infection⁶ and is macroscopically identified as osseous plaques with demarcated margins or irregular elevations of bone surfaces²³.

Numerous osteological changes related to physical stress are also present in this individual. On the proximal third of the diaphysis of the right humerus there is a shallow defect with a slightly porous floor at the insertion side of the *pectoralis maior* muscle that is generally referred to as a benign cortical defect (Fig. 2. E). Bilateral benign cortical defects are also noted on the inferior-medial parts of both clavicles (Fig. 2. B). These irregular, deep defects are usually called rhomboid fossae in paleopathological literature and are located at the insertion of the costo-clavicular ligament. This individual also has seven Schmorl's defects on his thoracic and lumbar vertebrae, osteoarthritis on two cervical, two thoracic and two lumbar vertebrae, as well as bilateral new hypertrophic bone on the attachment sides of the Achilles' tendons on the posterior parts of the calcanei (Fig. 2. D).

He also exhibits two well healed antemortem fractures. The first is located on the distal part of the left ulna, and is commonly referred to as a "parry" fracture (Fig. 2. C), while the second is located on the distal right fibula immediately above the *facies articularis malleoli fibulae* (Fig. 2. F). Both fractures are well healed, exhibit small calluses, and show no evidence of subsequent infection.

Discussion and Conclusion

The features of this skeleton both correspond to, and differ from Vegetius' portrait of the ideal Roman legionary. Beginning with his height: Vegetius states that a legionary should ideally be 177 to 178 cm tall and that the least acceptable height is 167 cm. The individual from Resnik was shorter than the required minimum but Vegetius, himself, did not attribute too much importance to height suggesting instead that strength and courage could compensate for a lack in height in the legionary. In terms of the type of people who were recruited into the legion Vegetius strongly advocates recruiting men from rural populations. Town dwellers were, according to him, not as vigorous and therefore less able to endure the rigors of

military life that apart from fighting included marching, running and carrying heavy loads. The drawback to recruiting men from rural settings was that because of the poorly developed public sanitation systems in the countryside these individuals frequently suffered from parasitic infections that ultimately resulted in iron-deficiency anemia. This was certainly true for the individual from Resnik who exhibits deep hypoplastic defects on his maxillary incisors as well as porotic bone on his skull vault.

Because there is no osteological evidence of other conditions such as scurvy, cancer, thalassemia or sickle-cell anemia that can mimic the osseous changes resulting from acquired iron-deficiency⁶ we deduce that chronic anemia was the most likely cause of the porotic changes on the skull vault. Chronic anemia inhibits the immunological system of the affected individual and facilitates development of bacterial infections. We know that the individual from Resnik suffered from these, as he had healed periostitis on both his tibiae and fibulae.

Periostitis represents a basic inflammatory response that results not only from non-specific bacterial infection, but also from trauma and from specific infectious diseases such as leprosy, tuberculosis, treponemal disease, and even by conditions such as fluorosis^{6,23}. As there is no skeletal evidence for any of these diseases in the individual from Resnik, and the ante-mortem fracture to the distal part of his right fibula is well healed with a small, barely perceptible callus, and no evidence of subsequent inflammation, the most likely cause of the bilateral periostitis present on his tibiae and fibulae is some type of unidentified bacterial infection.

Vegetius describes how the training of legionaries was prolonged and extensive, based on acquiring physical strength and stamina through the repetition of exercises designed to develop specific skills with defensive and offensive weapons. Strength and general stamina were primarily acquired through marching. In several parts of his text Vegetius stresses the importance of teaching recruits the so-called military pace, which according to him was best done through continuous marching. This pace probably required a continuous speed of 5 to 6 km/h, and to develop the stamina necessary for this recruits marched distances of 29.6 km to 35.5 km in 5 hours or less while carrying on their back loads weighting approximately 20 kg. This included dishes and utensils for preparing meals, woven basket (*cophinus*), an iron chain, leather belt, and the following implements: a saw (*serra*), an axe (*dolabra*), a shovel (*rutrum*), a pickax (*bidens*) and two to four wooden stakes (*sudes*) for fortifying the embankment around the military camp. The equipment would be hung from a stick that was carried over the shoulder. Besides equipment, a legionary would also carry his weapons and armor. The mail armor (*lorica hamata*) usually weighted between 12 to 15 kg, the plated armor (*lorica segmentata*) approximately 9 kg, the helmet (*cassis*) between 2 to 3 kg, the shield (*scutum*) between 5.5 to 7.5 kg, the heavy javelin (*pilum*) approximately 2 kg and the sword (*gladius hispaniensis*) approximately 1 kg. Additionally the sword and sometimes the knife (*pugio*) had scabbards. Therefore, the

total weight of weapons and armor was between 20 to 29 kg which, together with the basic equipment, gave a total weight of between 40 to 49 kg.

The skeleton of the soldier from Resnik clearly shows the consequences of exercising while carrying this amount of weight. There is a large benign cortical defect at the insertion side of the *pectoralis maior* muscle on the right humerus as well as on the attachment sites of the costo-clavicular ligaments of both medial clavicles. Benign cortical defects are musculoskeletal stress markers caused by chronic mechanical stress³⁰. In essence, they are shallow depressions at the insertion sites of muscles and are considered to be reliable indicators of heavy physical labor³¹.

Nowadays benign cortical defects are relatively rare and are generally incidental findings in the X-rays of young athletes. In prehistoric and Antique populations their frequency was much higher because of the lack of labor-saving devices. The predisposing requirements for their development are a restricted series of movements that are energetic and carried out for long periods of time, usually on a daily basis, and from the relatively young age.

The *pectoralis maior* muscle is a strong, broad triangular muscle that inserts on the lateral lip of the intertubercular groove of the humerus. It rotates the upper arm to the front and medially and places it in front of the thorax. If the arm is raised, the muscle pulls it downwards and in front. On the assumption that the soldier from Resnik was, as most people are, right-handed, this muscle participated in almost all exercises: exercising with shield and sword, throwing heavy javelin and firing arrows. The costo-clavicular ligament attaches on the costal impression of the clavicle. It limits elevation of the pectoral girdle and acts as a fulcrum during clavicular elevation³². The etiology of cortical defects is associated with strenuous activity of the pectoral girdle³⁰.

Skeletal changes involving the upper limbs and pectoral girdle have been observed in numerous other archaeological skeleton series. In these studies the recorded changes were associated with long-term and intensive use of paddles and/or oars³³⁻³⁸ and other types of heavy physical labor.

The heavy loads carried by the individual from Resnik most likely facilitated the development of Schmorl's defects on his vertebra. These defects are recognized as shallow, oval or kidney-shaped defects on the superior or inferior surfaces of the vertebra, and result from herniations of the *nucleus pulposus* into the body of neighboring vertebrae.

Bioarchaeological studies suggest that the occurrence and patterning of Schmorl's nodes in archaeological populations is depended on factors including trauma and long-term mechanical loading³⁹⁻⁴³, while modern clinical studies report a wide range of possible causes such as trauma, congenital or developmental defects of the cartilaginous end plate, various forms of metabolic bone diseases, neoplastic disease, degenerative disc disease or lesions of unknown origin⁴⁴⁻⁵⁷. Age, repetitive mechanical loading and

movement are believed to be the main factors influencing the presence and severity of Schmorl's nodes and vertebral osteoarthritis in archaeological populations⁵⁸⁻⁶³ and as there is no osteological evidence for the presence of the trauma or other diseases in the vertebral column of the individual from Resnik it is most likely that they reflect the high levels of mechanical stress his vertebral column was subjected to. Interestingly, high frequencies of Schmorl's defects were also recorded on the vertebra of American soldiers that took part in the siege of Fort Erie in 1812. Historical sources testify that those soldiers were exposed to extreme physical stress that included marching under full military equipment, digging ditches and building fortifications. There is no doubt that the large number of Schmorl's defects in the vertebral column of the soldier from Resnik had a similar etiology. The same is true for the presence of osteoarthritic changes in his thoracic and lumbar vertebra. These changes are common in elderly individuals, but their presence in younger adults suggests heavy mechanical stress on the vertebra column. The osteoarthritic changes on the thoracic and lumbar vertebra most likely reflect the heavy loads the individual from Resnik carried on his back, while the osteoarthritic changes on the cervical vertebra probably resulted from the habitual carrying of heavy legionary helmet.

The presence of new hypertrophic bone on the insertion sides of Achilles' tendons is, similar to vertebral osteoarthritis, also common in elderly individuals. In younger adults such as the individual from Resnik, they suggest chronic micro-traumas of the Achilles' tendon that cause bleeding and inflammation and are most likely the result of prolonged marching, exactly the activity that Vegetius so strongly recommended.

The two healed fractures this individual exhibits demonstrate the risks a soldier faced from both intentional and accidental trauma. The fracture of the distal left ulna is very frequent and is generally referred to as a "parry" or "nightstick" fracture. Its presence is generally explained by the following scenario: in an attempt to defend himself from an attacker who is coming from the front a soldier raises his left arm (his right arm usually holds a weapon), in order to protect his face and head. In this position the ulna is closest to the attacker and therefore absorbs most of the force of the blow. The second fracture on the distal part of the right fibula immediately above the *facies articularis malleoli fibulae* was the result of dislocation of the ankle. Complicated dislocations, accompanied with fractures of the distal fibula, are most likely caused by strong forces that come from the lateral side from the joint and lead to dislocation of the talus. A common scenario for suffering this type of injury is marching or running across uneven terrain, particularly at night and while carrying loads between 40 and 50 kg. Rehabilitation after this type of dislocations is long and usually lasts several months. The absence of an inflammatory process or periostitis of the right fibula of the soldier from Resnik suggests that, despite numerous potential complications, his rehabilitation was complete.

In conclusion, the skeleton of the soldier from Resnik testifies to the general living conditions in the Roman province of Dalmatia during the 2nd c. AD, as well as to the specifics of a legionary's life during this period. The shared features of life between this individual and his community include frequent parasitic infections and the resulting iron-deficiency anemia it caused, as well as the ensuing decreased immunocompetence that resulted in frequent non-specific bacterial diseases. All of these are visible in this individual through dental (hypoplastic defects on the maxillary incisors) and osteological (perio-

stitis on the tibiae and fibulae, and porotic bone on the skull vault) changes.

The osteological features specific for a military lifestyle include numerous osteological indicators of overuse and physical stress (benign cortical defects, humerus and clavicles, the high frequencies of Schmorl's defects and osteoarthritic changes on the vertebral column) as well as the presence of two well healed fractures, one a defensive fracture typical for people engaging in episodes of interpersonal violence, and the other an accidental injury frequent in individuals marching with heavy loads on their backs.

REFERENCES

1. VEGEČIJE, PFR, *Sažetak vojne vještine* (GMTK, Zagreb, 2002) – 2. WILKES JJ, Dalmatia (RKP, London, 1969) – 3. KROGMAN WM, ISCAN MY, *The human skeleton in forensic medicine* (CC Thomas, Springfield, 1986) – 4. BASS WM, *Human osteology. A laboratory and field manual of the human skeleton* (Missouri Archaeological Society, Columbia, 1987) – 5. BUIKSTRA JE, UBELAKER DH, *Standards for data collection from human skeletal remains* (Arkansas Archaeological Survey, Fayetteville, 1994) – 6. ORTNER DJ, *Identification of pathological conditions in human skeletal remains* (Academic Press, San Diego, 2003). DOI: org/10.1016/B978-0-12-528628-2.X5037-6 – 7. TROTTER M, GLEESER GC, *Am J Phys Anthropol*, 10 (1952), 463-514. DOI: org/10.1002/ajpa.1330100407 – 8. PINDBORG JJ, *Pathology of the dental hard tissues* (W. B. Saunders Company, Philadelphia, 1970) – 9. GOODMAN AH, ROSE JC, *Yearb Phys Anthropol*, 33 (1990) 59-110. DOI: org/10.1002/ajpa.1330330506 – 10. GAUTELLI-STEINBERG D, LUKACS JR, *Yearb Phys Anthropol*, 42 (1999) 73-126. DOI: org/10.1002/(SICI)1096-8644(1999)110:29<73::AID-AJPA4>3.0.CO;2-K – 11. SUCKLING G, ELLIOTT DC, THURLEY DC, *Arch Oral Biol*, 31 (1986) 427-439. DOI: org/10.1016/0003-9969(86)90016-6 – 12. PINDBORG JJ, *Int Dent J*, 32 (1982) 123-134. – 13. CARLSON DS, ARMELAGOS GJ, VAN GERVEN DP, *J Hum Evol*, 3 (1974) 405-10. DOI: org/10.1016/0047-2484(74)90203-6 – 14. CYBULSKI JS, *Am J Phys Anthropol*, 47 (1977) 31-40. DOI: org/10.1002/ajpa.1330470108 – 15. STUART-MACADAM P, *Am J Phys Anthropol*, 66 (1985) 391-98. DOI: org/10.1002/ajpa.1330660407 – 16. MITTLER DM, VAN GERVEN DP, *Am J Phys Anthropol*, 93 (1994) 287-97. DOI: org/10.1002/ajpa.1330930302 – 17. FAIRGRIEVE SI, MOLTO JE, *Am J Phys Anthropol*, 111 (2000) 319-31. DOI: org/10.1002/(SICI)1096-8644(200003)111:3<319::AID-AJPA3>3.0.CO;2-N – 18. WILLIAMS HU, *Arch Pathol*, 7 (1929) 839-902. – 19. ANGEL JL, *Science*, 153 (1966) 760-63. DOI: 10.1126/science.153.3737-760 – 20. MOSELEY JE, *Radiographic studies in hematological bone disease: implications for paleopathology*. In: JARCHO S (Ed), *Human paleopathology* (Yale University Press, New Haven, 1966). – 21. TRANCHO G, *Am J Phys Anthropol*, 74 (1987) 511-20. – 22. STUART-MACADAM P, *Anaemia in Roman Britain: Poundbury Camp*. In: BUSH H, ZVELEBIL M (Eds) *Health in past societies. Biocultural interpretations of human skeletal remains in archaeological contexts* (BAR International Series 567, Oxford UK, 1991). – 23. LARSEN CS, *Bioarchaeology: Interpreting behavior from the human skeleton* (Cambridge University Press, Cambridge UK, 1997). (ISBN-13: 978-0521658348) – 24. ORTNER DJ, KIMMERLE E, DIEZ M, *Am J Phys Anthropol*, 108 (1999) 321-31. DOI: org/10.1002/(SICI)1096-8644(199903)108:3<321::AID-AJPA7>3.0.CO;2-7 – 25. ORTNER DJ, BUTLER W, CAFARELLA J, MILLIGAN L, *Am J Phys Anthropol*, 114 (2001) 343-51. DOI: org/10.1002/ajpa.1046 – 26. SCHULTZ M, *Am J Phys Anthropol*, 33 (2001) 106-47. DOI: org/10.1002/ajpa.10024 – 27. BLOM DE, BUIKSTRA JE, KENG L, TOMCZAK PD, SHOREMAN E, STEVENS-TUTTLE D, *Am J Phys Anthropol*, 127 (2005) 152-69. DOI: org/10.1002/ajpa.10431 – 28. TAYLES N, *Am J Phys Anthropol*, 101 (1996) 11-27. DOI: org/10.1002/(SICI)1096-8644(199609)101:1<11::AID-AJPA2>3.0.CO;2-G – 29. HERSHKOVITZ I, ROTHSCHILD BM, LATIMER B, DOTOUR O, LEONETTI G, GREENWALD CM, ROTHSCHILD C, JELLEMA LM, *Am J Phys Anthropol*, 104 (1997) 213-26. DOI: org/10.1002/(SICI)1096-8644(199710)104:2<213::AID-AJPA8>3.0.CO;2-Z – 30. MANN WR, MURPHY PS, *Regional atlas of bone disease* (CC Thomas, Springfield, 1990) – 31. OWSLEY DW, MANN RW, MURPHY SP, *Injuries, surgical care and disease*. In: PFEIFFER S, WILLIAMSON RF (Eds) *Snake Hill: an investigation of a military cemetery from the War of 1812* (Dundurn Press, Toronto, 1991) – 32. CAVE AJE, *J Anat*, 95 (1961) 170-79. – 33. HAWKEY DE, STREET SR, *Am J Phys Anthropol*, 14 (1992), 89 – 34. LAI P, LOWELL NC, *Int J Osteoarchaeol*, 2 (1992) 221-34. DOI: org/10.1002/oa.1390020306 – 35. HAWKEY DE, MERBS CF, *Int J Osteoarchaeol*, 5 (1995) 324-38. DOI: org/10.1002/oa.1390050403 – 36. ESHED V, GOPHER A, GALILI E, HERSHKOVITZ I, *Am Journal Phys Anthropol*, 123 (2004) 303-15. DOI: 10.1002/ajpa.10312 – 37. LIEVERSE AR, BAZALIISKII VI, GORIUNOVA OI, WEBER AW, *Am J Phys Anthropol*, 138 (2009) 458-72. DOI: 10.1002/ajpa.20964 – 38. AGELARAKIS PA, SERPANOS Y, MAA, 10 (2010) 45-57. – 39. ORTNER D, PUTSCHAR W, *Identification of pathological conditions in human skeletal remains* (Smithsonian Institution Press, Washington DC, 1981) – 40. STIRLAND AJ, WALDRON T, *J Archaeol Sci*, 24 (1997) 329-35. DOI: org/10.1006/jasc.1996.0117 – 41. ŠLAUS M, *Am J Phys Anthropol*, 111 (2000) 193-209. DOI: org/10.1002/(SICI)1096-8644(200002)111:2<193::AID-AJPA6>3.0.CO;2-0 – 42. ÜSTÜNDAĞ H, *Int J Osteoarchaeol*, 19 (2008) 695-710. DOI: org/10.1002/oa.993 – 43. JIMÉNEZ-BROBEIL SA, AL OUMANOUI I, DU SOUICH PH, *Int J Osteoarchaeol*, 20 (2010) 36-46. DOI: org/10.1002/oa.1003 – 44. HUBBARD DD, GUNN DR, *Clin Orthop*, 88 (1972) 86-8. DOI: org/10.1097/00003086-197210000-00016 – 45. GHELMAN B, FREIBERGER RH, *Am J Roentgenol*, 127 (1976) 854-55. DOI: 10.2214/ajr.127.5.854 – 46. HILTON RC, BALL J, BENN RT, *Ann Rheum Dis*, 35 (1976) 127-32. DOI: org/10.1136/ard.35.2.127 – 47. SMITH DM, *Clin Orthop*, 117 (1976) 193-96. – 48. RESNICK D, NIWAYAMA G, *Radiology*, 126 (1978) 57-65. DOI: 10.1148/126.1.57 – 49. HANSSON TH, ROOS B, *Spine*, 8 (1983) 266-71. DOI: org/10.1097/00007632-198304000-00006 – 50. KOMBERG M, *Spine*, 13 (1988) 934-35. – 51. MALMIVAARA A, VIDEMAN T, KUOSMA E, TROUP JDG, *Spine*, 12 (1987) 453-57. DOI: org/10.1016/0268-0033(88)90151-9 – 52. MCLAIN R, WEINSTEIN JN, *Spine*, 15 (1990) 247-50. DOI: org/10.1097/00007632-199003000-00023 – 53. YOCHUM TR, WYLIE J, GREEN RL, *J Neuromuscle Syst*, 2 (1994) 19-22. – 54. CHANDRARAJ S, BRIGGS CA, OPESKIN K, *Clin Anat*, 11 (1998) 171-76. DOI: org/10.1002/(SICI)1098-2353(1998)11:3<171::AID-CA4>3.0.CO;2-W – 55. WAGNER AL, REED MF, ARRINGTON JA, STALLWORTH D, *Am J Neuroradiol*, 21 (2000) 276-81. – 56. PFIRRMANN CW, RESNICK D, *Radiology*, 219 (2001) 368-74. DOI: 10.1148/radiology.219.2.r01ma21368 – 57. HASEGAWA K, OGOSE A, MORITA T, HIRATA Y, *Spinal Cord*, 42 (2004), 124-28. DOI: org/10.1038/sj.sc.3101506 – 58. ROGERS J, WALDRON T, DIEPPE P, WATT I, *J Archaeol Sci*, 14 (1987), 179-93. DOI: org/10.1016/0305-4403(87)90005-7 – 59. LOVELL NC, *Am J Phys Anthropol*, 93 (1994) 149-64. DOI: org/10.1002/ajpa.1330930202 – 60. WALDRON T, *Counting the dead: the epidemiology of skeletal populations* (Wiley & Sons, Chichester, 1994) – 61. KNÜSEL CJ, GÖGEL S, LUCY D, *Am J Phys Anthropol*, 103 (1997) 481-95. DOI: org/10.1002/(sici)1096-8644(199708)103:4<481::aid-ajpa6>3.0.co;2-q – 62. VAN DER MERWE AE, IŞCAN MY, L'ABBÈ EN, *Int J Osteoarchaeol*, 16 (2006), 459-64. DOI: org/10.1002/oa.841 – 63. WEISS E, JURMAIN R, *Int J Osteoarchaeol*, 17 (2007) 437-50. DOI: org/10.1002/oa.889

M. Šlaus

Anthropological Centre, Croatian Academy of Sciences and Arts, Ante Kovačića 5, 10000 Zagreb, Croatia

e-mail: mslaus@hazu.hr

REKONSTRUKCIJA ŽIVOTA RIMSKOG VOJNIKA OTKOPANOG U RESNIKU NA TEMELJU ANTROPOLOŠKE ANALIZE NJEGOVA KOSTURA

SAŽETAK

Neprekidan teški fizički rad i repetitivno izvođenje specifičnih aktivnosti tijekom svakodnevnog rada utječe na kosti i mijenja njihovu morfologiju, naročito ako su te aktivnosti dugotrajne i ako su započele u ranoj dobi. Analiza i tumačenje tih promjena daje jedinstvenu prigodu da rekonstruiramo kvalitetu života, količinu i vrstu rada, kao i rizike koji se vezuju uz određena zanimanja ili aktivnosti. Ovdje su predstavljeni rezultati antropološke analize kostura otkopanog na antičkoj nekropoli u Resniku. Otkriveni arheološki nalazi iz groba utorena glava koplja) sugeriraju da je otkopan muškarac na neki način bio povezan s rimskom vojskom, vjerojatno kao legionar ili beneficijarij. Osteološki podaci dobiveni analizom kostura uspoređeni su s teoretskim i idealiziranim prikazom savršenog rimskog vojnika, prema izvještaju Vegecija Renata u radu "Sažetak vojne vještine" (*Epitome rei militaris*), kako bi se rekonstruirao život stvarnog rimskog vojnika koji je krajem 2. st. služio u rimskoj provinciji Dalmaciji. Analiza kostura dala je informacije o općim uvjetima života u 2. st. n.e., kao i o specifičnim rizicima povezanima s vojnim životom. Opći uvjeti života uključuju parazitske zaraze i posljedičnu anemiju koja je rezultirala brojnim virusnim i bakterijskim infekcijama, dok specifični rizici vezani uz vojni život uključuju brojne osteološke pokazatelje fizičkog stresa i teškog fizičkog rada. Prisutnost dvije remodelirane antemortalne frakture pokazuju kako je rizik od traumatskih ozljeda kod rimskih vojnika bio visok.