

Erythema of the penis after use of a latex condom - latex allergy or something else?

Ljubojević Hadžavdić, Suzana; Gojčeta Burnić, Sanda; Hadžavdić, Ayla; Marinović Kulišić, Sandra; Jurakić Tončić, Ružica

Source / Izvornik: **Contact Dermatitis, 2018, 78, 168 - 169**

Journal article, Published version

Rad u časopisu, Objavljena verzija rada (izdavačev PDF)

<https://doi.org/10.1111/cod.12879>

Permanent link / Trajna poveznica: <https://urn.nsk.hr/urn:nbn:hr:105:970168>

Rights / Prava: [In copyright](#) / [Zaštićeno autorskim pravom.](#)

Download date / Datum preuzimanja: **2024-08-08**



Repository / Repozitorij:

[Dr Med - University of Zagreb School of Medicine Digital Repository](#)



Erythema of the penis after use of a latex condom – latex allergy or something else?

Suzana Ljubojević Hadžavdić¹, Sanda Gojčeta Burnić², Ayla Hadžavdić³, Sandra Marinović Kulišić¹ and Ružica Jurakić Tončić¹

¹Department of Dermatology and Venereology, University Hospital Centre Zagreb, School of Medicine, University of Zagreb, 10000 Zagreb, Croatia,

²Department of Dermatology and Venereology, General Hospital Varaždin, 42000 Varaždin, Croatia and ³University of Zagreb, School of Medicine, 10000 Zagreb, Croatia

doi:10.1111/cod.12879

Key words: benzocaine; case report; contact allergy; latex condom.

Irritant and allergic contact dermatitis is commonly seen in patients complaining of itching, burning and irritation in the genital area. Dermatoses seen in the genital area are often confused with infection (especially with fungal infection), and the correct diagnosis and treatment may be delayed for months (1).

Case Report

A 26-year-old non-atopic man presented with recurrent erythematous dermatitis of the glans and shaft

of the penis (Fig. 1). He had recently entered a new relationship and had started using condoms for sexual intercourse. His symptoms appeared a few hours after every episode of sexual intercourse. After using condoms in the past, he had sometimes noted mild, self-limiting irritation on the shaft of his penis. Mycological and bacterial swabs from the penis skin, urethral swabs for sexually transmitted infections and serology for syphilis, human immunodeficiency virus and hepatitis gave negative results. We performed patch tests with the baseline series (Chemotechnique Diagnostics, Vellinge, Sweden; Imunološki zavod, Zagreb, Croatia) and with latex (Imunološki zavod). Patch testing showed positive reactions to benzocaine (5% pet.) on day (D) 2 (+) and on D3 and D7 (++) (Fig. 2). According to this patch test result, we re-evaluated the patient's history. He

Correspondence to: Professor Suzana Ljubojević Hadžavdić, Department of Dermatology and Venereology, University Hospital Centre Zagreb, School of Medicine, University of Zagreb, Salata 4, Zagreb 10000, Croatia. Tel: +385 912501593. Email: suzana.ljubojevic@gmail.com

Conflicts of interests: None declared.

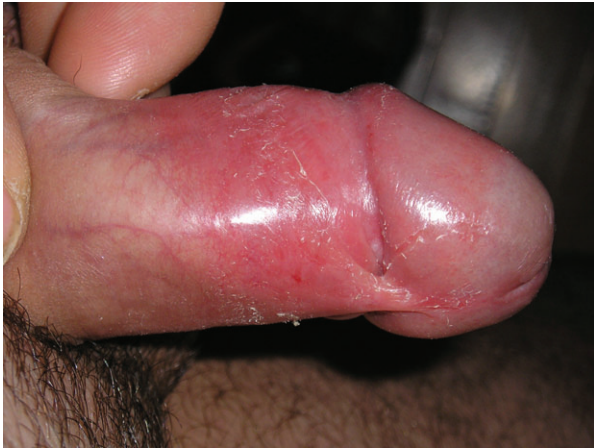

Fig. 1. Erythema, oedema and desquamation on the glans and shaft of the penis after benzocaine condom use.

Discussion

Genital hypersensitivity reactions may be subdivided into those related to sexual activity (kissing, foreplay, and coitus) and those that may occur in the absence of sexual contact. Active agents in topical medications and popular remedies, preservatives and ointment bases are the most frequent causes of allergic reactions (2). Both type I and type IV hypersensitivity reactions to latex condoms have been reported (3). Most commonly seen are contact dermatitis, contact urticaria, and, more rarely, anaphylaxis. Benzocaine is a local anaesthetic that is commonly used as a topical pain reliever. It can be found in cough drops and haemorrhoid ointments, but it is also the active ingredient in many over-the-counter anaesthetic ointments such as products for oral ulcers, sunburn relief lotions, and ear drops for relieving pain and removing earwax – and, moreover, in condoms.

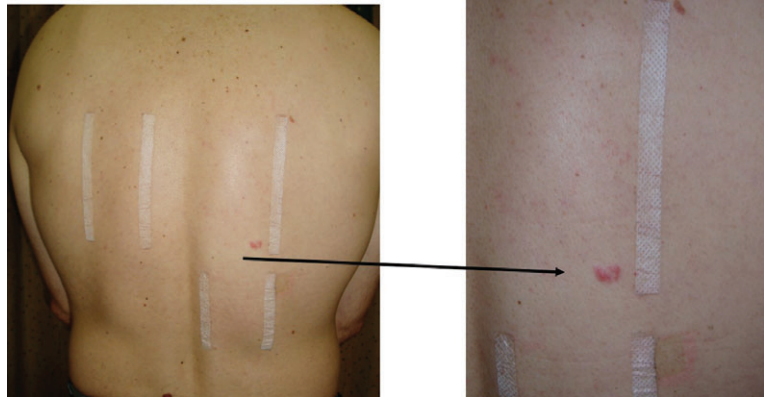


Fig. 2. Positive patch test reaction (+) to benzocaine (5% pet.).

stated that he had started using new brands of condom, which contained 5% benzocaine (Durex Extended Pleasure® and Durex Performax®) and 4.5% benzocaine (Lifestyles Everlast Intense Condom®), respectively, to increase the duration of his sexual activity and to improve his sexual performance. He also revealed that, a year previously, he had had haemorrhoids and had occasionally used a haemorrhoid ointment containing benzocaine.

Benzocaine contact allergy resulting from the use of latex condoms is quite rarely reported (4–6), possibly because patients may not report symptoms in the genital area, owing to feelings of shame. Genital allergy is uncommon, but should be considered in all patients with genital pruritus, redness, soreness, or burning sensations. It is important to take a thorough patient history, and it is necessary to perform patch tests with the baseline series and the patient's own products.

References

- 1 Sonnex C. Genital allergy. *Sex Transm Infect* 2004; **80**: 4–7.
- 2 Ljubojević S, Lipozenčić J, Celić D, Turčić P. Genital contact allergy. *Acta Dermatovenerol Croat* 2009; **17**: 285–288.
- 3 Caminati M, Giorgis V, Palterer B et al. Allergy and sexual behaviours: an update. *Clin Rev Allergy Immunol* 2017. <https://doi.org/10.1007/s12016-017-8618-3>.
- 4 Muratore L, Calogiuri G, Foti C et al. Contact allergy to benzocaine in a condom. *Contact Dermatitis* 2008; **59**: 173–174.
- 5 Foti C, Bonamonte D, Antelmi A et al. Allergic contact dermatitis to condoms: description of a clinical case and analytical review of current literature. *Immunopharmacol Immunotoxicol* 2004; **26**: 481–485.
- 6 Placucci F, Lorenzi S, La Placa M, Vincenzi C. Sensitization to benzocaine on a condom. *Contact Dermatitis* 1996; **34**: 293.