

Vagal nerve stimulation is beneficial in postural orthostatic tachycardia syndrome and epilepsy

Petelin Gadže, Željka; Bujan Kovač, Andreja; Adamec, Ivan; Milekić, Nina; Šulentić, Vlatko

Source / Izvornik: **Seizure, 2018, 57, 11 - 13**

Journal article, Accepted version

Rad u časopisu, Završna verzija rukopisa prihvaćena za objavljivanje (postprint)

<https://doi.org/10.1016/j.seizure.2018.03.001>

Permanent link / Trajna poveznica: <https://urn.nsk.hr/urn:nbn:hr:105:049514>

Rights / Prava: [In copyright](#) / [Zaštićeno autorskim pravom.](#)

Download date / Datum preuzimanja: **2024-07-18**



Repository / Repozitorij:

[Dr Med - University of Zagreb School of Medicine
Digital Repository](#)





Središnja medicinska knjižnica

**Petelin Gadže Ž., Bujan Kovač A., Adamec I., Milekić N., Šulentić V.
(2018) *Vagal nerve stimulation is beneficial in postural orthostatic
tachycardia syndrome and epilepsy. Seizure, 57. pp. 11-13 ISSN 1059-
1311***

<http://www.elsevier.com/locate/issn/10591311>

<http://www.sciencedirect.com/science/journal/10591311>

<http://dx.doi.org/10.1016/j.seizure.2018.03.001>

<http://medlib.mef.hr/3502>

University of Zagreb School of Medicine Repository

<http://medlib.mef.hr/>

Vagus nerve stimulation is beneficial in postural orthostatic tachycardia syndrome and epilepsy

Zeljka Petelin Gadze¹, Andreja Bujan Kovac¹, Ivan Adamec², Nina Milekic³, Vlatko Sulentic¹

¹Department of Neurology, University Hospital Centre Zagreb, School of Medicine, University of Zagreb, Referral Centre of the Ministry of Health of the Republic of Croatia for Epilepsy, Zagreb, Croatia

² Department of Neurology, University Hospital Center Zagreb, School of Medicine, University of Zagreb, Referral Centre for Autonomic Nervous System Disorders, Zagreb, Croatia

³ Department of Neurology, Šibenik-Knin County General Hospital, Šibenik, Croatia

Corresponding author : abujankovac@gmail.com (Andreja Bujan Kovac), telephone number +385915566030

Keywords: vagus nerve stimulation; postural orthostatic tachycardia syndrome; epilepsy

Acknowledgements: Authors are very grateful to Prof. Sanja Hajnšek, M.D., Ph.D., Assist. Prof. Mario Habek, M.D., Ph.D., Prof. Milan Radoš, M.D., Ph.D., Assist. Prof. Goran Mrak, M.D., Ph.D., Prim. Sibila Nankovic, M.D. and to Ivana Cajic, M.D. for their help in treating patient presented in this paper.

Declarations of interest: none.

POTS (Postural Orthostatic Tachycardia Syndrome) is a condition caused by cerebral hypoperfusion which results in general weakness, dizziness, lightheadedness, fatigue upon standing and visual blurring or fogging of the visual fields. Syncope occurs in 40% of patients. Other predominantly orthostatic symptoms include palpitations, tremulousness and anxiety. Gastrointestinal symptoms, as nausea, cramps, bloating, constipation and diarrhea and acrocyanosis as well as edema due to low venous pooling can also appear in some cases. This syndrome was first described in 1871, by physician Jacob Mendes Da Costa. Hallmark of this disorder is an exaggerated heart rate increase in response to postural change [1].

29-year-old female patient was admitted to our hospital in December 2011 for additional work-up and due to pharmacoresistant epilepsy from the age of 9. Clinically, according to the ILAE (International League Against Epilepsy) 2017 operational classification of seizure types [2] she had focal motor onset seizures to bilateral tonic-clonic seizures (central lobe seizures, prior referred as Jacksonian seizures of the left side of the body). Several years later, seizures of different origin also appeared, with phenotype of focal impaired awareness seizures of motor onset with gestural automatisms and motor dysphasia followed by sense of fear and panic attacks and with short-term postictal confusion, corresponding to left temporal lobe seizures. Brain MRI (Magnetic resonance imaging) showed bilateral frontoparietal polymicrogyria and right subependymal nodular grey matter heterotopia (Figure 1.). Couple of years ago, she also noticed palpitations and dizziness in standing upright that were relieved by sitting or lying flat. Due to complex malformation of cortical development patient was not considered as a candidate for resective neurosurgery and we decided for minimal invasive neurosurgical treatment, implantation of vagal nerve stimulator (VNS) [3]. During the preoperative work-up head-up tilt test (HUTT) was performed that revealed POTS refractory to lifestyle modification measures. Cardiovascular ultrasound and holter-ECG were normal.

One week after implantation, VNS was initiated at 0.25 mA (duty cycle set to a 30-Hz signal frequency, a 500-ms pulse width, 30 seconds of ON-time, and 3 min of OFF-time). HUTT done at one month and three months after implantation was normal. VNS was gradually increased to 1 mA which led to significant reduction in seizure rate and disappearance of orthostatic intolerance symptoms (Figure 2.).

POTS is defined by a heart rate increment of 30 beats/min or more within 10 minutes of standing on HUTT, in the absence of orthostatic hypotension. As a form of orthostatic intolerance, it particularly occurs in younger adults and children in response to postural stressors, with a female to male ratio of 4-5:1 [4]. The reason for this is not known, however observed gender differences in muscle sympathetic nerve discharge characteristics and decreased stroke volume in healthy patients may explain why woman are more likely to develop POTS. The orthostatic nature of the symptoms is the primary clue to diagnosis. Patients with POTS have decrease in sympathetic activity that leads to systemic hypotension upon standing.

VNS is a safe and effective adjunctive treatment for drug-resistant epilepsy when surgery is inadvisable [3]. Limited data suggest that long-term VNS therapy might affect cardiac autonomic function. Therapeutic effects of POTS are further being explored by some clinical studies. Optimal therapy of POTS remains uncertain. No intervention has been systematically studied. To our knowledge, this is the first reported case of the positive effect of VNS in a patient with POTS and epilepsy. Further studies with a larger number of patients are needed.

Ethical approval:

This article does not contain research including human participants or animals performed by any of the authors.

Informed consent:

Informed consent was obtained from the patient included in the study.

Figure 1. A.-D. Brain MRI showing bilateral frontoparietal polymicrogyria and right subependymal nodular grey matter heterotopia.

Figure 2. A. Preoperative HUT showing POTS with vasodepressor syncope. **B.** Postoperative HUT showing normal response.

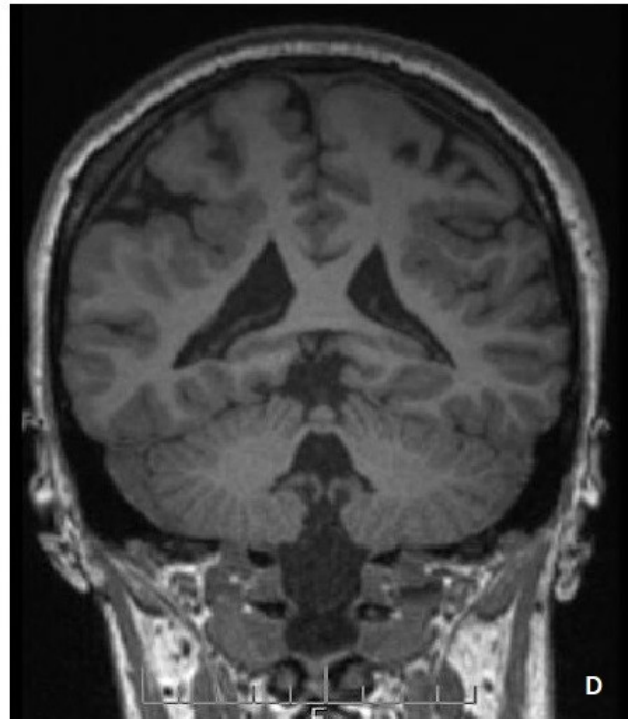
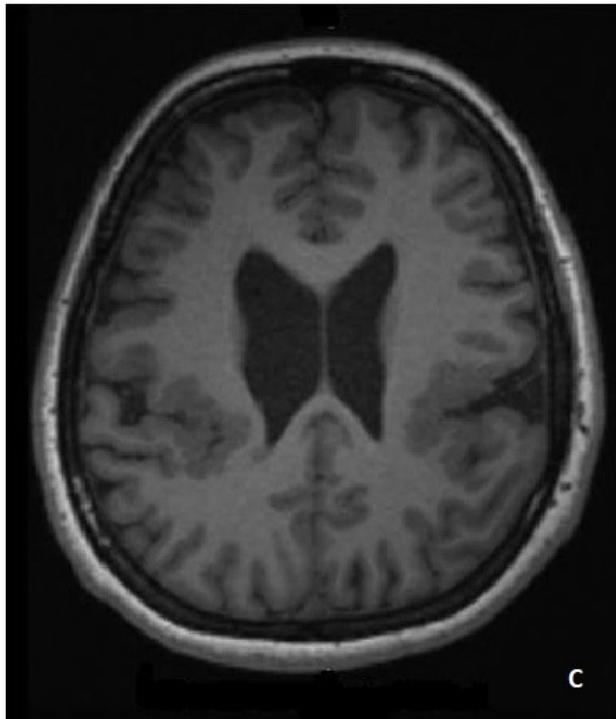
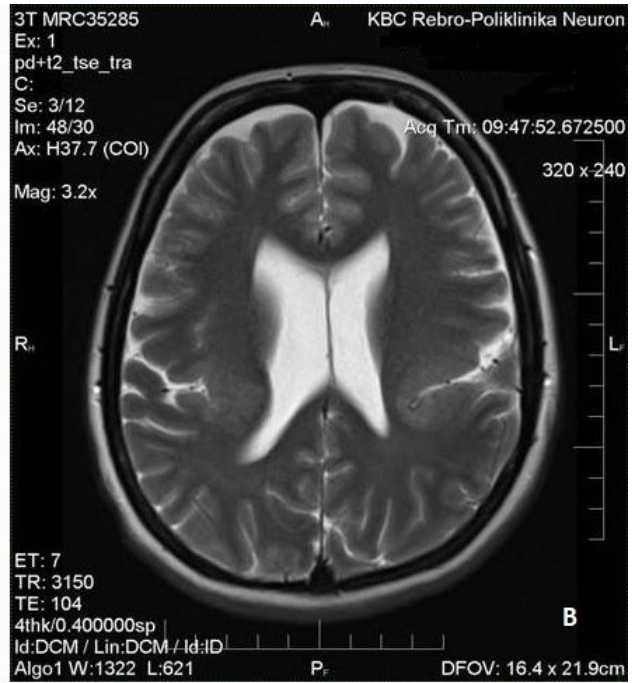
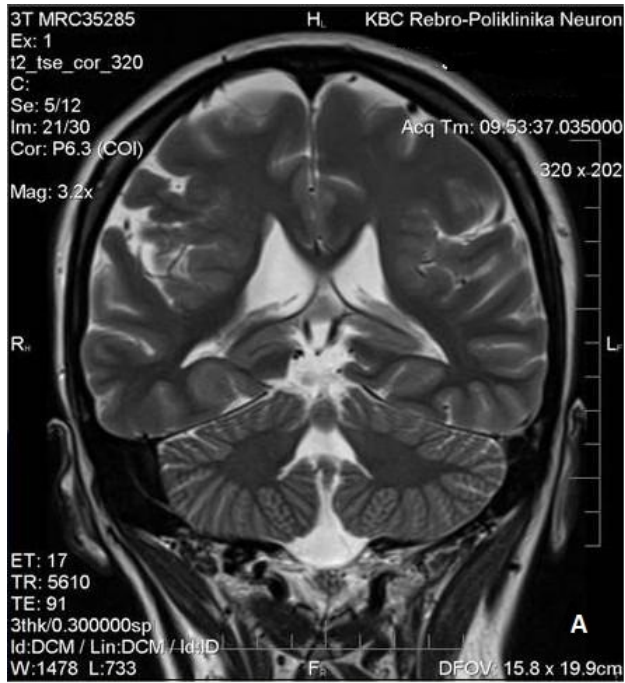
References

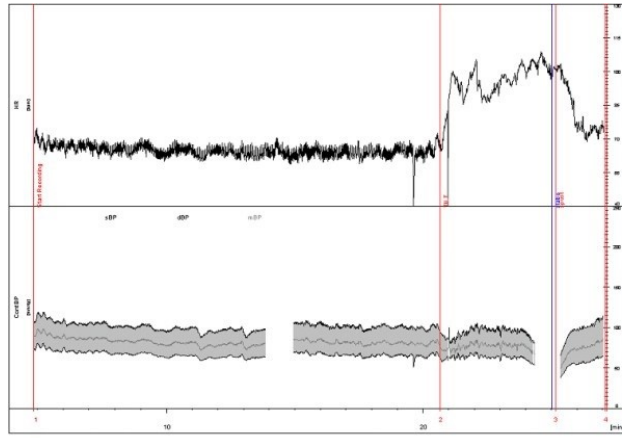
[1] Mathias CJ, Low DA, Iodice V, Owens AP, Kirbis M, Grahame R. Postural tachycardia syndrome-current experience and concepts. *Nat Rev Neurol.* 2011;6;8(1):22-34. doi: 10.1038/nrneurol.2011.187.

[2] Fisher RS, Cross JH, French JA, Higurashi N, Hirsch E, Jansen FE, Lagae L, Moshé SL, Peltola J, Roulet Perez E, Scheffer IE, Zuberi SM. Operational classification of seizure types by the International League Against Epilepsy: Position Paper of the ILAE Commission for Classification and Terminology. *Epilepsia.* 2017;58(4):522-530. doi: 10.1111/epi.13670.

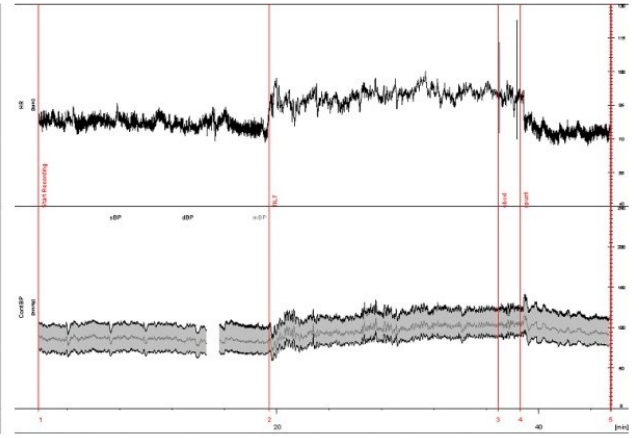
[3] Arcand J, Waterhouse K., Hernandez-Ronquillo L, Vitali A., Tellez-Zenteno JF. Efficacy of Vagal Nerve Stimulation for Drug-Resistant Epilepsy: Is it the Stimulation or Medication? *Can J Neurol Sci.* 2017;44(5):532-537. doi: 10.1017/cjn.2017.46.

[4] Thieben MJ, Sandroni P, Sletten DM, Benrud-Larson LM, Fealey RD, Vernino S, Lennon VA, Shen WK, Low PA. Postural orthostatic tachycardia syndrome: the Mayo clinic experience. *Mayo Clin Proc.* 2007;82(3):308-13.





A



B