

Allergic contact dermatitis to cow's hair

Ljubojević, Suzana; Paštar, Zrinjka; Lipozenčić, Jasna; Milavec-Puretić, Višnja

Source / Izvornik: **Contact Dermatitis, 2007, 56, 50 - 52**

Journal article, Accepted version

Rad u časopisu, Završna verzija rukopisa prihvaćena za objavljivanje (postprint)

<https://doi.org/10.1111/j.1600-0536.2007.00934.x>

Permanent link / Trajna poveznica: <https://um.nsk.hr/um:nbn:hr:105:512835>

Rights / Prava: [In copyright](#)/[Zaštićeno autorskim pravom.](#)

Download date / Datum preuzimanja: **2024-07-17**



Repository / Repozitorij:

[Dr Med - University of Zagreb School of Medicine
Digital Repository](#)





Središnja medicinska knjižnica

Ljubojević, S., Paštar, Z., Lipozencčić, J., Milavec-Puretić, V. (2007) *Allergic contact dermatitis to cow's hair*. *Contact Dermatitis*, 56 (1). pp. 50-52.

The definitive version is available at www.blackwell-synergy.com

<http://www.blackwell-synergy.com/doi/abs/10.1111/j.1600-0536.2007.00934.x>

<http://dx.doi.org/10.1111/j.1600-0536.2007.00934.x>

<http://medlib.mef.hr/351>

University of Zagreb Medical School Repository

<http://medlib.mef.hr/>

FIRST AUTHOR:

Suzana Ljubojevic, MD, PhD

OTHER AUTHORS:

Zrinjka Pastar, MD

Jasna Lipozencic, MD, PhD

Visnja Milavec-Puretic, MD, PhD

CORRESPONDING ADDRESS:

Suzana Ljubojevic, MD, PhD

University Department of Dermatology and Venerology,

Zagreb University Hospital Center,

Salata 4, 10000 Zagreb

CROATIA

TEL/FAX: +385-1-4920-014

e-mail: suzana.ljubojevic@zg.htnet.hr

ALLERGIC CONTACT DERMATITIS TO COW HAIR

S. Ljubojevic, Z. Pastar¹, J. Lipozencic, V. Milavec-Puretic

University Department of Dermatology and Venerology, Zagreb University Hospital
Center, Zagreb, Croatia

¹MORH, Health department, Zagreb, Croatia

ABSTRACT

A 32-year-old farmer woman with delay-ed type of allergy to cow's hair is described. She had the 5-year history of erythematous, desquamative lesions on the dorsal side of the hands and forearms. Shortly after entering cowshed, she showed relapse of skin symptoms and total regression when she was away from the farm. The patch test to European standard series, patient's own cow hair, hay and stable hay was performed. Additionally prick test to inhalant allergens, patient's own cow hair, hay, stable hay and cow's milk, total immunoglobulin class E together and specific IgE to cow dander and milk were performed. Patch test gave positive reaction to cow's hair, cobalt chloride, nickel sulfate and thimerosal. All other tests were negative.

Key words: cow hair, allergic contact dermatitis, patch test

INTRODUCTION

Cow hair and dander can cause contact dermatitis, which can be diagnosed by patch testing. Delayed type hypersensitivity from animal materials is rarely reported, except in Finland where cows' dander is the most common occupational allergen (1, 2).

CASE REPORT

A 32-year-old farmer woman had a 5-year history of erythematous, desquamative lesions on the dorsal side of the hands and forearms. The covered skin was uninvolved. Seven years before, she got married and moved to her husband's farm, where he had cowshed. The skin lesion got worst every time when she had contact with cow hair, stable hay and straw. Shortly after milking, trimming or brushing the cow, many vesicles, bules and afterwards deep and painful rhagades appeared. Anamnestic data indicated that wet work potentiated and worsted skin symptoms. The lesions cleared completely when the patient was away from the cowshed for few days. She denied exacerbation of any skin symptoms with a contact to other allergens and irritants beside allergens found in cowshed. The patient had no side effects from drinking cow's milk. Her past medical history and family history were negative for atopic diseases.

We performed patch test to standard European series, patient's own cow hair, hay and stable hay. The cow hair brought by the patient was brush from the cows, was occluded and tested. The first reading was after 20 minutes, than after 48 and 72 hours. Additionally we performed prick test to inhalant allergens, hay, stable hay, cow's hair and cow's milk, total immunoglobulin class E (IgE) together with specific IgE (Radioallergosorbent test-RAST) to cow hair and milk.

Patch test showed positive reaction to cow's hair, cobalt chloride, nickel sulfate and thimerosal (Fig. 1). Patch test to cow's hair didn't show positive reaction after occluded for 20 minutes, but it was positive after 48 and 72 hours (Fig. 2). Prick tests gave negative results. Total and specific IgE were within normal limits.

She was treated with local corticosteroid ointments for 10 days and then with neutral protective hand creams. She was told to avoid wet work for some time and to avoid the contact with cows. On the follow up visit she was without skin symptoms, and her husband is now talking care of cows.

DISCUSSION

In European countries occupational allergy to cows is infrequent, but it is well-known in Finland (1, 2). This is because of the cold climate in Finland that cows are kept up to nine months yearly indoors and Finnish farmers shave their cows in order to make them look cleaner (3). This all leads to an excessive allergen exposure. True delayed-type dermatitis from cow hair or dander is rarely reported (4). Immediate and delayed contact allergy to cow dander was first described by Epstein in 1948 (5). He described 28 cases of typical hand eczema and cow sensitivity in milkers (5). Fifteen out of 28 patients had positive immediate and 13 delayed skin test reactions to cow dander. In the study performed by Susitaival *et al*, equal number (one third) of the patient had immediate, late and combined immediate and late allergy to cow dander (1).

In our case patient had positive patch test to four allergens. Luckily, she hadn't have any problems with other allergies beside constantly worsening of the skin symptoms, while she was working in cowshed. Wet work and irritant factors elicited a skin barrier

dysfunction that allowed protein molecules to penetrate the skin and induces allergic contact dermatitis (6). We didn't perform scratch-chamber test because, our patient didn't have any symptoms of immediate reaction. Fresh cow dander applied as a scratch-chamber test seems to be the most effective way of proving an IgE-mediated contact dermatitis (7).

CONCLUSION

It is important to consider cow hair as a possible cause of allergic contact dermatitis and although patch testing to cow hair and other biological material is not standardized, it has to be tested in order to prove delayed contact dermatitis.

REFERENCES:

1. Susitaival P, Husman L, Hollmen A, Horsmanheimo M, Husman K, Hannuksela M. Hand eczema in Finnish farmers. A questionnaire-based clinical study. *Contact Dermatitis* 1995;32:150-155.
2. Kanerva L, Susitaival P. Cow dander: the most common cause of occupational contact urticaria in Finland. *Contact Dermatitis* 1996;35:309-310.
3. Spiewak R. Occupational rhinoconjunctivitis, protein contact dermatitis, asthma and contact urticaria to cow allergens in a farmer. *Allergologie* 2004;27:402-407.
4. Timmer C, Coenraads PJ. Allergic contact dermatitis from cow hair and dander. *Contact Dermatitis* 1996; 34:292-293.
5. Epstein S. Milker's eczema. *J Allergy* 1948;19:333-341.

6. Kanerva L, Estlander T. Immediate and delayed skin allergy from cow dander. *Am J Contact Dermat* 1997;8:167-169.
7. Mahler V, Diepgen TL, Heese A, Peters KP. Protein contact dermatitis due to cow dander. *Contact Dermatitis* 1998;38:47-48.

Figure 1. Positive patch test reaction to cow's hair, cobalt chloride, nickel sulfate and thimerosal

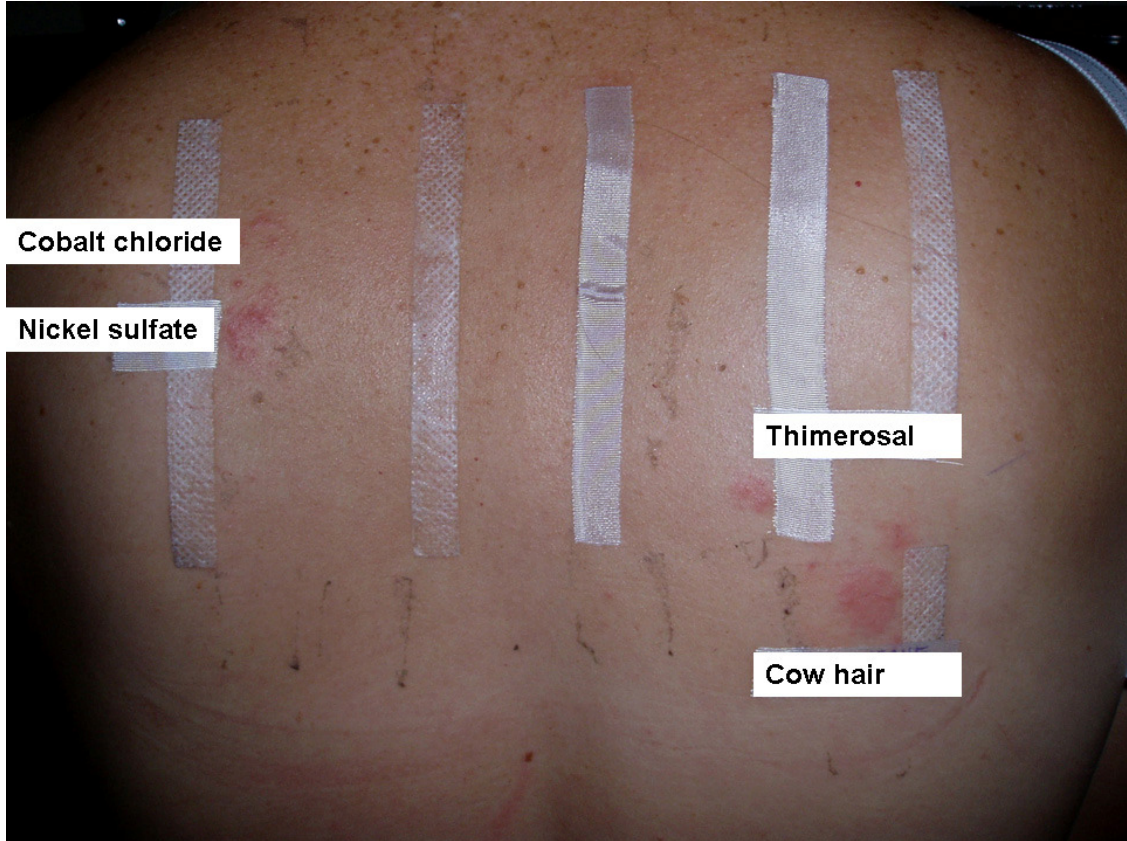


Figure 2. Positive patch test reaction to patients own cow hair

