

Transbronchial fine needle aspiration cytology in the diagnosis of mediastinal/hilar sarcoidosis

Smojver-Ježek, Silvana; Peroš-Golubičić, Tatjana; Tekavec-Trkanjec, Jasna; Mažuranić, Ivica; Alilović, Marija

Source / Izvornik: **Cytopathology, 2007, 18, 3 - 7**

Journal article, Accepted version

Rad u časopisu, Završna verzija rukopisa prihvaćena za objavljivanje (postprint)

<https://doi.org/10.1111/j.1365-2303.2006.00336.x>

Permanent link / Trajna poveznica: <https://urn.nsk.hr/urn:nbn:hr:105:241089>

Rights / Prava: [In copyright](#) / [Zaštićeno autorskim pravom.](#)

Download date / Datum preuzimanja: **2024-07-13**



Repository / Repozitorij:

[Dr Med - University of Zagreb School of Medicine
Digital Repository](#)





Središnja medicinska knjižnica

Smojver-Ježek, S., Peroš-Golubičić, T., Tekavec-Trkanjec, J., Mažuranić, I., Alilović, M. (2007) *Transbronchial fine needle aspiration cytology in the diagnosis of mediastinal/hilar sarcoidosis*. *Cytopathology*, 18 (1). pp. 3-7.

The definitive version is available at www.blackwell-synergy.com.

<http://www.blackwell-synergy.com/doi/abs/10.1111/j.1365-2303.2006.00336.x>

<http://dx.doi.org/10.1111/j.1365-2303.2006.00336.x>

<http://medlib.mef.hr/353>

University of Zagreb Medical School Repository

<http://medlib.mef.hr/>

**TRANSBRONCHIAL FINE NEEDLE ASPIRATION CYTOLOGY IN THE DIAGNOSIS OF
MEDIASTINAL/HILAR SARCOIDOSIS**

Silvana Smojver-Ježek, M.D.M.Sc., clinical cytologist¹

Tatjana Peroš-Golubičić, M.D. Ph.D., Associate Professor, pneumonologist²

Jasna Tekavec-Trkanjec, M.D. Ph.D., pneumonologist²

Ivica Mažuranić, M.D.Ph.D., radiologist³

Marija Alilović, M.D., pneumonologist²

From University Hospital for Lung Diseases "Jordanovac",

Departments of Cytology¹, Pneumology² and Radiology³

10 000 Zagreb, Jordanovac 104, CROATIA

Silvana Smojver-Ježek, M.D. M.Sc., clinical cytologist

University Hospital for Lung Diseases "Jordanovac",

10 000 Zagreb, Jordanovac 104, CROATIA

Tel. + 385 1 23 85 131, Fax. + 385 1 23 48 345

E-mail: ssmojver@pbf.hr

Running head: TBFNA CYTOLOGY IN SARCOIDOSIS

SUMMARY

Objective: The diagnostic value of the transbronchial/transtracheal fine needle aspiration (TBFNA) cytology in the patients with mediastinal and/or hilar lymphadenopathy has been investigated.

Method: Out of 116 patients with mediastinal/hilar lymphadenopathy, the diagnosis of sarcoidosis was established in 88 (75,9%). One hundred and seventy-one TBFNAs with cytological 26-gauge needle were performed, from different lymph node stations. Adequate lymph node samples were obtained in 157/171 (91,8%) TBFNA and 14/171(8,2%) TBFNA samples were inadequate.

Results: Cytological findings consistent with sarcoidosis were found in 79/88 (89,77%) patients and 133/157 (84,71%) samples. Sensitivity of TBFNA cytology in sarcoidosis presenting as mediastinal/hilar lymphadenopathy was 78,7%, specificity 92,3%.

Conclusions: Overall diagnostic accuracy of TBFNA cytology in the diagnosis of sarcoidosis was 86,2%, and cytological findings consistent with sarcoidosis were the only morphological diagnosis of sarcoidosis in 63,6% of patients.

Key words: transbronchial, fine needle aspiration cytology, mediastinal/hilar lymphadenopathy, sarcoidosis, diagnostic accuracy

INTRODUCTION

Sarcoidosis is a systemic granulomatous disease that primarily affects the lung and lymphatic systems of the body, most often mediastinal and hilar lymph nodes (1). Fine needle aspiration (FNA) is a simple, safe and cost-effective method; it can be performed in any body setting, with results usually available within a day. Transbronchial fine needle aspiration (TBFNA) is minimally invasive bronchoscopic procedure in the diagnosis and staging of mediastinal and/or hilar masses (2,3). The diagnosis of sarcoidosis is based on clinicoradiological information supported by morphological findings and transbronchial needle aspiration can demonstrate the elements of granulomatous inflammation in histological or/and cytological specimens.

In the 1950s Brouet and Euler introduced transbronchial needle aspiration through a rigid bronchoscope (4). Transbronchial needle aspiration during fiberoptic bronchoscopy was adapted by Wang et al. in 1978, avoiding more invasive surgical procedures, such as mediastinoscopy (2,5,6). The method was used for sampling of intraluminal lesions, but in the last two decades its primary indication has been to obtain material from mediastinal and/or hilar nodes in staging of lung carcinomas and differential diagnosis of reactive lymphadenopathy (2,3,4,7,8,9). Most authors report using a 19-gauge histology needle, which can provide both histologic and cytologic material (4,10). Specimens obtained with small needles of 20,22,26 gauges are suitable for cytological examination only (9,11,12). The presence of lymphocytes with or without other types of cells is an essential criterion of specimen adequacy in TBFNA of intrathoracic lymphadenopathy (12). The diagnostic value of transbronchial fine needle aspiration cytology in patients with sarcoidosis presenting as mediastinal/hilar lymphadenopathy has been investigated.

MATERIALS AND METHODS

The patients with mediastinal and/or hilar lymphadenopathy by radiographic criteria who had a bronchoscopic TBFNA procedure performed between January 1999 and December 2003 in a single institution (University Hospital for Lung Diseases Jordanovac, Zagreb) were included in the study.

All patients underwent bronchoscopy and TBFNA with 26-gauge needle for cytological analysis was performed. Punctures were repeated until macroscopically adequate material was obtained judged by bronchoscopist and cytotechnologist. A cytopathologist was not present during the procedures and rapid on site evaluation was not performed. Direct smear technique was used for specimens preparation, specimens were air-dried and stained with May-Grünwald Giemsa. The needle was washed out and the solution sent for microscopical examination for the presence of acid-fast bacilli (AFB) and cultured on Löwenstein-Jensen medium.

Specimens were inadequate if bronchial epithelial cells and macrophages, and/or sparse lymphocytes, comprised less than 30% of cell elements (12). The presence of lymphocytes with or without other types of cells is the essential criterion of specimen adequacy in TBFNA of intrathoracic lymphadenopathy (7,12,13). Specimens were considered adequate if there were more than 30% of lymphocytes as representative of lymph node sampling. Specimens were diagnostic for sarcoidosis if bronchial epithelial cells, erythrocytes, lymphoid cells with normal morphology and elements of granuloma were found. A cytological diagnosis of granuloma in TBFNA was established according to following criteria: the presence of epithelioid cells, scattered or in clusters, variable numbers of small lymphocytes, multinucleated giant cells, and no or minimal necrosis. Following the cytological examination specimens with minimal necrosis were restained with auramine and examined for the presence of AFB by fluorescence microscope.

A final diagnosis of sarcoidosis was based upon: positive TBFNA cytology, negative AFB finding by fluorescence microscopy and negative growth of *Mycobacterium tuberculosis* in Löwenstein culture of TBFNA material, histopathological recognition of sarcoid granulomas in other bronchoscopic materials and clinical and radiologic findings consistent with sarcoidosis.

Statistical methods:

Sensitivity of TBFNA cytology was calculated as true positive (TP)/true positive + false negative (FN); specificity as true negative (TN)/true negative + false positive (FP); diagnostic accuracy as true positive + true negative/ true positive + true negative + false positive + false negative $TP+TN/TP + TN + FP + FN$; negative predictive value was calculated as true negative / true negative + false negative $TN/TN + FN$ and positive predictive value as true positive/true positive + false positive $TP/TP + FP$ (3,8). All TBFNA with cytological findings consistent with sarcoidosis, the diagnosis of which was confirmed by other procedures, were regarded as true positive. True negatives were adequate TBFNA specimens without cytological findings consistent with sarcoidosis in patients with a disease other than sarcoidosis. False negative were TBFNA specimens without specific cytological findings confirmed as sarcoidosis and false positive were TBFNA specimens with cytological findings consistent with sarcoidosis in diseases other than sarcoidosis.

RESULTS

Among 116 patients with mediastinal and/or hilar lymphadenopathy, there were 70 women and 46 men, mean age 46, SD +/- 15 years. A diagnosis of sarcoidosis was established in 88 (75,9%) of patients, 57 woman and 31 men, mean age 43 years, SD +/- 13 years.

Adequate lymph node samples were obtained in 157/171 (91,8%) TBFNA and 14/171(8,2%) TBFNA samples were inadequate.

The cytological findings are shown in Table 1. Findings consistent with sarcoidosis were present in 133/157 (84,7%) of TBFNA samples and 79/88 (89,8%) of patients with sarcoidosis proven otherwise.

Multinucleated giant cells of Langhans type with epithelioid cells and variable numbers of lymphocytes with or without minimal necrosis, as the elements of granuloma, were found in 63/88 (71,6%) of sarcoidosis patients and 104/157 (66,2%) of TBFNA samples (Figures 1 and 2). Small groups or scattered epithelioid cells with lymphocytes, without multinucleated giant cells or necrosis were considered as findings consistent with sarcoidosis in 16/88 (18,2%) patients and 29/157 (18,5%) of TBFNA samples (Figure 3). Elements of lymph node or lymph node hyperplasia were found in 9/88 (10,2%) of sarcoidosis patients and 24/157 (15,3%) of TBFNA samples. These findings were non-specific and non-indicative of sarcoidosis, and were considered as negative adequate TBFNA samples. In 63,6% of our patients TBFNA cytology was the only morphological evidence of granulomatous inflammatory disease.

Sensitivity of TBFNA cytology in sarcoidosis presenting as mediastinal/hilar lymphadenopathy was 78,7% and specificity 92,3%. The positive predictive value for sarcoidosis was 97,8% and negative predictive value 60%. Overall diagnostic accuracy of TBFNA cytology in the diagnosis of mediastinal/hilar sarcoidosis was 86,2%.

DISCUSSION

Transbronchial fine needle aspiration is a minimally invasive bronchoscopic procedure, which is an effective, cost-saving method for the diagnosis and mediastinal staging of lung carcinoma, with many documented reports in the literature (2,5,6,14,15,16). Recently, new studies concerning the value of TBFNA in the diagnosis of sarcoidosis depending on the stage of disease, needle gauge and other factors have emerged (2,3,4,11,17).

In our study a small 26-gauge needle was used for TBFNA and material for cytological analysis only was obtained. Fine needle aspiration (FNA) in this location is more difficult to perform than FNA in many other sites, because the target is indirectly visualized by radiographic methods (12,18).

Inadequate material was obtained in 8,2% TBFNA of sarcoidosis presenting as mediastinal/hilar lymphadenopathy. Proportions of inadequate material ranged from 7-26% in other reports, as shown in Table 2. (3,14,15,19,20). There were differences in number of patients, needle gauges, aspiration site, and whether the material was obtained for cytological and/or histological analysis. Routinely, a 22-gauge cytology needle was used for staging and 18 or 19-gauge histology needles were used predominantly for diagnostic purposes (19).

Cytological findings consistent with sarcoidosis in our study were considered positive and specific for sarcoidosis. Positivity in mediastinal/hilar sarcoidosis in our report was 84,7% in TBFNA specimens and in 89,8% of patients, higher than positivity of TBFNA in previously reported studies, which varies from 42-72% (3,4,11,17). Trisolini and Wang have already suggested that the high density of granulomas in sarcoid lymph nodes was responsible for the high percentage of positive granuloma findings even in cytological samples (2,3). High positivity can also be partially explained by preparation technique of cytology specimens. Glass-to-glass direct smearing technique of needle content was used, with probably less negative influence on granuloma architecture and loss of cells than flush technique with cytocentrifugation, as previously reported by Trisolini et al. (3). However, the small diameter of the cytological needle used for TBFNA and glass-to-glass smearing technique, in our

opinion, can sometimes be responsible for distortion of multinucleated giant cells, with a negative effect on identification of multinucleated giant cells of Langhans type.

In 63,6% of our patient TBFNA cytology was the only morphological evidence of granulomatous disease, Trisolini et al. reported 62% (3). Lymphocytes with epithelioid cells scattered or in small clusters in TBFNA were not sufficient to diagnose a granuloma, but were also considered as specific findings consistent with sarcoidosis, forming about 25% of positive findings. Ceinkaya et al. reported tuberculosis as the most common cause of benign intrathoracic lymph node enlargement in Turkey (11). In our study, all TBFNA with epithelioid cells and without necrosis in patients with mediastinal/hilar lymphadenopathy were confirmed as specific for sarcoidosis by transbronchial lung biopsy, radiological and clinical findings and follow up.

Sensitivity and specificity of TBFNA cytology of mediastinal/hilar lymphadenopathy in the diagnosis of sarcoidosis in our material were high, 78,7% and 92,3% respectively, due to the relatively low percentage of false negatives and small number of false positives, compared with results of Trisolini et al. (table 3). Predictably, positive predictive value for sarcoidosis was 97,8% and negative predictive value was lower, i.e. 60%. Trisolini et al. reported sensitivity and specificity of 69% and 91% respectively (3). In our study, sensitivity was slightly higher, 78,7%. Diagnostic accuracy of TBFNA cytology for sarcoidosis varies from 65-76% in different studies, depending on needle size and number of patients involved (Table 3.) (3,4,11,16,17). Diagnostic accuracy for 157 TBFNA samples in 88 patients with sarcoidosis presenting as mediastinal/hilar lymphadenopathy in our study was slightly higher, i.e. 86,2%, probably due to the high percentage of cytological findings consistent with sarcoidosis even in the absence of granuloma.

The accuracy of TBFNA cytology in the diagnosis of mediastinal/hilar sarcoidosis is dependent on the needle gauge and the number of patients studied, as well as on the bronchoscopist's skill and the efficiency of the cytology laboratory.

Tables:

Cytological findings	Sarcoidosis patients (88)		TBFNA (157)	
	No	Percent	No	Percent
Findings consistent with sarcoidosis	79	89,8	133	84,7
- Elements of granuloma	63	71,6	104	66,2
- Lymphocytes, epithelioid cells	16	18,2	29	18,5
Elements of lymph node or lymph node hyperplasia	9	10,2	24	15,3
- Lymph nodes hyperplasia	3	3,4	5	3,2
- Lymphocytes	6	6,8	19	12,1

Table1. Cytological findings in 157 TBNA specimens sampled in 88 patients with sarcoidosis

Author	Ref.	Needle	Supstrate	No. patients	Inadequate samples
Trisolini	3	19 G	Intrathoracic lymphadenopathy	32	26% (cytology only)
Haponik	14	22G	Mediastinal mass, peribronchial lesion	185	8,3-25,6%
Hsu	15	21 G	Intrathoracic lymphadenopathy, peribronchial lesion	90	7-21%
Patteli	19	22 G	Intrathoracic lymphadenopathy	183	20%
Hermens	20	19 G	Intrathoracic lymphadenopathy	106	21%

Table 2.

Inadequate samples of transbronchial needle aspirations in different studies depending on needle gauge, substrate and number of patients.

Author	Ref.	Needle	No. patients	Dg. accuracy	Sensitivity	Specificity
Trisolini	3	19 G	32	72%	69% cytology 91% histology	91% cytology and histology
Pauli	4	18 G	152	72%	/	/
Cetinkaya	11	22 G	60	65-76% granulomas	/	/
Wang	16	18 G	25	72%	/	/
Morales	17	19 G	30	53%	/	/

Table 3.

Diagnostic yield of transbronchial needle aspiration in the diagnosis of mediastinal/hilar sarcoidosis

Figures:

Figure 1.

Cluster of epithelioid cells and small lymphocytes in TBFNA smear of granuloma in sarcoidosis (May-Grunwald–Giemsa stain, x200)

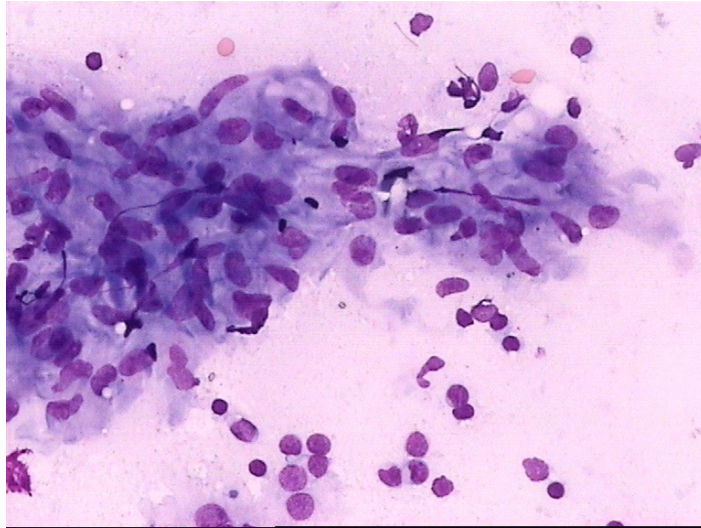


Figure 2.

Multinucleated giant cell of Langhans type in TBFNA smear of granuloma in sarcoidosis (May-Grunwald–Giemsa stain, x200)

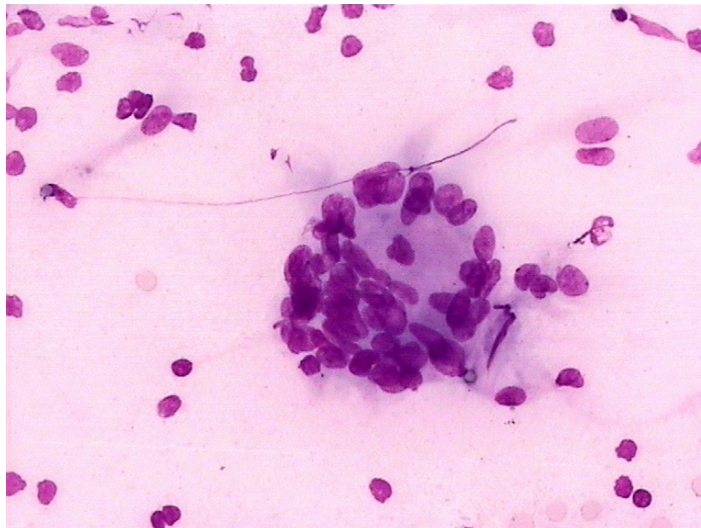
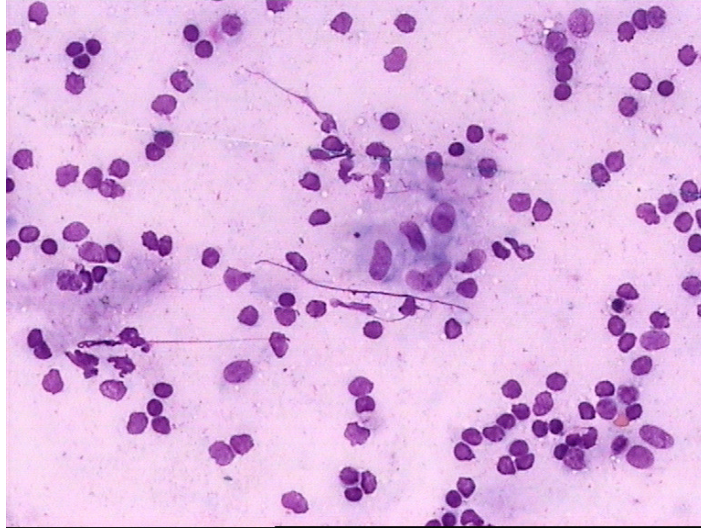


Figure 3.

Small groups or scattered epithelioid cells with lymphocytes in TBFNA smear of lymph node in sarcoidosis (May-Grunwald–Giemsa stain, x200)



REFERENCES:

1. American Thoracic Society. Statement on Sarcoidosis. *Am J Respir Crit Care Med* 1999; 160:736-755.
2. Wang KP, Brower R, Haponik EF, Siegelman S. Flexible Transbronchial Needle Aspiration for Staging of Bronchogenic Carcinoma. *Chest* 1983; 84:571-576.
3. Trisolini R, Agli LL, Cancellieri A et al. The Value of Flexible Transbronchial Needle Aspiration in the Diagnosis of Stage I Sarcoidosis. *Chest* 2003; 124:2126-2130.
4. Pauli G, Pelletier A, Bohner C et al. Transbronchial Needle Aspiration in the Diagnosis of Sarcoidosis. *Chest* 1984; 85:482-484.
5. Wang KP, Terry P, Marsh B. Bronchoscopic Needle Aspiration Biopsy of Paratracheal Tumors. *Am Rev Respir Dis* 1978; 118:17-21.
6. Wang KP, Terry PB. Transbronchial Needle Aspiration in the Diagnosis and Staging of Bronchogenic Carcinoma. *Am Rev Respir Dis* 1983; 127:344-347.
7. Harrow EM, Oldenburg FA, Lingenfelter MS, Smith AM. Transbronchial Needle Aspiration in Clinical Practice. A Five-Year Experience. *Chest* 1989; 96:1268-72.
8. Harrow EM, Oldenburg FA, Marshall Smith A. Transbronchial needle aspiration in clinical practice. *Thorax* 1985; 40:756-759.
9. Silverman JF, Marrow HG. Fine Needle Aspiratin Cytology of Granulomatous Diseases of the Lung, Including Nontuberculous Mycobacterial Infection. *Acta Cytol* 1985; 29:535-541.
10. Cetinkaya E, Yildiz P, Kadakal F, Tekin A, Soyasal F, Elbiol S, Yilmaz V. Transbronchial Needle Aspiration in the Diagnosis of Intrathoracic Lymphadenopathy. *Respiration* 2002; 69:335-338.
11. Cetinkaya E, Yildiz P, Altin S, Yilmaz V. Diagnostic Value of Transbronchial Needle Aspiration by Wang 22-Gauge Cytology Needle in Intrathoracic Lymphadenopathy. *Chest* 2004; 125:527-531.

12. Baker JJ, Solanki PH, Schenk DA, Van Pelt C, Ramzy I. Transbronchial Fine Needle Aspiration of the Mediastinum. Importance of Lymphocytes as an Indication of Specimen Adequacy. *Acta Cytol* 1990; 34:517-523.
13. Bilaçeroğlu S, Çağurici U, Günel Ö, Bayol Ü, Perim K. Comparison of Rigid and Flexible Transbronchial Needle Aspiration in the Staging of Bronchogenic Carcinoma. *Respiration* 1998; 65:441-449.
14. Haponik EF, Cappellari JO, Chin R et al. Education and Experience Improve Transbronchial Needle Aspiration Performance. *Am J Respir Crit Care Med* 1995; 151:1998-2002.
15. Hsu LH, Liu CC, Ko JS. Education and Experience Improve the Performance of Transbronchial Needle Aspiration. A Learning Curve at a Cancer Center. *Chest* 2004; 125:532-540.
16. Wang KP. Flexible Transbronchial Needle Aspiration Biopsy for Histologic Specimens. *Chest* 1985; 88:860-863.
17. Morales MCF, Patefield AJ, Strollo PJ, Schenk DA. Flexible Transbronchial Needle Aspiration in the Diagnosis of Sarcoidosis. *Chest* 1994; 106:709-711.
18. Gupta RK, Naran S, Lallu S, Fauck R. The diagnostic value of fine needle aspiration cytology (FNAC) in the assessment of palpable supraclavicular lymph nodes: a study of 218 cases. *Cytopathology* 2003; 14:201-207.
19. Patelli M, Agli LL, Poletti V et al. The Role of Fiberscopic Transbronchial Needle Aspiration in Staging of N2 Disease Due to Non-Small Cell Lung Cancer. *Ann Thorac Surg* 2002; 73:407-411.
20. Hermans FHW, Van Engelenburg TCA, Visser FJ et al. Diagnostic Yield of Transbronchial Histology Needle Aspiration in Patients with Mediastinal Lymph Node Enlargement. *Respiration* 2003; 70:631-635.