

Thrombosis of a biological pulmonary valve in a young patient on anticoagulant therapy with rivaroxaban: a case report

Strozzi, Maja; Anić, Darko; Baričević, Željko; Hrabak-Paar, Maja

Source / Izvornik: **European Heart Journal - Case Reports, 2019, 3**

Journal article, Published version

Rad u časopisu, Objavljena verzija rada (izdavačev PDF)

<https://doi.org/10.1093/ehjcr/ytz023>

Permanent link / Trajna poveznica: <https://um.nsk.hr/um:nbn:hr:105:904405>

Rights / Prava: [In copyright](#)/[Zaštićeno autorskim pravom.](#)

Download date / Datum preuzimanja: **2024-07-10**



Repository / Repozitorij:

[Dr Med - University of Zagreb School of Medicine
Digital Repository](#)



Thrombosis of a biological pulmonary valve in a young patient on anticoagulant therapy with rivaroxaban: a case report

Maja Strozzi^{1*}, Darko Anic², Zeljko Baricevic¹, and Maja Hrabak-Paar³

¹Department for Adult Congenital Heart Disease, University Clinic for Cardiovascular Diseases, Clinical Hospital Center Zagreb, University of Zagreb School of Medicine, 10000 Zagreb, Kispaticeva 12, Croatia; ²Department for Congenital Heart Surgery, University Clinic for Heart Surgery, Clinical Hospital Center Zagreb, University of Zagreb School of Medicine, Kispaticeva, Croatia; and ³Department of Diagnostic and Interventional Radiology, University Hospital Center, University of Zagreb School of Medicine, Kispaticeva, Croatia

Received 1 July 2018; accepted 20 February 2019; online publish-ahead-of-print 5 March 2019

Background

Patients with repaired tetralogy Fallot often develop severe pulmonary regurgitation (PR) and need surgical or catheter valve replacement/implantation. Early valve failure is not expected and thrombosis of a biological valve in a mid-term period after surgery on pulmonary position is rare.

Case summary

We report a 33-year-old female patient, who presented with heart failure, 18 months after surgical implantation of a biological valve on pulmonary position for severe PR, after previous complete repair. The patient was on anti-coagulant therapy with novel oral anticoagulants (NOACs) for paroxysmal atrial fibrillation. After revealing a big pulmonary valve (PV) thrombus as a cause of severe valve stenosis and right heart failure, patient was re-operated without complication. After surgery a long-term warfarin therapy was introduced. The patient had an uneventful 9-month follow-up.

Discussion

Thrombotic events after rivaroxaban therapy are rare in non-valvular disease and there is paucity of data for NOAC therapy related to valve thrombosis. In our case, severe heart failure 1 year and a half after PV replacement, in a patient taking anticoagulant therapy, was unexpected. The diagnosis of valve thrombosis was revealed by echocardiography, and confirmed by computed tomography. We did not find any sign of thrombophilia, or any mechanical reason for valve thrombosis.

Keywords

Pulmonary valve • Thrombosis • Anticoagulant therapy • Rivaroxaban • Heart failure • Case report

Learning points

- Pulmonary valve (PV) prosthesis failure, in patients after tetralogy of Fallot (TOF) repair and later PV replacement in majority of cases is the result of degeneration, rather than thrombosis.
- Thrombosis of a tissue PV is rare in absence of thrombophilia, especially in patients treated with anticoagulant therapy.
- Heart failure in early to mid-term period after PV replacement can be a result of tissue valve thrombosis.
- Therapy with novel oral anticoagulant rivaroxaban, might not prevent valve thrombosis.

* Corresponding author. Tel: +385 98/233 650, Email: maja.strozzi@gmail.com

Handling Editor: Nikolaos Bonaros

Peer-reviewers: Kate von Klemperer and Cemil Izgi

Compliance Editor: Christian Fielder Camm

Supplementary Material Editor: Peysh A. Patel

© The Author(s) 2019. Published by Oxford University Press on behalf of the European Society of Cardiology.

This is an Open Access article distributed under the terms of the Creative Commons Attribution Non-Commercial License (<http://creativecommons.org/licenses/by-nc/4.0/>), which permits non-commercial re-use, distribution, and reproduction in any medium, provided the original work is properly cited. For commercial re-use, please contact journals.permissions@oup.com

Introduction

Pulmonary regurgitation (PR) is common after tetralogy of Fallot (TOF) surgical repair. It is increasingly recognized that right-sided valve disease is not a benign lesion and that it has a significant and an independent impact on morbidity and mortality.¹ Surgical procedure often involves pulmonary valvulotomy, a transannular patch, or incision in the right ventricular (RV) infundibulum, which can all contribute to long-term PR.² Despite being well tolerated for a long time, there is evidence that PR leads to progressive RV dilatation and eccentric hypertrophy. With time, it can be conducive to RV dysfunction, exercise intolerance, ventricular arrhythmias, and, rarely, a sudden cardiac death.³ Dilatation and failure of the RV can be prevented by valve replacement.⁴ Surgical bioprosthetic valves will eventually degenerate. In pulmonary position, this can be expected to occur 5–10 years after implantation.⁵

Apart from valve degeneration, endocarditis can also be the cause of pulmonary valve (PV) failure. Valve thrombosis is considered rare.⁶ Long-term anticoagulant therapy for tissue valves is not indicated.⁷ There is, however, a positive effect on biological valve thrombosis, when there is a suspicion of it.⁸ There is so far no evidence of any positive influence of novel oral anticoagulants (NOACs) on valvular thrombus formation.

We present a case of surgical tissue PV obstruction caused by a big thrombus in a patient on anticoagulation therapy with rivaroxaban.

Timeline

Date	Events
1989	Total repair of tetralogy of Fallot
6 April 2016	Emergency admittance for atrial flutter. Successful ablation was performed. For paroxysmal atrial fibrillation (AF), anticoagulation therapy with rivaroxaban was started
30 May 2016	Pulmonary tissue valve implantation for severe regurgitation with excellent postoperative recovery. Warfarin therapy for 3 months followed by rivaroxaban for AF
20 December 2017	Admitted to our department for severe heart failure (clinical deterioration 4 weeks before admission). Biological pulmonary valve (PV) thrombosis was diagnosed, and fractionated heparin was introduced
28 December 2017	Reoperation: replacement of a thrombosed tissue valve. Uneventful postoperative course. Warfarin for long-term therapy introduced (target INR 2.5–3)
9 October 2018	Clinically without events, on transthoracic echocardiogram normal PV function without thrombus formation

Case presentation

A 33-year-old female patient was admitted to our Clinic with severe heart failure. She was referred for the first time 2 years earlier, as an emergency, for atrial flutter, frequency 215/min. An immediate cardioversion was performed, followed by electrophysiology and radiofrequency ablation and anticoagulant therapy with NOACs was introduced for paroxysmal atrial fibrillation (AF).

The young woman is an adult congenital heart disease patient, after surgical correction of TOF at the age of 4 years. She underwent ventricular septal defect (VSD) closure, right ventricle outflow tract resection, and PV repair with a Dacron annular patch. She has regularly been followed by an adult cardiologist without expertise in congenital heart disease.

At her first presentation in our hospital, echocardiographic (ECHO) examination revealed a dilated RV with already reduced systolic function and volume overload, dilated tricuspid annulus, and intermediate tricuspid regurgitation, with no evidence of residual VSD, obstruction of PV and pulmonary hypertension. A significant PR was observed, confirmed by cardiac magnetic resonance imaging, with regurgitation fraction of 41% and diastolic volume of the RV of 233 mL (116 mL/m²), with RV ejection fraction of 48%.

A surgical procedure was proposed. Pulmonary valve prosthesis implantation (SJM Biocor A 25 mm), tricuspid anuloplasty (Edwards MC 3 Tricuspid Ring 34 mm) and patch reconstruction of pulmonary artery (BioIntergral Surgical Patch) was successfully performed. Clinical recovery was fast, and postoperative ECHO indicated good function of biological prosthesis on PV position, and reduction of RV volume.

One year and a half after the surgery, the clinical course was uneventful. The patient was treated by anticoagulation therapy with warfarin 3 months after surgery, followed by rivaroxaban 20 mg daily, for paroxysmal AF.

She arrived again 18 months later, with right heart failure, after a month of progressive effort intolerance. The ECHO revealed again the dilatation of RV, this time with signs of pressure overload, and pulmonary pressure gradient of 110 mmHg (*Figure 1*). Transoesophageal ECHO (TOE) established an organized thrombus formation on the prosthesis, measuring 25 × 10 mm with an additional floating formation of 8 × 5 mm and a residual valve ‘tunnel’ of ~8 mm (*Figure 2*). The findings of electrocardiogram-triggered pulmonary computed tomography (CT) angiography were similar (*Figure 3A and B*). We did not find thrombophilia, or a mechanical reason for valve thrombosis.

Reoperation was proposed and performed: excision of a thrombosed tissue valve and re-implantation of St. Jude Biocor valve A 25 mm, in pulmonary position. The patient made a good postoperative recovery. A long-term anticoagulation therapy with warfarin was induced. Postoperative ECHO showed reduction of RV volume and an improvement in systolic function. The PV gradient was 25 mmHg. The 9-month follow-up was uneventful.

Discussion

Pulmonary valve replacement after repair of TOF is recommended before the occurrence of RV dysfunction, but the timing is still

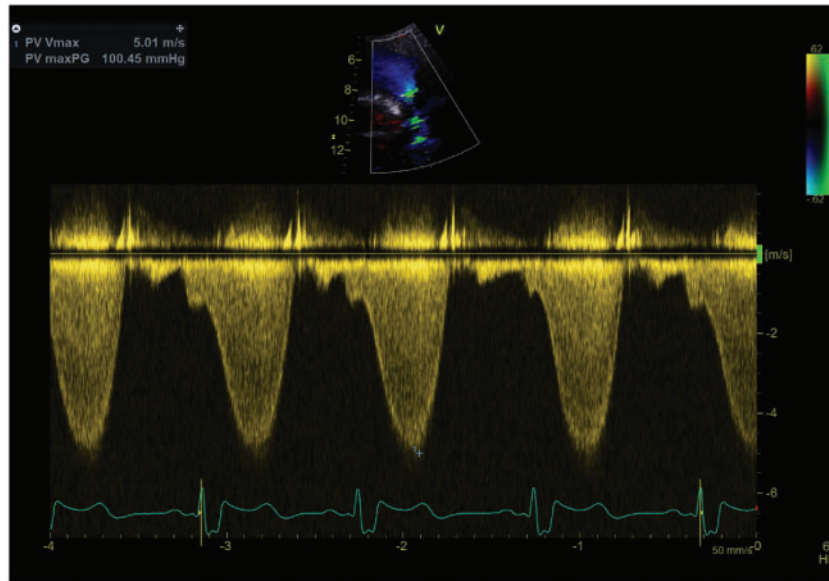


Figure 1 Continuous-wave Doppler tracing indicating severe pulmonary stenosis with maximum pressure gradient of 100 mmHg.

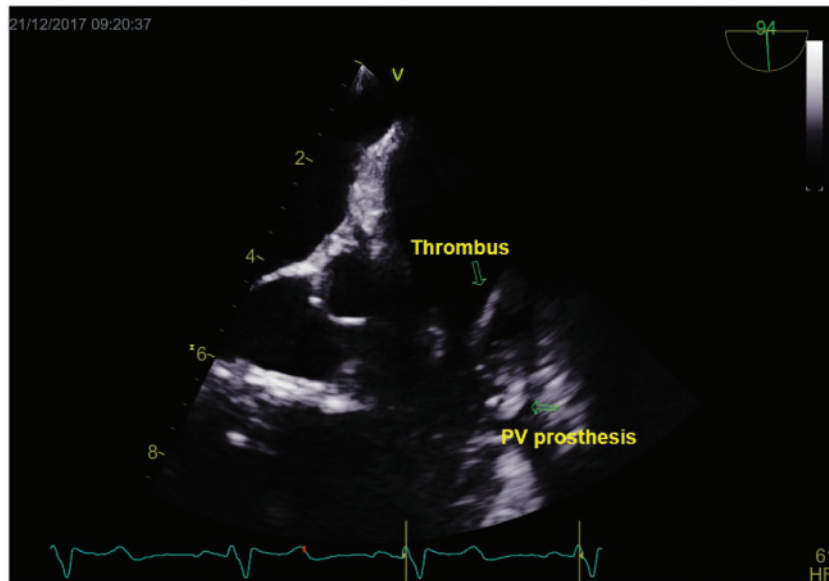


Figure 2 Transoesophageal echocardiogram showing thrombotic mass extending across prosthetic pulmonary valve into the pulmonary trunk (arrows).

controversial. Cardiac magnetic resonance imaging has become accepted as the gold standard for the assessment of RV remodelling.⁹ Despite RV diastolic volume was less than recommended for PV replacement, considering our patients RV volume overload, along with rhythm disturbances, a decision for PV replacement was made.

The effects of PR on some electrocardiographic predictors of arrhythmia, for example AF, are not clear. Restoration of PV

competence often leads to stabilization or reduction of QRS duration with a corresponding decrease in arrhythmia.¹⁰ In our case, the atrial flutter was the first presentation of hemodynamic deterioration, a long time after TOF repair.

Data concerning the best tissue valve prosthesis for use in the pulmonary position are scarce.¹¹ Literature describes several factors which influence the time of valve degeneration: the timing of surgery,

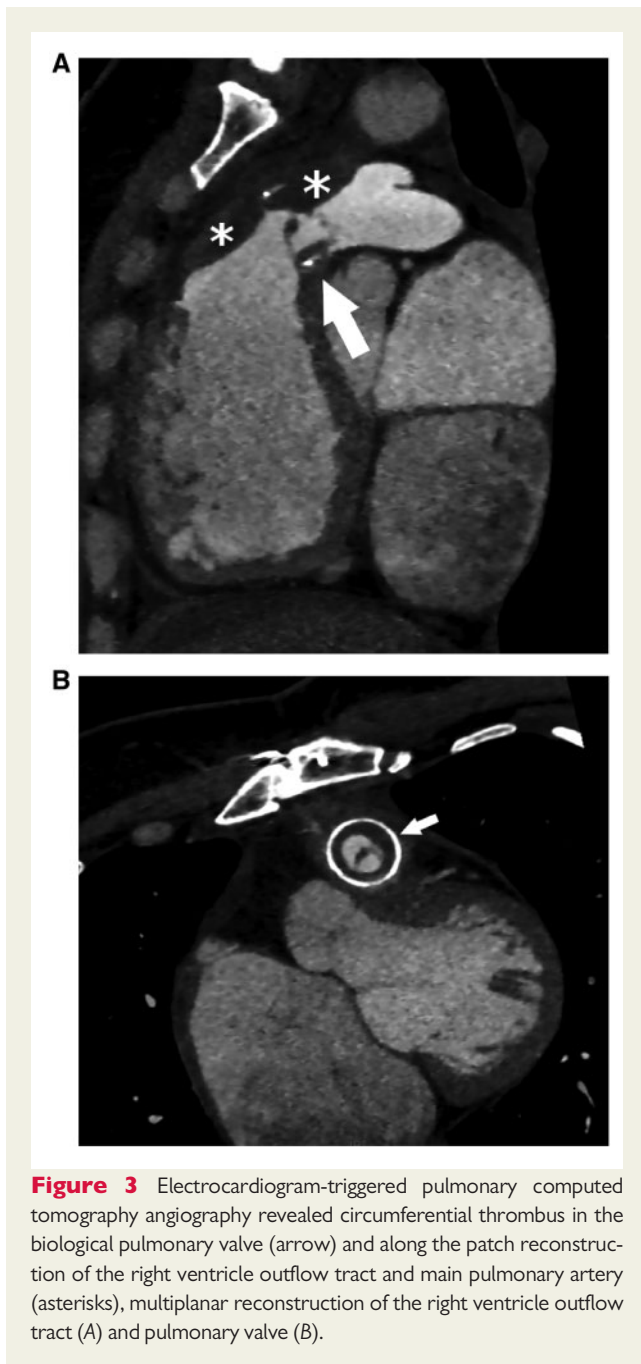


Figure 3 Electrocardiogram-triggered pulmonary computed tomography angiography revealed circumferential thrombus in the biological pulmonary valve (arrow) and along the patch reconstruction of the right ventricle outflow tract and main pulmonary artery (asterisks), multiplanar reconstruction of the right ventricle outflow tract (A) and pulmonary valve (B).

the patient's age, valve size, immunological factors, operative complexity, and also postoperative valve gradients.¹²

Bio-prosthetic valve thrombosis is a rare event, which may occur late after surgery.¹³ Patients with tissue heart valve prosthesis still have a risk of developing valve thrombosis and arterial thromboembolism. Antithrombotic therapy with warfarin in the early postoperative period is controversial, but still recommended.¹⁴ Our patient was treated with warfarin for up to three months following surgery, whereupon rivaroxaban was introduced, for long-term thromboembolic protection after paroxysmal AF.

In patients with AF, rivaroxaban was not inferior to warfarin for the prevention of stroke or systemic embolism.¹⁵ Although there is no evidence of NOAC activity in thrombotic events in valve disease, presence of any valvular disease did not influence the comparison of dabigatran with warfarin, and no difference in events was found.¹⁶ A fixed-dose regimen of rivaroxaban alone showed no inferiority to standard therapy for the initial and long-term treatment of pulmonary embolism and had a potentially improved risk benefit profile. Novel oral anticoagulants appear to be safe and effective in adult patients with congenital heart disease.¹⁷ There are no published data about influence of rivaroxaban or other NOACs on thrombotic events related to surgical tissue valves.

Echocardiographic plays an important role to the diagnosis of biological valve thrombosis and CT may be of added value.¹⁸ In our patient, PV thrombosis was first revealed by TOE, and then confirmed by CT.

Bioprosthetic valves are generally considered to carry a low risk of thrombosis and only few reports exist of the valve thrombosis. Majority data refer to left heart mechanical valves thrombosis.¹⁹ For the management, thrombolytic therapy has been suggested as an alternative to surgery. It is associated with lower mortality rate but carries the risk of embolism, bleeding, and re-thrombosis. The optimal treatment of biological valve thrombosis is still a matter of debate. Anticoagulation and operative intervention are the mainstay of treatment. A response to anticoagulation therapy is usually observed 4–12 weeks after initiation.¹³ In our case, repeated surgery was performed, expecting complete haemodynamic success in a patient with high functional class, big thrombus burden, severe valve obstruction and low surgical risk.²⁰

Supplementary material

Supplementary material is available at *European Heart Journal - Case Reports* online.

Acknowledgements

The authors would like to thank Kristina Maric Besic for the contribution in patient treatment and Margarita Brida for reweaving the submitted case report.

Slide sets: A fully edited slide set detailing this case and suitable for local presentation is available online as [Supplementary data](#).

Consent: The author/s confirm that written consent for submission and publication of this case report including image(s) and associated text has been obtained from the patient in line with COPE guidance.

Conflict of interest: none declared.

References

1. Bouzas B, Kilner PJ, Gatzoulis MA. Pulmonary regurgitation: not a benign lesion. *Eur Heart J* 2005;**26**:433–439.
2. Kirklin JK, Kirklin JW, Blackstone EH, Milano A, Pacifico AD. Effect of transannular patching on outcome after repair of tetralogy of Fallot. *Ann Thorac Surg* 1989; **48**:783–791.
3. Gatzoulis MA, Balaji S, Webber SA, Siu SC, Hokanson JS, Poile C, Rosenthal M, Nakazawa M, Moller JH, Gillette PC, Webb GD, Redington AN. Risk factors for arrhythmia and sudden cardiac death late after repair of tetralogy of Fallot: a multicentre study. *Lancet* 2000;**356**:975–981.

4. Ferraz Cavalcanti PE, Sá MP, Santos CA, Esmeraldo IM, de Escobar RR, de Menezes AM, de Azevedo OM, de Vasconcelos Silva FP, Lins RF, Lima Rde C. Pulmonary valve replacement after operative repair of tetralogy of Fallot: meta-analysis and meta-regression of 3,118 patients from 48 studies. *J Am Coll Cardiol* 2013;**62**:2227–2243.
5. Lee C, Park CS, Lee C-H, Kwak JG, Kim S-J, Shim W-S, Song JY, Choi EY, Lee SY. Durability of bioprosthetic valves in the pulmonary position: long-term follow-up of 181 implants in patients with congenital heart disease. *J Thorac Cardiovasc Surg* 2011;**142**:351–358.
6. Egbe AC, Pislaru SV, Pellikka PA, Poterucha JT, Schaff HV, Maleszewski JJ, Connolly HM. Bioprosthetic valve thrombosis versus structural failure: clinical and echocardiographic predictors. *Am Coll Cardiol* 2015;**66**:2285–2294.
7. Mérie C, Køber L, Skov Olsen P, Andersson C, Gislason G, Skov Jensen J, Torp-Pedersen C. Association of warfarin therapy duration after bioprosthetic aortic valve replacement with risk of mortality, thromboembolic complications, and bleeding. *JAMA* 2012;**308**:2118–2125.
8. Egbe AC, Connolly HM, Pellikka PA, Schaff HV, Hanna R, Maleszewski JJ, Nkomo VT, Pislaru SV. Outcomes of warfarin therapy for bioprosthetic valve thrombosis of surgically implanted valves: a prospective study. *JACC Cardiovasc Interv* 2017;**10**:379–387.
9. Buechel ER, Dave HH, Kellenberger CJ, Dodge-Khatami A, Pretre R, Berger F, Bauersfeld U. Remodelling of the right ventricle after early pulmonary valve replacement in children with repaired tetralogy of Fallot: assessment by cardiovascular magnetic resonance. *Eur Heart J* 2005;**26**:2721–2727.
10. Therrien J, Siu SC, Harris L, Dore A, Niwa K, Janousek J, Williams WG, Webb G, Gatzoulis MA. Impact of pulmonary valve replacement on arrhythmia propensity late after repair of tetralogy of Fallot. *Circulation* 2001;**103**:2489–2494.
11. Abbas JR, Hoschtitzky JA. Which is the best tissue valve used in the pulmonary position, late after previous repair of tetralogy of Fallot? *Interact Cardiovasc Thorac Surg* 2013;**17**:854–860.
12. Jang W, Kim YJ, Choi K, Lim HG, Kim WH, Lee JR. Mid-term results of bioprosthetic pulmonary valve replacement in pulmonary regurgitation after tetralogy of Fallot repair. *Eur J Cardiothorac Surg* 2012;**42**:e1–e8.
13. Pislaru SV, Hussain I, Pellikka PA, Maleszewski JJ, Hanna RD, Schaff HV, Connolly HM. Misconceptions, diagnostic challenges and treatment opportunities in bioprosthetic valve thrombosis: lessons from a case series. *Eur J Cardiothorac Surg* 2015;**47**:725–732.
14. Gherli T, Colli A, Fragnito C, Nicolini F, Borrello B, Saccani S, D'Amico R, Beghi C. Comparing warfarin with aspirin after biological aortic valve replacement. A prospective study. *Circulation* 2004;**110**:496–500.
15. Patel MR, Mahaffey KW, Garg J, Pan G, Singer DE, Hacke W, Breithardt G, Halperin JL, Hankey GJ, Piccini JP, Becker RC, Nessel CC, Paolini JF, Berkowitz SD, Fox KAA, Califf RM. Rivaroxaban versus warfarin in nonvalvular atrial fibrillation. *N Engl J Med* 2011;**365**:883–891.
16. Ezekowitz MD, Nagarakanti R, Noack H, Brueckmann M, Litherland C, Jacobs M, Clemens A, Reilly PA, Connolly SJ, Yusuf S, Wallentin L. Comparison of dabigatran and warfarin in patients with atrial fibrillation and valvular heart disease: the RE-LY Trial (Randomized Evaluation of Long-Term Anticoagulant Therapy). *Circulation* 2016;**134**:589–598.
17. Pujol C, Niesert A-C, Engelhardt A, Schoen P, Kusmenkov E, Pittrow D, Ewert P, Kaemmerer H. Usefulness of direct oral anticoagulants in adult congenital heart disease. *Am J Cardiol* 2016;**117**:450–455.
18. Egbe A, Pislaru SV, Ali MA, Khan AR, Boler AN, Schaff HV, Akintoye E, Connolly HM, Nkomo VT, Pellikka PA. Early prosthetic valve dysfunction due to bioprosthetic valve thrombosis: the role of echocardiography. *JACC Cardiovasc Imaging* 2017; pii:S1936-878X(17)30797-0.
19. Bonou M, Lampropoulos K, Barbetseas J. Prosthetic heart valve obstruction: thrombolysis or surgical treatment? *Eur Heart J Acute Cardiovasc Care* 2012;**1**:122–127.
20. Roudaut R, Serri K, Lafitte S. Thrombosis of prosthetic heart valves: diagnosis and therapeutic considerations. *Heart* 2007;**93**:137–142.