

Laporovaginal surgery in cervical cancer: a Croatian experience

Ćorušić, Ante; Barišić, Dubravko; Plavec, Andrea; Planinić, Pavao;
Škrkatić, Lana; Vujić, Goran; Herman, Mislav

Source / Izvornik: **Collegium Antropologicum, 2007, 31, 147 - 154**

Journal article, Published version

Rad u časopisu, Objavljena verzija rada (izdavačev PDF)

Permanent link / Trajna poveznica: <https://um.nsk.hr/um:nbn:hr:105:587028>

Rights / Prava: [In copyright](#)/[Zaštićeno autorskim pravom.](#)

Download date / Datum preuzimanja: **2024-07-15**



Repository / Repozitorij:

[Dr Med - University of Zagreb School of Medicine
Digital Repository](#)



Laporovaginal Surgery in Cervical Cancer: A Croatian experience

Ante Ćorušić, Dubravko Barišić, Andrea Plavec, Pavao Planinić, Lana Škrgeć, Goran Vujić and Mislav Herman

Department of Gynecology and Obstetrics, Medical School, University of Zagreb, Zagreb, Croatia

ABSTRACT

With correct staging a large number of patients with cervical cancer FIGO stages IA2 and IB can be spared of unnecessary radiation therapy by laparoscopic assisted vaginal radical hysterectomy (LAVRH) as an option of radical surgical treatment in such patients. The development of laporovaginal surgery, indication and contraindication were presented. Also, the surgical technique was described in detail. Fifty-two patients were followed up in 2003 after LAVRH or open surgery, performed in our single center. Only 5 (14%) patients died from cervical cancer within 3 years following the treatment. They were all clinical stage IB treated with open surgery. There were 4 (11%) complications following treatment and they were all in patients with clinical stage IB, also treated with open surgery. There was no complication in LAVRH treated patients. The results and complications of the sole Croatian center performing LAVRH or open surgery in patients with cervical cancer FIGO stages IA and IB were similar to those in centers across the world.

Key words: cervical cancer; FIGO stage IA2 and IB, laparoscopic assisted vaginal radical hysterectomy, Schauta operation

Introduction

Development of vaginal surgery

The first written traces on surgical treatment of cervical carcinoma reach back to the 16th and 17th centuries¹ when amputation of cervical tumors was performed. At the end of the 18th century, Marschall and Schroder as well as Osiander, at the beginning of the 19th century, recommend »partial trachelectomy« in patients with prolapsing cervical carcinoma¹. In 1813, Langenback performed »subperitoneal removal« of prolapsed cervical carcinoma^{1,2}. He used tying of blood vessels as hemostasis. In 1821, Sauter operated a patient with cervical carcinoma through the vagina, by opening the peritoneum and removing the uterus without the use of ligatures in bleeding control. The patient developed vasovaginal fistula and died four weeks following the surgery for unknown reasons, even though the author did not mention perioperative bleeding³. This type of surgical technique was developed for the following twenty years. The five-year survival rate for all stages of the disease was around 10%¹. By developing surgical technique (haemostatic clip) and introducing Lister's aseptic principles, Czerny reduced perioperational mortality to 32%^{1,4}. In

1880, the Czech gynecologist Pawlik performed extended vaginal hysterectomy, in a patient with advanced cervical carcinoma⁴. Thirteen years later, Schuhardt described radical vaginal hysterectomy with help of »paravaginal help incision«⁴.

Staude also performed extended vaginal hysterectomy in 1894, using two Schuhardt's incisions to improve the operating approach⁵. At this time, Reis, Rumpf, Kelly and Wertheim developed abdominal radical hysterectomy as a method of choice in treating cervical carcinomas. They emphasize that the mere removal of the organ is not sufficient but it is necessary to remove the regional lymph nodes as places of supposed spreading of the disease^{1,4,6,7}. However, high perioperative mortality (18.6%) in that period distanced most gynecologists from the laparotomy approach. In June 1901, in Vienna, Schauta performed the first radical hysterectomy through the vagina, and published his experience in treating cervical carcinoma in 258 cases in 1908⁸. Since that time, radical vaginal hysterectomy has mostly been called Schauta's operation, particularly emphasizing preparation of the urinary bladder and preserving the ureter. Amreich fur-

ther improved the original Schauta's operation. His experiences in 1505 cases were published in 1943⁹. In comparison to Schauta's operation, the Amreich's approach involves more radical resection of the dorsal part of lateral parametria. In Germany, Stoeckel modified Schauta's operation and introduced the principle of mandatory preparation of the ureter. While Schauta only inserted the ureter proximally, Stoeckel introduced systematic anatomical preparation of the ureter¹⁰.

Bearing in mind the radical nature of removing the parametria, Wertheim and Schauta's operations are complementary. Both approaches, according to the Routledge classification, belong to the type II of radicalness, i.e. the medial half of cardinal and sacrouterine ligaments is being removed. The Mackenrodt-Latzko-Meigs operation is as radical as the Schauta-Amreich operation and, according to the Routledge classification, falls into the type II-II of radicalness^{11,12}. Complete resection of the parametria by vaginal approach is not possible.

Development of laparoscopy

Lymphogenic spreading of cervical carcinoma is the primary route of transmission of the disease. In approximately 15% of stage I cervical carcinoma cases metastases into pelvic lymph nodes were detected. As far back as 1895, Ries supposed that the removal of iliacal lymph nodes should be the key part of surgical treatment of cervical carcinomas^{1,4}.

With time, individual authors combined lymphadenectomy with radical vaginal hysterectomy. Stoeckel combined radical vaginal hysterectomy with transperitoneal pelvic lymphadenectomy in individual cases^{10,13}. Mitra in India and Navratil in Austria, combined extraperitoneal lymphadenectomy according to Nathanson, with radical vaginal hysterectomy^{13–15}. Mitra performed extraperitoneal lymphadenectomy three weeks after the vaginal operation. In Europe this method was accepted by van Bastianse and Inquilla^{1,13,16}. However, these operative techniques were not widely accepted because, at that time, the Wertheim's operation was the »golden standard« in surgical treatment of cervical carcinomas. Due to this fact, radical vaginal operation was »neglected« for a long time in treating cervical carcinomas. Development of laparoscopy enabled the reaffirmation of radical vaginal hysterectomy. In 1969, Bartel described pelvic retroperitoneoscopy. By using the Carlens' mediastinoscope, modified according to Maasen, through an incision cut along the spina iliaca anterior, he explored the retroperitoneal region ventrally from spinae¹⁷. In 1973, Wittmoser insufflated CO₂ into the retroperitoneum to have a better view when performing lumbar sympathectomy¹⁸. With time, the retroperitoneoscopic technique was improved. In 1987 Dargent, using the pelviscope (laparoscope), was the first to perform retroperitoneal interiliacal lymphadenectomy in the same session as radical vaginal hysterectomy¹⁹. He was the first to actualize the extended vaginal hysterectomy. Two years later, Querleu introduced transperitoneal pelvic lymphadenectomy laparoscopically. He removed the »interiliacal lymph

node packet« between the arteria umbilicalis and the vena iliaca externa laparoscopically²⁰. Canis was the first to publish »endoscopic radical hysterectomy type II« in 1990²¹. A year later, Querleu published the »laparoscopically assisted vaginal radical hysterectomy according to Schauta«²². At that time Dargent improved the operational technique. He laparoscopically resected the proximal and dorsal part of the lateral parametria, prepared the ureter vaginally and standardized this surgical operation in 1992 as the laparoscopically assisted radical vaginal hysterectomy (LAVRH)^{23–25}.

Operative Procedures

Laparoscopic lymphadenectomy and radical vaginal hysterectomy – LAVRH

Two surgeons operate, each operating a contralateral side, the patient is in the lithotomic position (»supine position«). The operation is performed under general anesthesia and indwelling of the urinary catheter is mandatory. Through an infraumbilical incision, a 10 mm trocar is inserted and through it, a telescope. Under visual control we insert additional 5 mm of the trocar, one in the medial line, two transversal fingers above the symphysis and two lateral at around 3 cm, laterally and cranially from the *arteria epigastrica inferior*. Our approach and operative technique are based on the experiences of Possover and Schneider^{26–30}. The operation begins with inspection of the whole abdomen. The patient is then put into the Trendelenburg's position at 30 degrees. Using the bipolar electrodes and scissors, we mobilize the caecum and the sigma in order to detach them from the lateral pelvic wall. The right side is operated first. After this, using the bipolar electrode and the scissors, we perform resection of the *ligamentum teres uteri* (Figure 1). With the help of the blunt preparation procedure, we open the Wagner's pit and show the *musculus iliopsoas*. Then we identify the *ligamentum umbilicale laterale* (obliterated *arteria umbilicalis*) (Figure 2). Using firm grasp forceps, we grip that ligament and pull it medially. Medially and ventrally from it, where the urinary bladder is situated. Pushing the urinary bladder medially, we secure access to the interiliacal lymph nodes and the *fossa obturatoria*. Then we show the *arteria iliaca externa* and remove it from the muscle iliopsoas. The fat tissue with lymph nodes is situated between the muscle iliopsoas and the *arteria iliaca externa*. Laterally from this tissue, there is the *nervus genitofemoralis* requiring extra precautions. During this preparation caution is also required with numerous branches of *arteria iliaca externa*, which need to be coagulated. The lower limit of dissection of the lymph nodes along the *arteria iliaca externa* is the *vena circumflexa ilium profunda*, which is situated dorsally from the *ligamentum inguinale*. By pulling the fat tissue with the lymph nodes dorsally, using blunt preparation we show the *vena iliaca externa*. Laterally and dorsally from it, there is the *nervus obturatorius* which is showed with blunt preparation (Figure 3). Medially from the nerve in the fat tissue, the surface

obturator lymph nodes are situated, and laterally are the deep obturator lymph nodes. The lateral dissection limit is the *fascia muscoli obturatorii internus*. In the obturator opening, along with the nerve, the arteria and vena obturatoria also enter. If these blood vessels are injured during preparation, they can be coagulated with no fear. During the preparation of the obturator nerve, it should not be injured because its injury causes paresis of the adductor muscles of the upper leg. After »cleaning« the obturator pit, the fat tissue with the lymph nodes »en block« is being pulled proximally and laterally. In the triangle between a. and v. *iliaca externa* and the a. and v. *iliaca interna*, caution is required because this region contains numerous branches of the v. *iliaca interna*. By pulling the fat tissue with the lymph nodes further proximally, by blunt preparation with coagulation with bipolar electrodes we come to bifurcation of the arteria iliaca communis. This is the upper limit of dissection. Thus, »en block« resection of the iliacal, interiliacal and obturator lymph nodes has been performed (Figure 4).

The same procedure is repeated on the left side. Following this, we go on to the mobilization of the ureter and proximal resection of the parametria. By removing the obturator lymph nodes, we show the *fossa paravesicalis* (Figure 5). Mobilization of the ureter shows the starting point of the *arteria iliaca interna*. Dorsally and caudally from the *arteria uterina* is the *fossa pararectalis*. The *fossa pararectalis* and the *fossa paravesicalis* are divided by the *ligamentum cardinale*. When the *ligamentum cardinale* is optimally shown using blunt preparation and coagulation with a bipolar electrode, the resection is performed »step by step« exclusively on the vascular part of the cardinal ligament. When performing the resection, we have to be careful about the *pars nervosa ligamenti cardinali* because there the *nervi splanchnici pelvini* are situated, which are very important for normal functioning of the rectum and urinary bladder. In case there are problems with bleeding, we can easily coagulate the *arteria iliaca interna*. The cardinal ligament is resected caudally to the level of the *arteria iliaca interna*. Then we coagulate and cut the *arteria uterina* on the level of the starting point of the *arteria iliaca interna*. Then, in several steps, we resect the proximal (supraureteral) part of the »bladder pillars« and after this, using bipolar electrodes and scissors, we detach the peritoneum of the urinary bladder from the uterus (*plica vesicouterina*)^{28,29}. This finishes the laparoscopic part of the surgery and we proceed with the transvaginal part of the surgery.

The patient is put into the position for a vaginal operation (candy cane position). The vaginal membrane is clamped with six straight traumatic clamps and infiltrated with vasoconstricting solution (2% mixture of xylocain and adrenaline). Using a monopolar electrode, we circumcise the whole circumference of the uterus to the dorsal and ventral vaginal fascia. We circumcise 1.5–2 cm of the uterine membrane from the vaginal-cervical point of connection. A »vaginal cuff« is closed with an extended stitch, then we remove the urinary catheter. By pulling the vaginal cuff ventrally, we show the septum rectovaginale.

By pulling the vaginal cuff caudally and dorsally using scissors, we detach the dorsal side of the urinary bladder from the uterus and the cervix (Figure 6). The preparation must be exactly in the medial line to the *plica vesicouterinae* that was previously laparoscopically prepared. When we have completely detached the bladder from the vagina and the uterus a Breisky speculum is introduced, and the bladder is pushed ventrally. Then we proceed with opening of the *fossae paravesicales*. The medial side of the bladder pillars was shown during the preparation of the urinary bladder. Now preparation of the lateral side follows.

The vaginal membrane is clamped with Kocher clamps on the left side at »1 and 3 o'clock« and on the right side at »9 and 11 o'clock«. Using scissors, we make blunt preparation in the lateral-dorsal direction, thus detaching the lateral part of the bladder pillars from the endopelvic fascia. After this, identification of the ureter follows. The ureter is identified with help of the »click manoeuvre«³⁰. Namely, the collateral index finger is set on the medial side of the bladder pillars and a Peham clamp on the lateral side in a way that top of the clamp is directed to the laterodorsal direction. Between the clamp and the finger, we can clearly feel the ureter. By moving the Peham clamp dorsomedially and using the finger to push the ureter cranially, we detach the ureter from the distal part of the bladder pillars. When we have showed the ureter, we resect and bind the distal part of the bladder pillars (Figure 7). Using the ureteral clamp, we pull the ureter caudally and see if there is some unresected supraureteral part of the bladder pillars which are then resected, using a clamp, and then bound. Then we introduce a Breisky speculum into the Douglas and push the rectum dorsally. At the same time, using another Breisky speculum, we push the bladder and the ureter ventrally. In this way we show the rectal pillars that are gripped by a strong clamp (Wertheim clamps), we cut and bind. In this way the preparation is completely removed (Figure 8).

The *sacrouterine ligamentum* is fixated to the back membrane of the vagina using a 2.0 vycril stitches and the uterus is closed using individual vycril 2.0 stitches.

In the end, the intraabdominal operation field is checked laparoscopically and drained using the drain 14Ch through a suprapubic cut.

Laparoscopically assisted radical vaginal trachelectomy – LAVRT

Cervical carcinomas are spread primarily by metastasizing into the regional lymph nodes and infiltrating into the parametria. Vertical invasion into the uterus body is relatively rare and described only in cases when the primary tumor is > 4 cm in diameter. Patients suffering from cervical carcinoma of the FIGO stage of the disease IA2 and IB1 have a 5–15% chance of metastasizing into the regional lymph nodes. In the IA2 stage of disease, risk of invasion into the parametria is negligible³¹. Therefore, the fertile ability of those patients can be preserved. It is sufficient to perform thorough conization

LAVRH – laparoscopic assisted vaginal radical hysterectomy

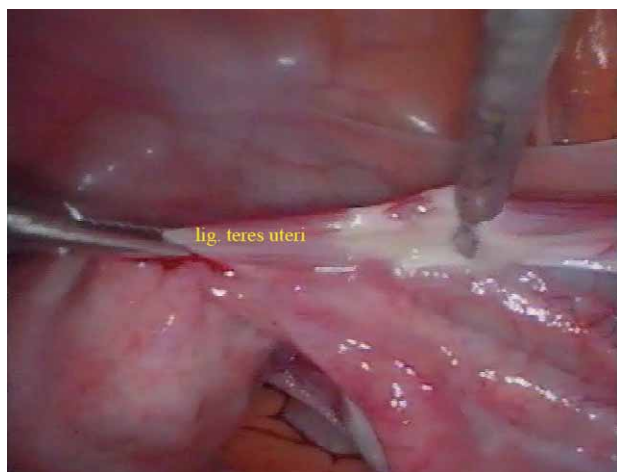


Fig. 1. Coagulation and resection of the ligamentum teres uteri during LAVRH.

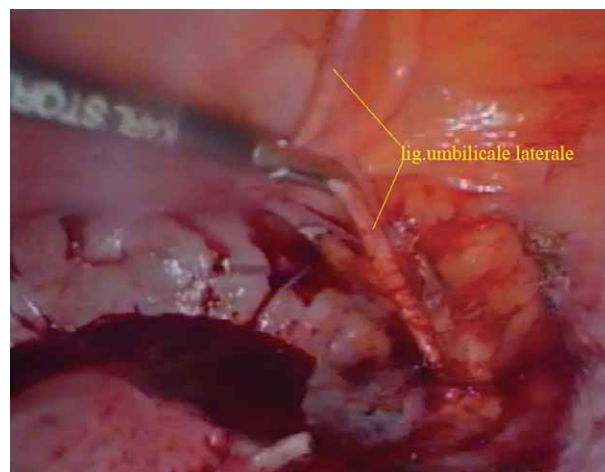


Fig. 2. Identifying of the ligamentum umbilicale laterale during LAVRH.

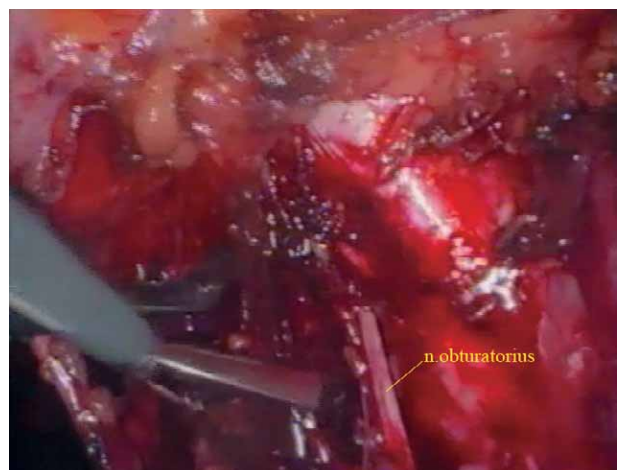


Fig. 3. Preparation of the nervus obturatorius during LAVRH.

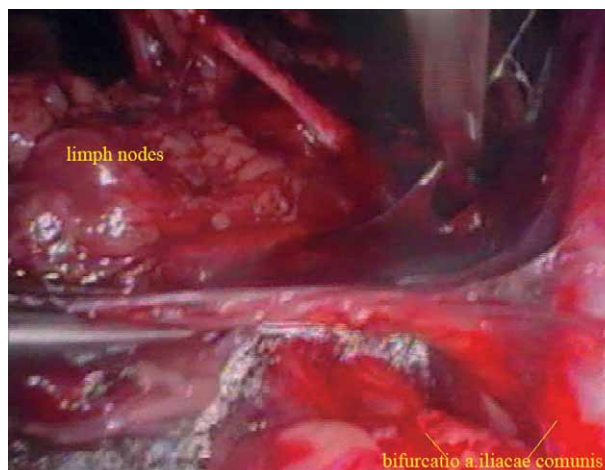


Fig. 4. Bifurcation of the arteria iliaca communis – the upper limit of dissection in LAVRH.

and laparoscopic pelvic lymphadenectomy in cases where edges and top of the conus are free, and the lymph nodes negative, for this stage of the disease³¹.

At the IB1 stage of the disease risk of invasion into the parametria grows with size of the tumor and depth of penetration into the stroma³¹. However, fertility can be preserved in this stage of the disease as well. In 1995, Dargent was the first to report on a modified Schauta-Amreich radical vaginal surgery where the body of the uterus was preserved. He called this new operational technique radical vaginal trachelectomy³². For the past ten years several authors have reported on their experience with radical vaginal trachelectomy combined with laparoscopic pelvic lymphadenectomy^{33–35}. Debates on which indications point to LAVRT are led as long as today. Burnett has analyzed results of four large series with a total of 152 patients with the follow-up period of

23–47 months. Four (2.5%) patients have developed a relapse within the follow-up period³⁵. Similar results were published by Dargent³⁶.

Disease relapses occurred in patients where the primary tumor was > 2 cm. Hence, most authors consider that LAVRT is indicated for patients under the age of 40 with cervical tumor < 2 cm and who want to preserve their fertility. Presurgical procedures include the MRI for accurate assessment of the tumor size or possible invasion into the parametria.

The surgical technique is similar to that of the LAVRH. First, laparoscopically, we remove all pelvic lymph nodes. Frozen section is obligatory. In case the lymph node is positive, the operation is discontinued and the patient is referred to chemoradiation therapy or LAVRH is performed. In case the removed lymph nodes are negative,

LAVRH – laparoscopic assisted vaginal radical hysterectomy

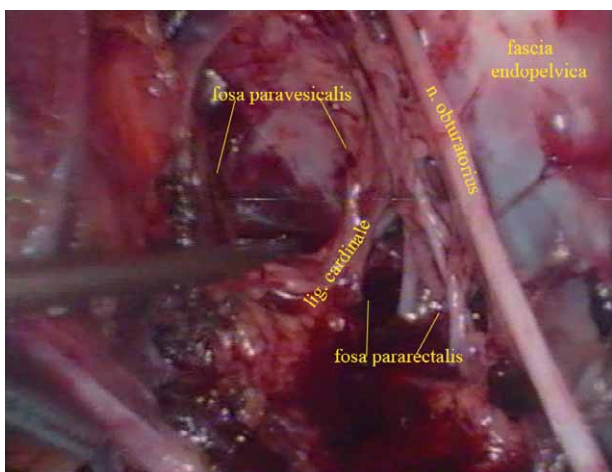


Fig. 5. Fossa paravesicalis and pararectalis after removing obturator lymph nodes in LAVRH.

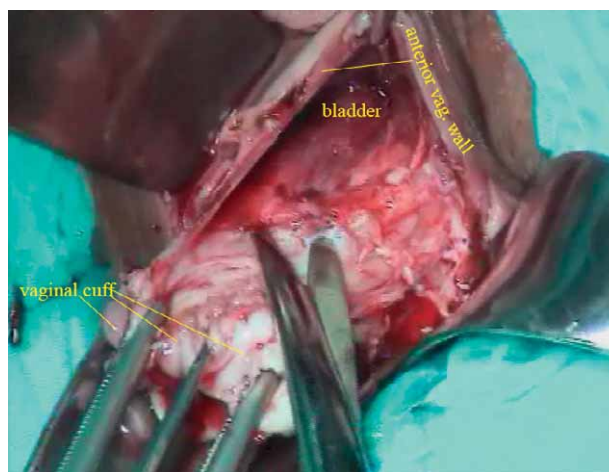


Fig. 6. Detaching the dorsal side of the

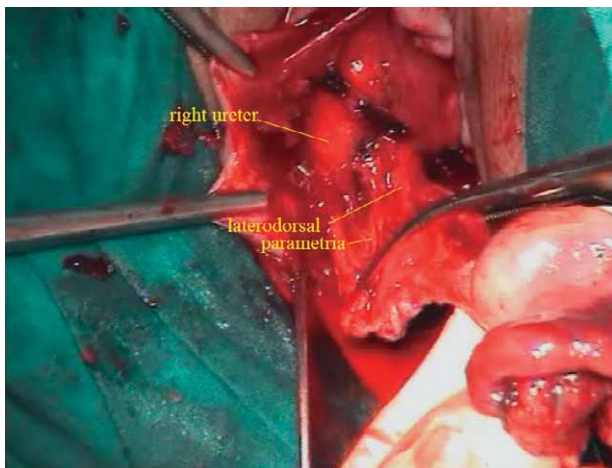


Fig. 7. Right ureter and resection of the laterodorsal parametria during LAVRH.

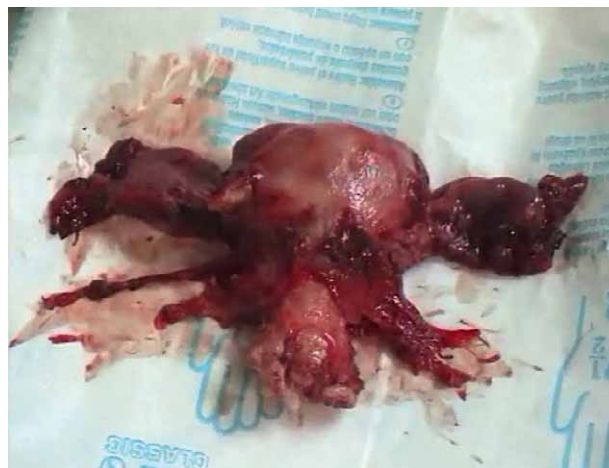

Fig. 8. Specimen of the resected uterus after

the vaginal part of the procedure is continued. The preparation should ideally contain 1–2 cm of the uterus, the whole cervix and 1–2 cm of the lateral parametria. After removing the preparation, frozen section is performed. In cases where edges of the preparation are free the procedure is finished by reconstructing the vagina and forming the »new exocervix«, using the classical Sturmdof technique.

In cases where edges of the preparation are positive to frozen section, LAVRH is to be performed. All risks involved must be carefully explained to the patient prior to the procedure.

Numerous pregnancies have been described in patients who underwent LAVRT but with a large number of spontaneous abortions (40%) and a significant number of premature births³⁷.

LAVRT is a new surgical technique and represents an important step in the development of surgical policy on treating cervical carcinoma. It requires enormous experience of the surgeon, both in the area of vaginal surgery and in the area of invasive (radical) laparoscopic pelvic surgery. Therefore, LAVRT is to be performed exclusively in highly specialized institutions that have a well tuned-in surgical team and an expert pathology team when interpretation of the frozen section pathohistological results is concerned.

Results and Discussion

In our single center 52 patients with cervical cancer FIGO stage IA and IB underwent either open surgery or LVRH in the 2003 and were followed up for at least 3 years. The distribution of patients according to clinical

stage, infiltration of parametrium, type of operation, number of lymph nodes removed is presented (Table 1 and 2). Pathohistological findings include 10 (19%) patients with *adenocarcinoma*, 8 (16%) with *adenosquamous carcinoma* and 34 (65%) with *planocellular carcinoma*. The survival rate and time period to recurrence of the disease according to clinical stage is presented (Table 3). Only 5 (14%) patients died from cervical cancer *within 3 years following the treatment*. They were all FIGO stage IB and all underwent open surgery. There were 4 (11%) complications following treatment and they were all in patient FIGO stage IB, also only in open surgery treated patients. Two postirradiation ileitis and two hydro-nephrosis were reported. The distribution of complications following treatment according to the type of surgery is presented in Table 4. There were no complications in patients treated with LAVRH.

It was already mentioned that Wertheim performed the first radical surgery of cervical carcinoma in 1898. The same year, Marie Curie discovered radium, the application of which in medicine began four years later^{1,37}. A whole century has passed in debates on which modality

of treating cervical carcinomas (surgical or via radiation therapy) is more efficient. While gynecologists and oncologists agree that, for stages of the illness of IIB and above, chemoradiation is the optimal choice, there has been continuous doubt about which modality of treatment is best for stages IB and IIA. Landoni tried to resolve these doubts. According to his research, the survival rate of patients with stages IB and IIA depends exclusively on the size of their tumor, not on the modality of treatment³⁸. The results of our study which include patients treated by open surgery or LAVRH support this conclusion because we show that survival rate in 3 years for patients FIGO stage IA2 is 100% regardless the type of surgery and 91.7% in patients with FIGO stage IB1 treated with LAVRH (Table 3).

The benefits of surgical treatment need to be pointed out: preservation of the ovarian function and preservation of the vaginal function (lubrication, stenosis). Apart from this, together with correct staging, a large number of patients with disease stages IB and IIA can be spared of unnecessary radiation therapy³⁹. Therefore, Dargent emphasizes: »Surgery in comparison with radiotherapy is a single step treatment: instant treatment with complete response obtained in a few hours«³⁷.

Most gynecologists including our team today consider the primary surgical treatment a method of choice for tumors < 4 cm. With respect to the fact that only 15% of cervical carcinomas of this size have regional metastases, this stage of disease is ideal for »surgical-pathological staging«. Regardless of the fact that FIGO has not accepted it so far. This approach includes postoperative radiation of patients whom are found to have: metastases into lymph nodes or infiltration of the parametria or infiltration > ½ of the cervix thickness or lymphovascular space involvement (LVSI). This information is obtained only after a radical surgery. This is the advantage of the laparo-vaginal approach. Namely, a surgeon starts the operation with laparoscopic pelvic lymphadenectomy. During the procedure »ex tempore« the removed lymph nodes are subject to pathohistologic examination. In cases where metastases in the lymph node are found, the op-

TABLE 1

THE DISTRIBUTION OF PATIENTS ACCORDING TO CLINICAL STAGE OF CERVICAL CANCER, MEDIAN AGE AND INFILTRATION OF PARAMETRIUM

Type of operation (N)	Clinical stage	Number of patients N (%)	Median age (year)	Infiltration of parametrium N (%)
Open surgery (38)	I A 1*	3 (8%)	37	0
	I A 2	12 (31%)	36	0
	I B	23 (61%)	43	3 (13%)
	Total	38	38.7	3 (8%)
LAVRH (14)	I A 2	2 (14%)	34	0
	I B1	12 (86%)	40.5	1 (8%)
	Total	14	37.4	1 (7%)

*radical surgery was performed only when lymphovascular space involvement (LVSI) was positive in cone biopsy

TABLE 2

THE DISTRIBUTION OF TYPE OF SURGERY, NUMBER OF REMOVED LYMPH NODES ACCORDING TO CLINICAL STAGE OF CERVICAL CANCER

Type of operation (N)	Clinical stage	Type of surgery		Number of removed lymphnodes	Mean number of lymph nodes per patient
		Rutledge II N (%)	Rutledge III N (%)		
Open surgery (38)	I A 1*	1 (7%)	2 (8%)	42	21
	I A 2	10 (71%)	2 (8%)	211	17.5
	I B	3 (21%)	20 (84%)	454	19.7
	Total	14 (37%)	24 (63%)	707	19.4
LAVRH (14)	I A 2	2 (100%)	0	35	17.5
	I B1	0	12 (100%)	228	19.0
	Total	2 (14.3%)	12 (85.7 %)	263	18.8

*radical surgery was performed only when lymphovascular space involvement (LVSI) was positive in cone biopsy

TABLE 3
THE DISTRIBUTION OF PATIENT ACCORDING TO NUMBER OF METASTASIS, RECURRENCE OF DISEASE FROM CERVICAL CANCER AND SURVIVAL RATE

Type of operation	Clinical stage (N)	Patients with metastasis N (%)	Total number of metastasis	Patients with recurrence disease (N)	Period (months)	Survival rate (3-years)
Open surgery	I A 1* (3)	0	0	0	0	100%
	I A 2 (12)	0	0	2	17	100%
	I B (23)	6 (26%)	16	7	19	78%
LAVRH	I A 2 (2)	0	0	0	0	100%
	I B (12)	2 (17%)	3	1	18	91.7%

LAVRH – laparoscopic assisted vaginal radical hysterectomy, *radical surgery was performed only when lymphovascular space involvement (LVSI) was positive in cone biopsy

TABLE 4
THE DISTRIBUTION OF COMPLICATION ACCORDING TO THE TYPE OF OPEN SURGERY OF CERVICAL CANCER

Type of surgery (N)	Postirradiation <i>ileitis</i> N (%)	<i>Hydronephrosis</i> N (%)	Total N (%)
Rutledge II (15)	0	1	1 (6.7%)
Rutledge III (23)	2	1	3 (13.0%)
Total (38)	2 (5%)	2 (5%)	4 (10.5%)

eration is discontinued and the patient is referred to chemo-irradiation treatment. In cases where there are no metastases in the lymph nodes, radical vaginal hysterectomy is continued. If the already mentioned risk factors are found on the removed preparation, the patient is referred to additional radiation treatment. There is no evidence that radio-therapy treatment following LAVRH has the higher morbidity rate than following open abdomen operations³⁸. Patients with a tumor < 2 cm are ideal for this operation. Namely, regardless of histologic type of the tumor, if parametria, lymph nodes and LVSI are negative, there is no chance of a relapse.

In tumors > 2–4 cm we need to be more cautious in setting the indication for LAVRH. In such patients, in spite of the negative lymph nodes and negative LVSI, the relapse risk is around 15%. If metastases were detected in pelvic lymph nodes, or there is a case of histologically aggressive tumor (small cell cancer, neuroendocrine cancer), relapse of the disease is present in 30–50% of the cases²⁶.

Contraindications for LAVRH include a tumor > 4 cm or poor histologic type. When assessing the tumor size, only MRI is used. The presence of enlarged regional lymph nodes does not necessarily represent a contraindication for LAVRH. In case the MRI shows an enlarged lymph node, laparoscopy is indicated. During the procedure, the lymph node is removed and sent to urgent histologic examination. If the frozen section result is negative, laparoscopic lymphadenectomy is continued, followed by radical vaginal hysterectomy. If the lymph node is positive, the operation is discontinued and the pa-

tient is referred to an oncologist for chemoirradiation. In case during laparoscopy we find a »bulky« lymph node, it is recommended to remove it and mark its spot with metal clips to ease the radio-therapist's plan for radiotherapy.

Several key questions arise here: (1) Can the frozen section be given absolute trust? In case the lymph node is positive, (2) does the uterus need to be preserved for future brachytherapy? (3) Do we need to continue with lymphadenectomy because the removal of tumorous metastases makes the following radiation treatment more effective? (4) Do we need to continue the LAVRH or (5) go on with the open abdomen surgery?

So far, we have no clear answers to these questions but most gynecologists-oncologists believe that in such situations »pelvic clearance« needs to be performed, and then the patient referred to further chemoirradiation treatment.

The efficacy of LAVRH was shown in a series of 200 patients with FIGO stage IA1 to IIB cervical cancer. This is the largest reported study⁴⁰. They reported follow up for at least 40 months and overall survival rate was 83 %. Comparing our overall survival rate in patients with cervical cancer FIGO stage IA2 and IB which was 92.8% show that we had the same success with the same complications rate. We did not perform this procedure in patients with cervical cancer FIGO stage IIB, so this was probably the reason why our survival rate is slightly higher than in the study by ⁴⁰. One possibility why we did not have complication in LAVRH treated patients is the small number of procedures (14), but the lack of complications in LAVRH treated patients supports the conclusion that with correct staging a large number of patients with cervical cancer FIGO stages IA2 and IB can be spared of unnecessary abdominal radical surgery; because the survival rate, number and severity of complications is almost the same^{41,42}. Several other observational studies support these conclusions^{40–46}. We had 4 (10.5%) complications in open surgery treated patients which were not different from other comparing studies between these two operative types.^{41,42,46}

Conclusion

With correct staging a large number of patients with cervical cancer FIGO stages IA2 and IB can be spared of unnecessary abdominal radical surgery and treated with LAVRH because the survival rate, number and severity

of complications is almost the same. Our results and experiences from the sole Croatian center performing LAVRH or open surgery in patients with cervical cancer FIGO stage IA2 and IB were similar to those in centers across the world. Primary surgical treatment is a method of choice for tumors of the cervix < 4 cm.

REFERENCES

1. LEONARDO RA, Hystory of Gynecology, Frolen Press, New York, 1994. — 2. COPENHAVER EH, Surg Clin North Am, 60 (1980) 437. — 3. SAUTER JN, CONSTANTZ W, WALLIS (Eds.), Die gänzliche Exstirpation der carcinomatösen Gebärmutter, ohne selbst entstandenen oder künstlich bewirten Worfall vorgenommen und glücklich vorführt, mit näherer Anleitung, wie diese Operation gemacht werden kann (1822). — 4. POSOVER M, The Laparoscopic-Vaginal Therapy of the Cervical Cancer (Cologne, 2003.) — 5. STAUDE C, Zentralbl Gynacol, 37 (1908) 1201. — 6. RIES E Z, Geburth Gynäk, 32 (1895) 266. — 7. WERTHEIM E, GRAD H, American Journal of Obstetrics and Disease of Woman and Children, 66 (1912) 169. — 8. SCHAUTA F. J. SAFAR: Die erweiterten vaginale Totalexstirpation des Uterus bei Kollumkarzinom, Wien-Leipzig, 1908. — 9. AMREICH AI, Wien Klin Wochenschr, 56(9), (1943) 162. — 10. STOECKEL W, Zentralbl Gynacol, 1 (1931) 53. — 11. POSOVER M, KAMPFRATH S, SCHNAIDER A, Zentralbl Gynacol, 119 (1997) 353. — 12. PIVER MS, RUTLEDGE FN, SMITH PJ, Obstet Gynecol, 44 (1974) 265–270. — 13. DARGENT D, Laparoscopic vaginal radical hysterectomy. In: DARGENT D, QUERLEU D, PLANTE M, REYNOLDS K (Eds.), Vaginal and laparoscopic vaginal surgery, (Taylor & Francis, London, 2004). — 14. MITRA S, Am J Obstet Gynecol, 78 (1959) 191. — 15. NAVRATIL E, Gynecol Prat, 20 (1969) 7. — 16. INGUILLA W, COSMI EV, Am J Obstet Gynecol, 99 (1967) 1078. — 17. BARTEL M, Zentralbl Chir, 94 (1969) 377. — 18. WITTMOSER R, Fortch Endosc, 4 (1973) 219. — 19. DARGENT D, Eur J Gynecol Oncol, 8 (1987) 292. — 20. QUERLEU D, Laparoscopic pelvic lymphadenectomy. In: Proceedings (Second World Congress of Gynecologic Endoscopy, Clermont Ferrand, 1989). — 21. CANIS M, MAGE G, WATTIEZ A, POULY JL, MANHES H, BRUHAT MA, J Gynecol Obstet Biol Reprod, 19 (1990) 921. — 22. QUERLEU D, J Gynecol Obstet Biol Reprod, 20 (1991) 747–748. — 23. DARGENT D, MATHEVET P, J Gynecol Obstet Biol Reprod, 21 (1992) 709. — 24. CHILDERS JM, HATCH K, SURWIT EA, Gynecol Oncol, 47 (1992) 38. — 25. QUERLEU D, Gynecol Oncol, 49 (1993) 24. — 26. POSOVER M, KRAUSE N, KÜHNE-HEID R, SCHNEIDER A, Gynecol Oncol, 70 (1998) 94. — 27.

POSOVER M, KRAUSE N, PLAUL K, KÜHNE-HEID R, SCHNEIDER A, Gynecol Oncol, 81 (1998) 19. — 28. POSOVER M, KRAUSE N, SCHNEIDER A, Obstet Gynecol, 91 (1998) 139. — 29. POSOVER M, STÖBER S, PLAUL K, SCHNEIDER A, Gynecol Oncol, 79(2) (2000) 154. — 30. SCHNEIDER A, POSOVER M, KAMPFRATH S, ENDISCH U, KRAUSE N, NOSCHEL H, Obstet Gynecol, 88 (1996) 1057. — 31. INOUE T, Cancer, 54 (1984) 3035. — 32. DARGENT D, MATHEVET P, SCHAUTA, Baillieres Clin Obstet Gynecol, 9 (1995) 691. — 33. SCHLAERTH JB, SPIRTOS NM, SCHLAERTH AC, Am J Obstet Gynecol, 188 (2003) 29. — 34. ROY M, PLANTE M, Am J Obstet Gynecol, 179 (1998) 1491. — 35. BURNETT AF, ROMAN LD, O'MEARA AT, MORROW CP, Gynecol Oncol, 88 (2003) 419. — 36. DARGENT D, MARTIN X, SACCHETONI A, MATHEVET P, Cancer, 88 (2000) 1877. — 37. DARGENT D, Laparoscopic vaginal radical trachelectomy. In DARGENT D, QUERLEU D, PLANTE M, REYNOLDS K (Eds), Vaginal and laparoscopic vaginal surgery (Taylor & Francis, London, 2004) — 38. LANDONI F, MANEO A, COLOMBO A, PLACA F, MILANI R, PEREGO P, FAVINI G, FERRI L, MANGIONI C, Lancet, 350 (1997) 535. — 39. ĆORUŠIĆ A, BABIĆ D, ILIĆ-FORKO J, BARIŠIĆ D, Analysis of some prognostic parameters in patients with invasive cervical carcinoma in relation to the modality of treatment. In: PECORELLI S, ATLANTE G, BENEDETTI PANICI P, MANCUSO S. (Eds), 7th Biennial Meeting of the International Gynecologic Cancer Society (Monduzzi Editore S.p.A, Bologna, 1999). — 40. HERTEL H, KOHLER C, MICHELS W, POSOVER M, TOZZI R, SCHNEIDER A., Gynecol Oncol, 90 (2003) 505. — 41. , Gynecol Oncol, 93 (2004) 588. — 42. MALUR S, POSOVER M, SCHNEIDER A, Surg Endosc, 15 (2001) 289. — 43. SPIRTOS NM, EISENKOP SM, SCHLAERTH JB, BALLON SC, Am J Obstet Gynecol, 187 (2002) 340. — 44. SCHLAERTH JB, SPIRTOS NM, CARSON LF, BOIKE G, ADAMEC T, STONEBRAKER B, Gynecol Oncol, 85 (2002) 81. — 45. POMEL C, ATALLAH D, LE BOUEDEC G, ROUZIER R, MORICE P, CASTAIGNE D, DAUPLAT J, Gynecol Oncol, 91 (2003) 534. — 46. , Gynecol Oncol, 95 (2004) 655.

A. Plavec

Department of Gynecology and Obstetrics, Medical School University of Zagreb, Petrova 13, HR-10000 Zagreb, Croatia
e-mail: andrea.plavec@zg.htnet.hr

ULOGA LAPAROVAGINALNE KIRURGIJE U KIRURŠKOM LIJEČENJU RAKA VRATA MATERNICE

SAŽETAK

Korektnim određivanjem stadija bolesti prema FIGO klasifikaciji veliki broj bolesnica s rakom vrata maternice stadija IA2 i IB mogao bi se poštediti nepotrebnog radikalnog abdominalnog kirurškog liječenja gdje je i laparoskopski asistirana vaginalna radikalna histerektomija (LAVRH) moguća. Prikazani su povijesni pregled, indikacije i kontraindikacije za LAVRH. Kirurška tehnika LAVRH je detaljno opisana. 52 bolesnice su praćene tijekom 2003. godine nakon provedenog liječenja LAVRH-om ili abdominalnom radikalnom kirurškom operacijom izvedenom u našem centru. U razdoblju praćenja 5 (14%) bolesnica je umrlo od raka vrata maternice i sve su bile FIGO stadija IB, liječene abdominalnom radikalnom operacijom. Prikazane su 4 (10.5%) komplikacije, sve u bolesnica s FIGO stadijem IB liječenih abdominalnom radikalnom operacijom. U bolesnica liječenih LAVRH-om nisu zabilježene komplikacije. Preživljenje, kao i broj komplikacija nakon LAVRH ili radikalne abdominalne operacije, u našem centru u Hrvatskoj, ne razlikuju se u usporedbi s drugim svjetskim centrima.