

# Aortic valve replacement in a patient with severe hemophilia

---

Gašparović, Hrvoje; Zupančić-Salek, Silva; Brida, Vojtjeh; Dulić, Grgur; Jelić, Ivan

Source / Izvornik: **Collegium Antropologicum, 2007, 31, 355 - 357**

Journal article, Published version

Rad u časopisu, Objavljena verzija rada (izdavačev PDF)

Permanent link / Trajna poveznica: <https://um.nsk.hr/um:nbn:hr:105:525469>

Rights / Prava: [In copyright](#)/[Zaštićeno autorskim pravom.](#)

Download date / Datum preuzimanja: **2024-07-24**



Repository / Repozitorij:

[Dr Med - University of Zagreb School of Medicine  
Digital Repository](#)



# Aortic Valve Replacement in a Patient with Severe Hemophilia

Hrvoje Gašparović<sup>1</sup>, Silva Zupančić-Salek<sup>2</sup>, Vojtjeh Brida<sup>3</sup>, Grgur Dulić<sup>1</sup> and Ivan Jelić<sup>1</sup>

<sup>1</sup> Department of Cardiac Surgery, University Hospital »Rebro«, Zagreb, Croatia

<sup>2</sup> Department of Hematology, University Hospital »Rebro«, Zagreb, Croatia

<sup>3</sup> Department of Cardiology, University Hospital »Rebro«, Zagreb, Croatia

## ABSTRACT

*Hemophilia A is an inherited bleeding disorder characterized by factor VIII deficiency. The basis for insufficient hemostasis lies within inadequate amplification of factor Xa production with the undersupplied factor VIII. We report on a young patient with critical aortic stenosis bearing all the clinical stigmata of severe hemophilia, in whom aortic valve replacement was performed with a tissue valve in order to avoid the need for long term anticoagulation.*

**Key words:** valve prosthesis, cardiac surgery, hemophilia

## Introduction

The substantial improvements in the management of patients with hemophilia have resulted in significant prolongation of their life expectancy<sup>1</sup>. While the prevalence of cardiac pathology in patients with hemophilia may be lower than in the healthy population of similar demographic characteristics, it is likely to be influenced by the mentioned aging of the hemophiliac population<sup>1</sup>. This fact brings into focus the importance of recognizing the risks associated with performing major cardiac surgical procedures in patients with inherited bleeding disorders. The complex coagulation disturbance provoked by cardiopulmonary bypass further adds to the patient's already defective hemostatic potential<sup>2</sup>. Prothrombin complex concentrates, activated prothrombin concentrates as well as recombinant factor VIIa have all been used in the prevention and treatment of bleeding associated with major surgical procedures in hemophiliacs<sup>3</sup>.

## Case Report

We present a 47-year-old man with a severe form of hemophilia A without inhibitors, who was referred for surgical management of his symptomatic aortic stenosis. He had already undergone shoulder, hip and knee replacements due to joint complications of his underlying illness.

He had echocardiographic evidence of severe calcific aortic stenosis, with a mean gradient of 58 mmHg in the setting of preserved left ventricular function. He complained of angina and progressive dyspnea on exertion. He underwent coronary angiography which showed mild nonobstructive coronary artery disease. Of note, he was HIV antibody, hepatitis B surface antigen and hepatitis C antibody negative. While there is little doubt that a patient of the same age group with a competent coagulation mechanism could have been offered a mechanical valve prosthesis, the choice in our patient was less simple. Following a detailed discussion with the patient which encompassed all the limitations of the various options for aortic valve replacement (AVR), we opted to use a third generation tissue prosthesis for his scheduled AVR. The patient's preoperative factor VIII level was 0.005 IU/dL. He received a 2500 U bolus (B1) of factor VIII the night before surgery. A repeat 4500 U dose (B2) was given 1 hour prior to the skin incision followed by a continuous infusion of 270 IU/hr, which enhanced the factor VIII activity to 107% (Figure 1). The operative strategy also included administration of the antifibrinolytic aprotinin and use of a cell-saver device, while exceptional emphasis on a meticulous surgical technique was insisted upon. The patient was anticoagulated for cardiopulmonary bypass (CPB) with a 3 mg/kg bolus dose of systemic heparin

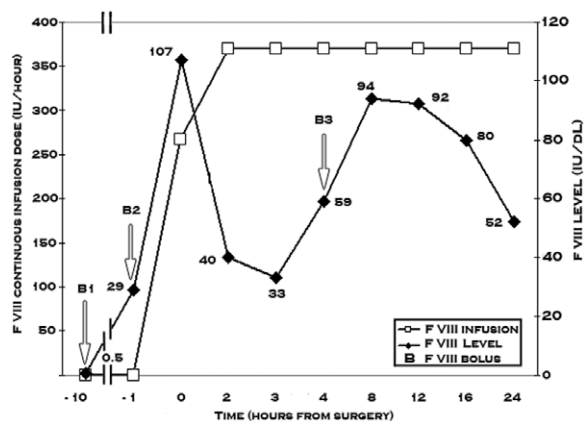


Fig. 1. Correlation of the factor VIII level with the continuous factor VIII infusion complemented with intermittent boluses (B1–3) in the immediate perioperative period.

to achieve an activated clotting time in excess of 480 seconds. Prior to institution of CPB another 5000 U bolus dose (B3) of the antihemophilic factor was given, while the continuous infusion was increased to 370 IU/hr<sup>4</sup>. The operation was performed in the standard fashion which included a median sternotomy approach and use of normothermic cardiopulmonary bypass. Following aortic cross clamping an oblique aortotomy was made and cold blood cardioplegia delivered directly into the coronary ostia. On inspection, the aortic valve was found to be tricuspid with extensive leaflet calcifications extending into the valve annulus. Following the excision of all disease leaflets, a thorough debridement and decalcification ensued. The aortic valve annulus was then calibrated and a 27 mm Medtronic Mosaic tissue valve (Medtronic, Minneapolis, USA) was inserted. The patient was weaned off cardiopulmonary bypass without inotropic support, and the competence of the prosthesis was demonstrated by transesophageal echocardiography. The factor VIII activity was boosted again at the conclusion of the operation, in synchrony to heparin's reversal with protamine.

The patient had an uneventful postoperative course. While the combination of the coagulation defect triggered by cardiopulmonary bypass in addition to the factor VIII deficiency made the prospect of increased perioperative blood loss a likely possibility, the chest tube output for the first 24 hours remained below 350 mL. The micromanagement of the continuous factor VIII infusion was done in collaboration with a hematologist and was continued until postoperative day twelve, when it was substituted for intermittent bolus dosing with the goal of maintaining the factor VIII activity above 40%.

## Discussion

The life expectancy of patients with hemophilia is currently estimated to be between 60 and 70 years. It is,

therefore, foreseeable that the problem of approaching a patient with hemophilia requiring a valve replacement might begin to occur with greater frequency. The incompetent hemostatic mechanism in hemophiliacs may confer a protective effect in terms of retarding the process of thrombosis superimposed upon atherosclerotic lesions, but no apparent link to aortic valve disease has thus far been identified. The paucity of published data falls short in providing unequivocal guidelines for the choice of a valve prosthesis in this specific clinical scenario<sup>1,5</sup>. Taking into consideration that our patient's inherited bleeding disorder had already burdened him with serious bleeding-related complications, we were more inclined to use a biological prosthesis in order to avoid the need for long term warfarin.

The complex coagulation disorder known to be precipitated by cardiopulmonary bypass coupled with the underlying factor VIII deficiency warranted a judicious multidisciplinary approach. Our intraoperative anticoagulation strategy did not differ from our routine management, and included heparin and its reversal with protamine. Whether administration of factor VIII during cardiopulmonary bypass is necessary or not in order to neutralize the hemodilutive effect of CPB remains a point of controversy. Our tactic was to continue factor VIII continuously and supplement it with intermittent boluses prior to the commencement of CPB and immediately upon its discontinuation. The continuous infusion of factor VIII was maintained until postoperative day twelve, which coincided with the removal of the last of the patient's stitches. The available data in the literature discourages the use of aspirin in the hemophiliac population, and neither aspirin nor warfarin was given to our patient at any time<sup>1</sup>.

The decision to operate on the presented patient was not made hastily. One should be reluctant to operate on a patient with asymptomatic aortic stenosis and a severe comorbidity based on echocardiographic appearance alone. However, our patient presented with both echocardiographic and clinical evidence of severe aortic stenosis. It was his worsening clinical condition that prompted us to proceed with surgery. We believed that the natural progression of his cardiac pathology outweighed the substantial risk of surgery.

The optimal choice of a valve prosthesis is undoubtedly of paramount importance, and we believe that a patient specific approach is warranted. Avoiding the perils of lifelong anticoagulation with warfarin in a patient with severe hemophilia comes at a cost of reduced prosthetic valve durability. With reoperative procedures becoming more prevalent in the contemporary cardiac surgical practice, however, we believe that future re-do valve replacement can be offered with low mortality.

## REFERENCES

1. MACKINLAY N, TAPER J, RENISSON F, RICKARD K, Hemophilia, 6 (2000) 84. — 2. PAPARELLA D, BRISTER SJ, BUCHANAN MR, Intensive Care Med, 30 (2004) 1873. — 3. SHETH S, DIMICHELE D, LEE M, LAMOUR J, QUAEGEBEUR J, HSU D, ADDONIZIO L, PIOMELLI S, Hemophilia, 7 (2001) 227. — 4. MARTINOWITZ U, SCHULMAN S, GITEL S, HOROZOWSKI H, HEIM M, VARON D, Br J Haematol, 82 (1992) 729. — 5. GHOSH K, SHETTY S, Hemophilia, 10 (2004) 743.

*H. Gašparović*

*Department of Cardiac Surgery, University Hospital Rebro Zagreb, Kišpatičeva 12, 10000 Zagreb, Croatia  
e-mail: hgasparovic@kbc-zagreb.hr*

## ZAMJENA AORTALNE VALVULE KOD BOLESNIKA SA TEŠKOM HEMOFILIJOM

### SAŽETAK

Hemofilija A je nasljedni poremećaj koagulacije koji je karakteriziran nedostatkom faktora VIII. U podlozi manjkavog hemostatskog potencijala je neadekvatna amplifikacija faktora Xa sa faktorom VIII. Ovaj prikaz slučaja fokusira se na mladog bolesnika sa kritičnom stenozom aortalne valvule koji boluje od teškog oblika hemofilije A. Strategija kirurškog liječenja bazirala se na zamjeni aortalne valvule sa tkivnom protezom kako bi se izbjegla dugoročna antikoagulacija