

Duplex sonography of arteriovenous fistula in chronic hemodialysis patients

Mišević, Tonči; Brkljačić, Boris; Zibar, Lada; Jakić, Marko; Kurbel, Sven; Radić, Radivoje; Mišević, Sanja

Source / Izvornik: **Collegium Antropologicum, 2006, 30, 535 - 541**

Journal article, Published version

Rad u časopisu, Objavljena verzija rada (izdavačev PDF)

Permanent link / Trajna poveznica: <https://um.nsk.hr/um:nbn:hr:105:092764>

Rights / Prava: [In copyright](#)/[Zaštićeno autorskim pravom.](#)

Download date / Datum preuzimanja: **2024-11-23**



Repository / Repozitorij:

[Dr Med - University of Zagreb School of Medicine Digital Repository](#)



Duplex Sonography of Arteriovenous Fistula in Chronic Hemodialysis Patients

Tonči Mišević¹, Boris Brkljačić², Lada Zibar³, Marko Jakić³, Sven Kurbel⁴,
Radivoje Radić⁴ and Sanja Mišević⁵

¹ Department of Radiology, University Hospital »Osijek«, Osijek, Croatia

² Department of Diagnostic and Interventional Radiology, University Hospital »Dubrava«, Zagreb, Croatia

³ Department of Dialysis, University Hospital »Osijek«, Osijek, Croatia

⁴ School of Medicine, University »J. J. Strossmayer«, Osijek, Croatia

⁵ Department of Neurology, University Hospital »Osijek«, Osijek, Croatia

ABSTRACT

Duplex sonography was used to assess functional features of arteriovenous fistula (AVF) for hemodialysis (HD). Internal diameter (ID), resistance index (RI) and blood flow (BF) velocity in feeding artery and in vein of AVF, and venous BF volume were analyzed with purpose to determine the normal values. Presumed normal BF velocities are those of clinically well functioning shunts, allowing BF through HD lines of minimally 250 ml/min. Study included 66 nondiabetic HD patients (30 women, 36 men), mean age 52 ± 13 years, treated by HD for median 61 (4–252) months. Measurements in 47 patients with clinically well functioning AVF were as followed: mean arterial ID 5.2 ± 1.4 mm, median arterial RI 0.3 (0.3–0.9), median arterial BF velocity 1.5 (0.6–3.6) m/s, mean venous ID 7.6 ± 2.2 mm, median venous RI 0.3 (0.3–0.9), mean venous BF velocity 1.6 ± 0.7 m/s, and median venous BF volume 530 (120–1890) ml/min. Patients with poor functioning AVF had significantly less arterial ID, higher arterial RI, less venous ID, less venous BF velocity and volume. Duplex sonography findings obtained for clinically estimated well functioning shunt should be considered as normal Doppler values. Blood vessels' morphologic features depend upon age, and older patients have more pronounced changes.

Key words: arteriovenous fistula, duplex sonography, blood flow, hemodialysis

Introduction

Patients in need for chronic hemodialysis (HD) mostly undergo arteriovenous fistula (AVF) surgical creation. Native AVF is the most frequent form of vascular access for HD, and to date the optimal one. The communication is commonly established in forearm between radial artery and cephalic vein, usually on left (nondominant) arm¹. Anastomosis can be terminoterminal (T-T) (the end of radial artery is connected with the end of cephalic vein), terminolateral (T-L) (end vein-to-side artery) and laterolateral (L-L) anastomosis. Communication between artery and vein can also be established by using artificial materials (polytetrafluoroethylene) and native grafts (Figure 1)^{2–4}.

Spectral analysis by duplex sonography technique shows that there are regular triphasic spectra in intact arteries in forearm. Hemodynamic changes occur following shunt creation between artery and vein, rendering

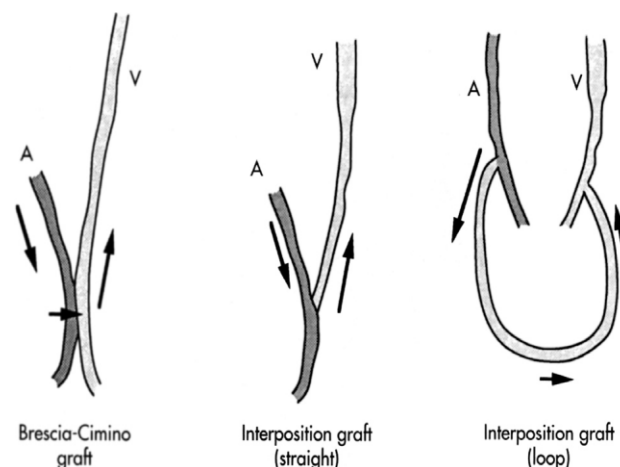


Fig. 1. Artificial communications between artery and vein.

normal arterial triphasic spectra of high resistance to be replaced by low-resistant biphasic spectra (Figure 2 and 3)⁵⁻⁸.

Complications associated with AVF include development of small and large aneurysms, pseudoaneurysms, stenoses, and total occlusion (thrombosis) of lumen at arterial or venous segment or of the shunt. The changes are more frequent in the venous segment; namely, more than 80% of all stenoses occur in the venous segment. Hemodialysis procedure requires certain flow volume in HD system. Minimum flow volume required is about 250 ml/min. Flow volume in AVF can be measured by various methods, such as duplex sonography, ultrasound dilution and magnetic resonance (MR). Analyzed values show

great variability in flow volumes in the range of minimum 450 ± 214 ml/min to $2,131 \pm 565$ ml/min according to various authors¹³⁻¹⁶.

Duplex sonography still does not provide firm quantitative finding that could discriminate between well and poor function of the shunt. The aim of the study was to show the usefulness of the Doppler technique in imaging stenosis or imminent thrombosis, once clinical dysfunction occurs. The study should give the rationale for standardizing the procedure.

Materials and Methods

The study design was cross sectional. The research included 66 nondiabetic HD patients (37 men and 29 women), mean age 52 ± 13 years, treated by HD for median time of 61 (4-252) months, with mean serum hemoglobin concentration 92 ± 16 g/l. The patients gave informed consent for the participation in the study.

The patients underwent AVF examination by CD ultrasound prior to middle-week HD session. A greater proportion of patients had lateroterminal and the rest of the patients had terminoterminal AVF, but there was no reliable documentation regarding this issue. Examination was performed using Siemens Versa plus device with the probe at frequency of 7.5 MHz. The point of ultrasonographic measurements in feeding artery was the one immediately preceding the communication, and the point with less turbulence in the venous part proximal to the anastomosis. Artery was examined by producing images in B mode. Internal diameter (ID), resistance index (RI), and blood flow (BF) velocity in the artery and the vein, and venous BF volume were measured. Resistance index is calculated by formula $RI = (A-B)/A$, where A is the highest BF velocity during systole and B is the lowest diastolic BF velocity. Aneurysmatic changes and calcifications were recorded.

The sonographic data were analyzed in relation with achieved BF volume in HD lines, history of AVF thrombosis, erythropoietin treatment, smoking habits, findings of aneurysmatic changes and calcifications, age, HD duration and hemoglobin concentration. They were divided in the two subgroups: 49 patients with BF volume of at least 250 ml/min during HD in dialysis lines and 17 patients with less than that. The BF volume of at least 250 ml/min allowed optimal HD without clotting in lines under standard heparinization (from 3,500 to 5,500 UI per session). History of AVF thrombosis was taken from the patients' medical records. The AVF thrombosis was considered the accident that occurred after the AVF was used for HD. There were 32 patients without history of AVF thrombosis, 19 patients with 1, 8 patients with 2 and 7 patients with 3 thrombotic accidents of AVF. Twenty two patients received human recombinant erythropoietin treatment (from 2,000 to 8,000 UI weekly). Smoking habit was found in 17 patients.

Data were entered onto a personal computer. Statistical tests were performed using SPSS for Windows. Normal distribution was considered when skewness was less

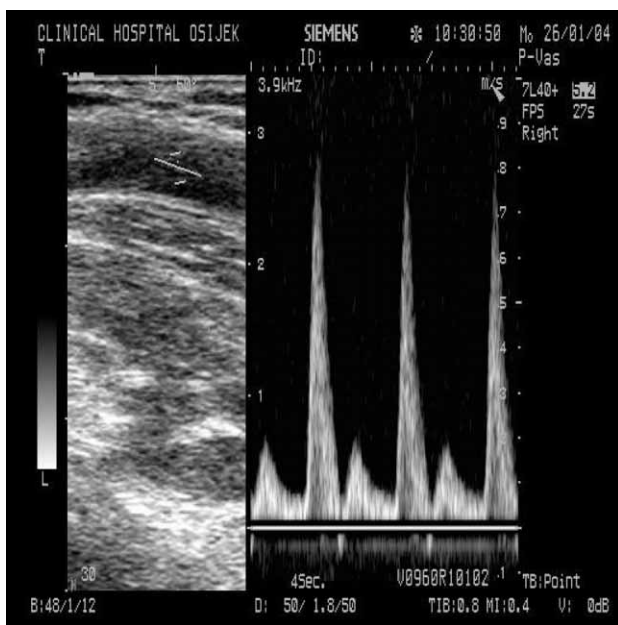


Fig. 2. Example of normal triphasic spectrum in arm or leg artery.

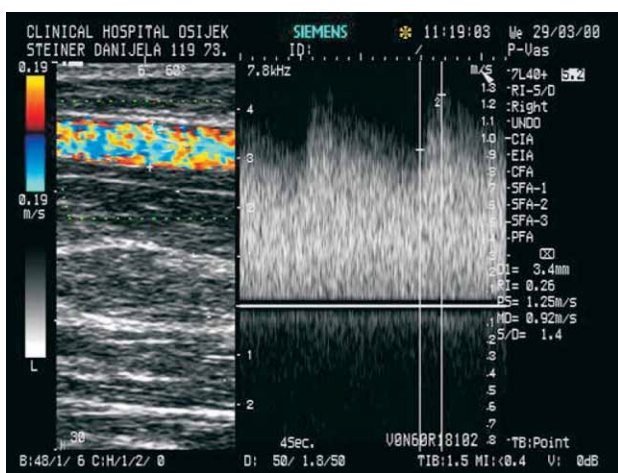


Fig. 3. Typical biphasic spectrum in arteriovenous fistula.

than 1. Normally distributed variables were expressed as means \pm SD, and the others as median (range). For determination of difference between two independent samples Student's t-test was used as a parametric method, and Mann-Whitney U-test as nonparametric method. Parametric ANOVA and post hoc Scheffe's test and nonparametric Kruskal-Wallis H test accompanied by Mann-Whitney post hoc test were used for differences estimation between more than two independent variables. Pearson's r was calculated for determination of correlation between normally distributed variables, and nonparametric correlation was measured with the Kendall's tau-b coefficient. Chi-square test and Odds ratio were used for analysis of nominal variables. Results were considered significant at $p < 0.05$.

Results

Values of sonographic measurements in all patients are presented in the table 1.

Arterial ID was significantly greater in the subgroup of patients with clinically well functioning AVF, their arterial RI was less, and venous ID, BF velocity and volume significantly greater (Table 2). Those subgroups did not differ in age neither in hemoglobin concentration.

According to the history of AVF thrombosis, the patients were divided in the 4 subgroups: without thrombosis ($n=32$), with 1 ($n=19$), with 2 ($n=8$), and with 3 thrombotic accidents ($n=7$). Differences in rheologic parameters were examined using ANOVA test (for arterial ID, venous ID and venous BF velocity) and Kruskal-Wallis H test (for arterial RI, arterial BF velocity, venous RI, and venous BF volume). The subgroups differed significantly in arterial ID ($F=3.443$, $p=0.022$) and venous BF volume (Chi-square=10.350, $p=0.016$), and not in other examined parameters. Post hoc Scheffe's test revealed that the difference in arterial ID was between the subgroup without and those with 1 thrombosis (Mean Difference=-1.143, $p=0.024$), and the same pair of subgroups was the one with significant difference in venous BF volume, as was found using post hoc Mann-Whitney

test ($z=-3.186$, $p=0.001$). The subgroups based on the history of AVF thrombosis also differed significantly in age (ANOVA test, $F=6.979$, $p < 0.001$) and in HD duration (Kruskal-Wallis H test, Chi-square=23.486, $p < 0.001$). Post hoc Scheffe's test found the difference in age between subgroups with 1 and 2 thrombosis (Mean Difference=-17.38, $p=0.009$) and subgroups with 1 and 3 thrombosis (Mean Difference=-18.86, $p=0.006$). The difference in HD duration (post hoc Mann-Whitney test) was found between the subgroup without AVF thrombosis and with 1 AVF thrombosis ($z=-3.362$, $p=0.001$), with 2 ($z=-3.756$, $p < 0.001$) and with 3 thrombotic accidents ($z=-2.820$, $p=0.005$). The subgroups did not differ in hemoglobin concentration.

Regarding the human recombinant erythropoietin substitution, 22 patients who underwent the treatment differed from those 44 untreated in arterial ID, RI, venous ID, RI and venous BF volume (Table 3). At the same time, they differed significantly in age ($t=2.463$, $p=0.012$), but neither in HD duration nor in hemoglobin concentration.

Subgroups with ($n=17$) and without ($n=49$) smoking habit differed significantly in arterial ID ($t=2.157$, $p=0.035$), and not in arterial RI, BF velocity, venous ID, RI, BF velocity and volume. The smokers were significantly younger ($t=-2.212$, $p=0.031$). The differences in HD duration and hemoglobin concentration between the subgroups were not significant.

TABLE 1
DOPLEX ULTRASONOGRAPHIC FINDINGS OF ARTERIOVENOUS FISTULA IN 66 CHRONIC HEMODIALYSIS PATIENTS

Parameter	Feeding artery*	Vein†
Internal diameter (mm)	5.0 \pm 1.3	7.1 \pm 2.1
Blood velocity (m/s)	1.5 (0.5–3.6)	1.6 \pm 0.7
Resistance index	0.4 (0.3–0.9)	0.4 (0.3–0.9)
Blood flow volume (ml/min)		500 (120–1,890)

* measured at the point proximal to the anastomosis

† measured at the point of minimal turbulence close to anastomosis

TABLE 2
COMPARISON OF DOPLEX ULTRASONOGRAPHIC FINDINGS OF ARTERIOVENOUS FISTULA BETWEEN TWO SUBGROUPS OF HEMODIALYSIS PATIENTS DIVIDED ACCORDING TO THE ACHIEVED BLOOD FLOW THROUGH HEMODIALYSIS LINES (N=66)

Parameter	Patients with sufficient blood flow* (n=47)	Patients with insufficient blood flow† (n=19)	Test value	p
Arterial internal diameter (mm)	5.2 \pm 1.4	4.4 \pm 0.8	$t=2.436$	0.018
Arterial blood velocity (m/s)	1.5 (0.6–3.6)	1.4 (0.5–2.2)	$z=-1.655$	0.098
Arterial resistance index	0.3 (0.3–0.9)	0.4 (0.3–0.9)	$z=-2.400$	0.016
Venous internal diameter (mm)	7.6 \pm 2.2	6.0 \pm 1.2	$t=3.617$	0.001
Venous blood velocity (m/s)	1.7 \pm 0.7	1.3 \pm 0.7	$t=2.100$	0.040
Venous resistance index	0.3 (0.3–0.9)	0.4 (0.3–0.9)	$z=-1.230$	0.219
Venous blood flow volume (ml/min)	530 (120–1,890)	320 (140–950)	$z=-2.897$	0.004

*blood flow through hemodialysis lines \geq 250 ml/min

†blood flow through hemodialysis lines $<$ 250 ml/min

TABLE 3
COMPARISON OF DOPLEX ULTRASONOGRAPHIC FINDINGS OF ARTERIOVENOUS FISTULA BETWEEN TWO SUBGROUPS OF HEMODIALYSIS PATIENTS DIVIDED ACCORDING TO HUMAN RECOMBINANT ERYTHROPOIETIN TREATMENT (N=66)

Parameter	Patients treated with erythropoietin (n=22)	Patients not treated with erythropoietin (n=44)	Test value	p
Arterial internal diameter (mm)	5.7±1.3	4.7±1.2	t=3.122	0.003
Arterial blood velocity (m/s)	1.5 (0.7–3.5)	1.5 (0.5–3.6)	z=-0.198	0.843
Arterial resistance index	0.3 (0.3–0.9)	0.4 (0.3–0.9)	z=-1.521	0.128
Venous internal diameter (mm)	8.1±2.0	6.6±2.0	t=2.861	0.006
Venous blood velocity (m/s)	1.7±0.8	1.6±0.7	t=0.874	0.385
Venous resistance index	0.3 (0.3–0.9)	0.4 (0.3–0.9)	z=-2.068	0.039
Venous blood flow volume (ml/min)	735 (210–1,760)	400 (120–1,890)	z=-2.823	0.005

TABLE 4
COMPARISON OF DOPLEX ULTRASONOGRAPHIC FINDINGS OF ARTERIOVENOUS FISTULA BETWEEN TWO SUBGROUPS OF HEMODIALYSIS PATIENTS DIVIDED ACCORDING TO PRESENCE OF CALCIFICATIONS (N=66)

Parameter	Patients with calcifications (n=12)	Patients without calcifications (n=54)	Test value	p
Arterial internal diameter (mm)	6.0±1.4	4.8±1.2	t=3.067	0.003
Arterial blood velocity (m/s)	1.6 (0.7–3.5)	1.5 (0.5–3.6)	z=-0.584	0.560
Arterial resistance index	0.4 (0.3–0.9)	0.4 (0.3–0.9)	z=-0.042	0.967
Venous internal diameter (mm)	8.3±2.2	6.9±2.0	t=2.161	0.034
Venous blood velocity (m/s)	1.7±0.8	1.6±0.7	t=0.732	0.467
Venous resistance index	0.3 (0.3–0.9)	0.4 (0.3–0.9)	z=-0.476	0.634

Aneurysmatic changes in AVF were found in 12 patients. They did not differ from those free of the finding (n=54) in arterial ID, RI, BF velocity, venous ID, RI and BF velocity, while the difference in venous BF volume was significantly different (z=-2.478, p=0–013, Mann-Whitney test). The two subgroups did not differ in age, HD duration and serum hemoglobin concentration.

Calcifications were found in AVF of 12 patients. They significantly differed from the 54 patients without the finding in arterial ID, venous ID and venous BFV (Table 4). The two subgroups were similar in age and serum hemoglobin concentration. The patients with calcifications were treated by HD for median 85 (42–169) months, while the subgroup without calcifications spent 55 (4–252) months under the treatment (z=-2.083, p=0.037, Mann-Whitney test).

Age was found to be significantly related to the most examined ultrasonographic features. Age was in negative correlation with arterial ID, venous ID and venous BFV, and in positive correlation with venous RI (Table 5). Age was not related to HD duration. Age and serum hemoglobin concentration were in significant negative correlation (r=-0.244, p=0.048).

Table 6 presents bivariate correlations between the examined sonographic parameters. All except three pairs of variables (arterial ID and arterial BV, arterial BV and venous ID and arterial BV and venous RI) were significantly correlated.

TABLE 5
CORRELATION BETWEEN DOPLEX ULTRASONOGRAPHIC FINDINGS OF ARTERIOVENOUS FISTULA AND AGE IN 66 HEMODIALYSIS PATIENTS

Parameter in correlation with age	Correlation coefficient*	p
Arterial internal diameter	r=-0.351	0.004
Arterial blood velocity	τ=0.045	0.605
Arterial resistance index	τ=0.138	0.117
Venous internal diameter	r=-0.327	0.007
Venous blood velocity	r=-0.163	0.191
Venous resistance index	τ=0.271	0.002
Venous blood flow volume	τ=-0.184	0.033

*r – Pearson correlation coefficient, τ – Kendall's Tau-b

Chi-square and Odds ratio were calculated to assess if smoking, aneurysmatic changes, calcifications and insufficient BF through HD lines each increases the risk for the other one. Smokers were not at increased risk for calcifications, aneurysmatic changes and insufficient BF through HD lines. Patients with calcifications were not at increased risk for aneurysmatic changes and for insufficient BF through HD lines. Patients with insufficient BF through HD lines were not at increased risk for aneurysmatic changes and calcifications.

TABLE 6
BIVARIATE CORRELATION BETWEEN DOPLEX ULTRASONOGRAPHIC FINDINGS
OF ARTERIOVENOUS FISTULA IN 66 HEMODIALYSIS PATIENTS

Parameters in correlation	Correlation coefficient ^a	p
Arterial internal diameter and arterial blood velocity	$\tau = -0.070$	0.939
Arterial internal diameter and arterial resistance index	$\tau = -0.213$	0.026
Arterial internal diameter and venous internal diameter	$r = 0.740$	<0.001
Arterial internal diameter and venous blood velocity	$r = -0.347$	0.004
Arterial internal diameter and venous resistance index	$\tau = 0.420$	<0.001
Arterial internal diameter and venous blood flow volume	$\tau = 0.662$	<0.001
Arterial blood velocity and arterial resistance index	$\tau = -0.204$	0.021
Arterial blood velocity and venous internal diameter	$\tau = 0.102$	0.265
Arterial blood velocity and venous blood velocity	$\tau = 0.272$	0.002
Arterial blood velocity and venous resistance index	$\tau = 0.126$	0.155
Arterial blood velocity and venous blood flow volume	$\tau = 0.289$	0.001
Arterial resistance index and venous internal diameter	$\tau = 0.251$	0.006
Arterial resistance index and venous blood velocity	$\tau = 0.313$	<0.001
Arterial resistance index and venous resistance index	$\tau = 0.535$	<0.001
Arterial resistance index and venous blood flow volume	$\tau = 0.172$	0.047
Venous internal diameter and venous blood velocity	$r = 0.338$	0.006
Venous internal diameter and venous resistance index	$\tau = 0.304$	0.001
Venous internal diameter and venous blood flow volume	$\tau = 0.498$	<0.001
Venous blood velocity and venous resistance index	$\tau = 0.351$	<0.001
Venous blood velocity and venous blood flow volume	$\tau = 0.222$	0.011
Venous blood velocity and venous blood flow volume	$\tau = 0.338$	<0.001

^ar – Pearson correlation coefficient, τ – Kendall's Tau-b

Discussion

The sonographic findings obtained for the patients with achieved sufficient blood flow through HD system differed significantly from those measured in AVF of patients with suboptimal blood flow during HD. These results indicate that limits of normal standard values range at the level of the findings obtained for the well functioning AVF. Our findings were close to those found by Malovrh in AVF measured 12 weeks after surgical creation and irrespective of function in the terms of our criteria²¹.

Certain examined sonographic features of AVF differed significantly between the groups of patients divided according to the history of AVF thrombosis. The found differences referred to the feeding artery internal diameter and blood flow volume through the venous limb of AVF, between the group without history of AVF thrombosis and the group with a single accident. Presumably, patients with thrombosis might be older and such differences could be ascribable to the age, but the groups did not differ in age, so the other reasons should be considered. They could be a consequence of an already impaired circulation, while the second AVF were mostly created at the same forearm as the first, now clotted shunt.

Those patients with repeated AVF thrombosis mostly have currently functioning fistula at the forearm other than the one with clotted shunts. That fact explains the absence of sonographic difference between the group without AVF thrombosis and the group with history of repeated thrombosis.

Subgroups of patients according to the erythropoietin treatment did not differ in the observed sonographic parameters. They also did not differ in hemoglobin values, i.e., the treated group had well corrected anemia due to the treatment itself, while the untreated group, in fact, had no reason to be treated regarding a good hemoglobin level. Consequently, the two subgroups did not differ in blood viscosity that could alter AVF blood flow velocity. There was a significant difference in internal arterial diameter between those subgroups that could be explained by a significant difference in age. Smokers were found larger arterial diameter than nonsmokers, but the smokers were significantly younger than nonsmokers.

Patients with aneurysmatic changes of AVF did not have significant differences in diameters, RI nor blood flow velocity through AVF at the points outside the aneurysmatic area, as it was expected. Calcifications were found irrespective of patient's age, but occurred more often in those treated with HD for a longer time. Patients with calcifications had larger AVF vessels' di-

ameters as well as greater blood flow volumes through AVF. Therefore, the examined rheologic features do not reflect vessel wall consistence and normal values of the measured parameters do not exclude serious pathology of vessel wall. Thorough examination of AVF quality should include sonographic vessel wall assessment and native x-ray examination of the extremity.

Correlations between age and the examined sonographic features of AVF confirmed the already alleged association of age at one side and vessel diameter and blood flow at the other side. Therefore, older patients are expected to have *a priori* less functional AVF due to narrower vessel diameters and higher RI. An enlarged flow volume from artery into the vein through the shunt produces high pressure onto venous wall. However, older people are not expected to stretch and dilate veins sufficiently under that pressure. These sonographic and statistic results quantitatively confirm clinically well known difficulties with vascular approach for HD in older patients.

It would be useful to perform duplex sonography examination before surgery of AVF construction, and to predict success or failure based on the sonographic finding. Such assessment would be really relevant if standard val-

ues of the examined parameters could be determined. Malovrh et al. found predictive role of preoperative CD features of artery and vein of future AVF for time needed for AVF to dilate enough to achieve sufficient blood flow. Significant correlations between venous blood flow volume and all the other examined sonographic parameters indicate that final AVF function depends on the arterial and the venous features, and also both the diameters and RI in their walls. Beside the need to establish referent values of the examined sonographic parameters, the examination technique should be also standardized, especially the points of measurements of the arterial and the venous part of AVF. Small mistakes in luminal measurement result in great misestimating of blood flow volume in AVF.

Conclusion

Doplex sonography should be used as a useful tool for the evaluation of arteriovenous fistula function in hemodialysis patients. However, normal values of sonographic parameters remain to be standardized. Sonographic features obtained for well functioning AVF could be used by creating standards for the method.

REFERENCES

1. TORDOIR, J. H., H. G. DE BRUIN, H. HOENEVELD, J. Vasc. Surg., 10 (1989) 122. — 2. SCHEIBLE, W., C. SKRAM, G. R. LEOPOLD, Am. J. Roentgenol., 134 (1980) 1173. — 3. MIDDLETON, W. D., D. D. PICUS, M. V. MARKS, Am. J. Roentgenol., 152 (1989) 633. — 4. KOKSOY, C., A. KUZU, I. ERDEN, Br. J. Surg., 82 (1995) 50. — 5. DOUSSET, V., N. GRENIER, C. DOUWS, Radiology, 181 (1991) 89. — 6. VILLEMARETTE, P., J. HOWER, J. Vasc. Tech., 16 (1992) 183. — 7. KANTERMAN, R. Y., T. M. VESELY, T. K. PILGRAM, Radiology, 195 (1995) 135. — 8. SCHWAB, S. J., L. D. QUARLES, J. P. MIDDLETON, Kidney Int., 33 (1988) 1156. — 9. OUDENHOVEN, L. F., P. M. PATTYNAMA, A. DE ROOS, H. J. SEEVERENS, S. A. REBERGEN, P. C. CHANG, Kidney Int., 45 (1994) 884. — 10. STANDAGE, B. A., E. S. SCHUMA, S. F. QUINN, J. W. RAGSDALE, R. C. SHELEY, Ann. Vasc. Surg., 12 (1998) 364. — 11. KRPAN, D., V. DEMARIN, F. PROT, S. MILUTINOVIĆ, V. MOLNAR, E. MILUTINOVIĆ, Int. J. Artif. Organs, 12 (1991) 78. — 12. MAHMUTYAZICIOGLU, K., M. KESENCI, S. FITOZ, S. BUYUKBERBER, O. SENCAN, I. ERDEN, J. Ultrasound. Med., 16 (1997) 813. — 13. FRANCO, G., J. Mal. Vasc., 28 (2003) 194. — 14. FRANCO, G., J. Mal. Vasc., 28 (2003) 200. — 15. SCHWARZ, C., C. MITTERBAUER, M. BOCZULA, T. MACA, M. FUNOVICS, G. HEINZE, M. LORENZ, J. KOVARIK, R. OBERBAUER, Am. J. Kidney Dis., 42 (2003) 539. — 16. BRANDENBURG, V. M., R. D. FRANK, J. RIEHL, Clin. Nephrol., 58 (2002) 398. — 17. PERINGS, S. M., M. KELM, T. LAUER, B. E. STRAUER, Z. Kardiol., 91 (2002) 481. — 18. BAY, W. H., M. L. HENRY, J. M. LAZARUS, N. L. LEW, J. LING, E. G. LOWRIE, Am. J. Nephrol., 18 (1998) 296. — 19. WONG, V. R., R. WARD, J. TAYLOR, S. SELVAKUMAR, T. V. HOW, A. BAKRAN, Eur. J. Vasc. Endovasc. Surg., 12 (1996) 207. — 20. TESSITORER, N., V. BEDOGNA, L. GAMMARO, G. LIPARI, A. POLI, E. BAGGIO, M. FIRPO, G. MORANA, G. MANSUETO, G. MASCHIO, Am. J. Kidney Dis., 42 (2003) 331. — 21. MALOVRH, M., Am. J. Kidney Dis., 38 (2003) 1218.

T. Mišević

Department of Radiology, University Hospital »Osijek«, J. Huttlera 4, 31000 Osijek, Croatia
e-mail: misevic.tonci@kbo.hr

DUPLEKS DOPLER ULTRAZVUK ARTERIJSKOVENSKIH FISTULA U BOLESNIKA NA HEMODIJALIZI

SAŽETAK

Funkcijske osobine arterijskovenskih fistula (AVF) za hemodijalizu ispitivane su obojenim dupleks dopler ultrazvukom s ciljem utvrđivanja normalnih doplerskih vrijednosti. Određivani su unutarnji promjer, indeks otpora i brzina krvnog protoka u arteriji i veni AVF, te volumen protoka krvi kroz njezin venski dio. Normalnim vrijednostima smatraju se one koje su dobivene kod bolesnika koji ostvaruju protok krvi kroz sustav za HD od najmanje 250 mL/min. U

studiji je ispitano 66 bolesnika (30 žena i 36 muškaraca) liječenih hemodijalizom (medijan duljine liječenja 61 mjesec, od 4 do 25) koji nemaju šećernu bolest, prosječne dobi 52 ± 13 godina. U 47 bolesnika s dobrom funkcijom AVF nađen je prosječan arterijski unutarnji promjer ID 5.2 ± 1.4 mm, medijan arterijskog indeksa otpora 0.3 (0.3–0.9), medijan brzine krvnog protoka kroz arteriju 1.5 (0.6–3.6) m/s, prosječni venski unutarnji promjer 7.6 ± 2.2 mm, medijan venskog indeksa otpora 0.3 (0.3–0.9), prosječna brzina krvnog protoka kroz venu 1.6 ± 0.7 m/s, i medijan volumena krvnog protoka kroz venski dio AVF 530 (120–1890) ml/min. Bolesnici s nezadovoljavajućom funkcijom AVF imali su značajno manji unutarnji arterijski promjer, veći arterijski indeks otpora, manji venski unutarnji promjer te manju brzinu i volumen krvnog protoka kroz venski dio AVF. Vrijednosti nalaza dobivenih obojenim dopler ultrazvukom za bolesnike s klinički procijenjenom dobrom funkcijom AVF može se smatrati približnom razinom prema kojoj će se odrediti normalne vrijednosti. Osobitosti krvnih žila bile su značajno ovisne o dobi, boljih vrijednosti u mlađih bolesnika.