

Paget's disease in contralateral breast occurring 11 years after mastectomy for invasive ductal carcinoma

Salopek, Daniela; Murgić, Jure; Tomas, Davor; Bolanča, Ante; Kusić, Zvonko

Source / Izvornik: **Collegium Antropologicum, 2009, 33, 327 - 329**

Journal article, Published version

Rad u časopisu, Objavljena verzija rada (izdavačev PDF)

Permanent link / Trajna poveznica: <https://um.nsk.hr/um:nbn:hr:105:264578>

Rights / Prava: [In copyright](#)/[Zaštićeno autorskim pravom.](#)

Download date / Datum preuzimanja: **2025-01-14**



Repository / Repozitorij:

[Dr Med - University of Zagreb School of Medicine
Digital Repository](#)



Paget's Disease in Contralateral Breast Occuring 11 Years after Mastectomy for Invasive Ductal Carcinoma

Daniela Salopek¹, Jure Murgić¹, Davor Tomas², Ante Bolanča¹ and Zvonko Kusić¹

¹ Department of Oncology and Nuclear Medicine, University Hospital »Sestre milosrdnice«, Zagreb, Croatia

² Department of Pathology »Ljudevit Jurak«, University Hospital »Sestre milosrdnice«, Zagreb, Croatia

ABSTRACT

Paget's disease of the breast is a rare form of breast cancer and represents only 1% to 4% of all breast cancers. It is characterized by the presence of Paget's cells in the epithelium tissue (in epidermis) and it manifests as a lesion of the nipple. In most cases, Paget's disease is associated with an underlying breast malignancy. Mastectomy has been considered the treatment of choice, but breast conservation is also being explored, in properly selected patients, depending on the underlying malignancy. We report a case of Paget's disease occurring in the contralateral breast 11 years after mastectomy for invasive ductal carcinoma but with no underlying breast malignancy.

Key words: breast cancer, invasive ductal carcinoma, Paget's disease, mastectomy

Introduction

Paget's disease is a carcinoma that initially grows in the milk sinuses of the nipple, extending into the ducts beneath the nipple¹. It is a rare form of breast cancer that represents only 1% to 4% of all breast cancer². The clinical presentation of Paget's disease is a benign-appearing chronic eczematous eruption of the nipple-areolar complex³. Nipple discharge, pruritus and pain are often present and nipple bleeding can also be encountered⁴. Here we present a report of a patient diagnosed with contralateral Paget's disease 11 years after mastectomy for invasive ductal carcinoma.

Case Report

A 65-year-old woman was diagnosed 11 years ago with invasive ductal carcinoma of the right breast, infiltrating lymph nodes in the right axillary region. The patient underwent radical mastectomy with axillary evacuation and received postoperative radiotherapy treatment followed by tamoxifen hormonal therapy during 5 years. There was no signs of recurrence or advanced disease on yearly control examinations. Mammography and ultrasound examination did not show any suspicious findings on the left breast. In year 2005, she noticed a rash on the

left nipple which became retracted, and an eczematoid lesion which progressed slowly, during a few months time, into ulceration. Control mammography and ultrasound were performed and revealed no suspicious findings on the left breast or axilla. Excisional biopsy of the nipple lesion revealed nests and single large cells, with bright cytoplasm and hyperchromatic nuclei showing a specific, »pagetoid« extension through epidermis (Paget's cells) (Figure 1). Cells were immunohistochemically positive for cytokeratin 7 (Figure 2), HER-2/neu (Figure 3) and epithelial membrane antigen (Figure 4), but negative for estrogen and progesterone. Diagnosis of Paget's disease was established. Patient underwent left mastectomy with axillary evacuation. Both macroscopically and microscopically, in serial sections of the left breast, an underlying carcinoma was not found. Lymph nodes were also without tumor. No additional therapy was performed and one year after the surgery the patient showed no signs of tumor.

Discussion

Paget's disease is considered a rare form of breast carcinoma. The initial clinical manifestation of Paget's dis-

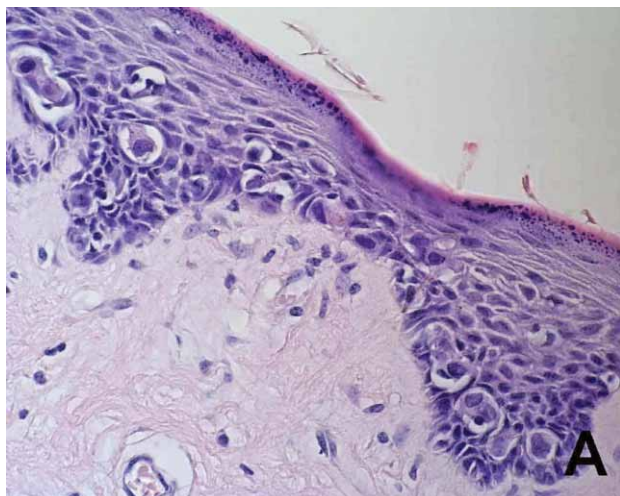


Fig. 1. Microscopic examination showed nests and single large cells, with bright cytoplasm and hyperchromatic nuclei with »pagetoid« extension through epidermis – Paget's cells (HEx400).

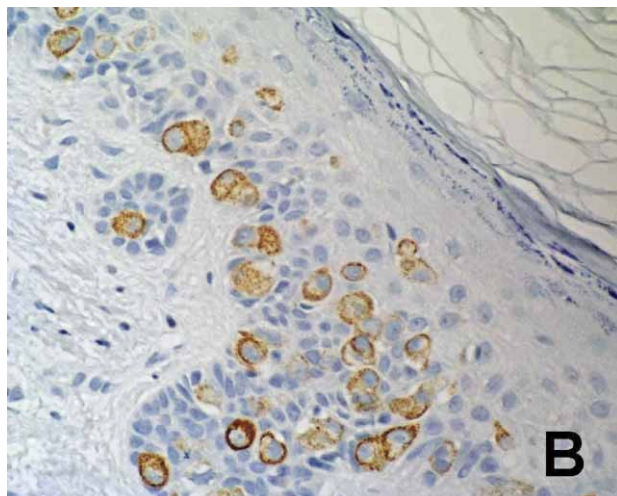


Fig. 2. Immunohistochemistry showed positive reaction for cytokeratin-7 (x400).

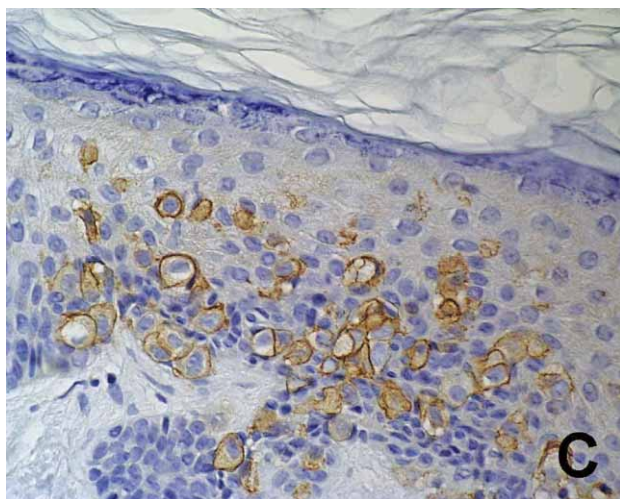


Fig. 3. Immunohistochemistry showed positive reaction for HER-2/neu (x400).

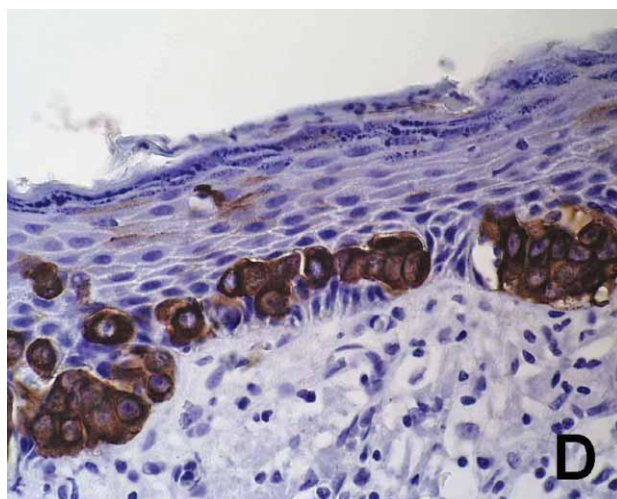


Fig. 4. Immunohistochemistry showed positive reaction for epithelial membrane antigen (x400).

ease is an eczematous or psoriasiform lesion of the nipple, extending to the mammary areola and the surrounding skin⁵, repeatedly healing and recurring over time. The disease typically originates from a high-grade in situ or infiltrating intraductal carcinoma, what is reflected in hormone receptor negative and HER-2/neu positive Paget cells⁶. A case of mammary Paget's disease originating from lobular in situ carcinoma has also been described⁷. But, Paget's disease can be presented without underlying carcinoma^{5,8}, as it is the case in our patient. Radical or modified radical mastectomy has been the treatment of choice for Paget's disease, with breast conserving surgery taking over in carefully selected and estimated cases. The question arises of the necessity and well-foundedness of any surgical therapy in Paget's disease of

the breast without an underlying breast malignancy. Quality of life of these women should also be of meaning. Paget's disease usually occurs synchronously with breast cancer, the same breast being affected. Rarely, but to be considered, we encounter a patient with Paget's disease associated with carcinoma of the contralateral breast⁹. So when Paget's disease is been diagnosed, it is important not to ignore the possibility of the existence of a nonpalpable lesion in the other breast. A case of Paget's disease developing after conservative surgery for ductal carcinoma of the breast has been known¹⁰. But, to our knowledge, a case of Paget's disease occurring on the contralateral breast after radical surgery for breast carcinoma, and with such time distance, has not been described yet.

REFERENCES

1. ROSEN PP, Rosen's Breast Pathology (Lippincot, Williams and Wilkins, Philadelphia, 2001). — 2. CHAUDARY MA, MILLIS RR, LANE B, MILLER NA, Breast Cancer Res Treat, 8 (1986) 139. — 3. SAKORAFAS GH, BLANCHARD K, SARR MG, FARLEY DR, Cancer Treat Rev, 27 (2001) 9. — 4. KOHLER S, ROUSE RV, SMOLLER BR, Mod Pathol, 11 (1998) 79. — 5. PRATENDA G, GUELI N, BOTTONI U, CALVIERI S, J Exp Clin Cancer Res, 17(4) (1998) 519. — 6. ROSEN PP, Arch Pathol Lab Med, 126 (2002) 1159. — 7. SAHOO S, GREEN I, ROSEN PP, Arch Pathol Lab Med, 126 (2002) 90. — 8. MORI O, HACHISUKA H, NAKANO S, MAEYAMA Y, SASAI Y, J Dermatol 21(3) (1994) 160. — 9. KIJIMA Y, OWAKI T, YOSHINAKA H, AIKOU T, Surg Today 33 (2003) 606. — 10. SHOUSA S, TISDALL M, SINNETT HD, Histopathology, 45(4) (2004) 416.

J. Murgić

*Department of Oncology and Nuclear Medicine, University Hospital »Sestre milosrdnice«, Vinogradska 29,
10000 Zagreb, Croatia
e-mail: juremurgic@inet.hr*

POJAVA PAGETOVE BOLESTI U KONTRALATERALNOJ DOJCI 11 GODINA NAKON MASTEKTOMIJE ZBOG DUKTALNOG INVAZIVNOG KARCINOMA

SAŽETAK

Pagetova bolest dojke je rijedak oblik karcinoma dojke koji predstavlja 1–4% svih zloćudnih tumora dojke. Karakterizirana je prisutnošću Pagetovih stanica u epidermisu i predstavlja leziju bradavice. U većini je slučajeva Pagetova bolest povezana sa pridruženim podležećim karcinomom dojke. Mastektomija se smatra liječenjem izbora, ali se posljedni kirurški zahvat također primjenjuje u pravilno izabranih bolesnica, ovisno o podležećoj malignosti. Prikazujemo slučaj pojave Pagetove bolesti u kontralateralnoj dojci, bez pridruženog maligniteta dojke, 11 godina nakon mastektomije zbog duktalnog invazivnog karcinoma.