

Algorithm for classification and treatment of poststernotomy wound infections

Vlajčić, Zlatko; Žic, Rado; Stanec, Sanda; Stanec, Zdenko

Source / Izvornik: **Scandinavian journal of plastic and reconstructive surgery and hand surgery, 2007, 41, 114 - 119**

Journal article, Accepted version

Rad u časopisu, Završna verzija rukopisa prihvaćena za objavljivanje (postprint)

<https://doi.org/10.1080/02844310701214479>

Permanent link / Trajna poveznica: <https://urn.nsk.hr/urn:nbn:hr:105:844389>

Rights / Prava: [In copyright](#)/[Zaštićeno autorskim pravom.](#)

Download date / Datum preuzimanja: **2024-07-14**



Repository / Repozitorij:

[Dr Med - University of Zagreb School of Medicine Digital Repository](#)





Središnja medicinska knjižnica

Vlajčić Z., Žic R., Stanec S., Stanec Z. (2007) *Algorithm for classification and treatment of poststernotomy wound infections. Scandinavian journal of plastic and reconstructive surgery and hand surgery, 41 (3). pp. 114-9. ISSN 0284-4311*

<http://informahealthcare.com/loi/alp>

<http://dx.doi.org/10.1080/02844310701214479>

<http://medlib.mef.hr/727>

University of Zagreb Medical School Repository

<http://medlib.mef.hr/>

Original Paper:

Algorithm for classification and treatment algorithm of poststernotomy wound infections

Zlatko Vlajcic, Rado Zic, Sanda Stanec & Zdenko Stanec

Department of Plastic Surgery, University Hospital "Dubrava", Zagreb, Croatia

Correspondence: Zlatko Vlajcic, MD, MSc, Department of Plastic Surgery, University

Hospital "Dubrava", Av. Gojka Suska 6, HR-10000 Zagreb, Croatia. Fax: +385 1 290 2451.

Tel: +385 98 60 77 60. E-mail: zvlajcic@kbd.hr

Brief title: Sternotomy infections, treatment algorithm

Abstract

The treatment of sternal wound infection still carries high mortality. Treatment preferences range from more conservative treatments that do not include flaps, to more aggressive reconstructions using different types of flaps, and these could be resolved and standardised using a proper classification with a treatment algorithm. We propose modification of the existing classification, with different proposals for treatment, stressing the importance of the radicality of debridement, and report our results in 31 patients, 24 of whom were well satisfied. Eleven were left with some pain in the chest wall, and eight each with some muscular weakness and less than adequate cosmesis. We would also like to recommend the omental flap as the first choice for selected cases. With our selective approach, we have achieved good functional and aesthetic results with satisfied patients.

Key words: Sternal wound, classification, treatment algorithm, follow-up

Introduction

The reported incidence of sternal wound infection after median sternotomy ranges from 0.4% to 5.9% [1], but the mortality is still high, varying from 14% [2] to 47% [3]. Obviously, this clinical entity, after cardiac surgical procedures, is still a significant problem.

There has been a trend for cardiac surgeons to prefer a more conservative approach to the treatment of sternal wound infections with rewiring of the sternum and closed mediastinal irrigation. Pedicled flaps have been reserved as a second line treatment in case the first fails [4]. Plastic surgeons prefer a more aggressive approach with early debridement and closure with the muscle flaps of infected median sternotomy wounds as “the standard against which all other treatment modalities must be compared” [5].

There is also the question of the best timing of the reconstruction. A one-stage procedure has been advocated, and confirmed in more recent reports [6]. As a modification of the procedure, a short intraoperative inflation of the SpaceMaker balloon to expand pectoralis major and enable tensionless closure has been described [7]. A two-stage closure has been suggested by Pairolero et al. [8]. As a bridge between debridement and delayed closure in two-stage wound treatment, vacuum assisted closure was recently described [9].

Finally, the debate has also been oriented towards the choice of initial reconstructive material. While most advocate the use of pedicled muscle or musculocutaneous flaps as the first choice and an omental flap only as a “life boat”, others prefer to use the omental flap initially as proposed by Lopez–Monjardin et al. [10].

Free flaps are also an option for sternal reconstruction [6].

In line with the experience that we gained during the recent war in Croatia with the treatment of lower extremities war wounds as high-energy wounds or defects, we prefer the “pseudo-tumoral” approach to infected poststernotomy wounds, consisting of radical

resection of all non-viable tissue and reconstruction with well-vascularised tissue in a one-stage procedure.

Patients and Methods

The clinical records of all patients treated at the Department of Plastic Surgery, University Hospital "Dubrava", Zagreb, with flaps for poststernotomy wound infections were studied.

The initial cardiac surgery was done at the Department of Cardiac Surgery, University Hospital "Dubrava", Zagreb, University Hospital Center "Rebro", Zagreb, and Special Hospital for Cardiology and Cardiothoracic Surgery "Magdalena", Krapinske Toplice, from 1996 to 2004. All patients had been previously treated unsuccessfully by Robicsek's rewiring of the sternum [11] and closed mediastinal irrigation or open packing with attempts at secondary closure. Our intention was not to define the risk factors for postoperative sternal wound infection, because our group of patients was not big enough to resolve the issue.

Patients were entered into the study at their first consultation with the plastic surgeon. A history was taken, clinical examination made, and the poststernotomy wound infection categorised. We had no influence on the previous treatments during the patients' stay at the Cardiac Department, and the microbiological cultures were usually taken in that department. The overall incidence of sternal wound infection after median sternotomy was 3%, mostly Gram-positive bacteria. *Staphylococcus aureus* was isolated in 12/31 and *S. epidermidis* in 9/31 of the cases. We did not use quantitative tissue cultures to decide the timing of wound closure. Our modified classification of poststernotomy wound is shown in Table I.

The clinical follow-up was prospective and ranged from 3 weeks to 8 years (Table II). Haematomas, sternal instability, hernias and bulges, skin necrosis, deformities of the chest contour (axillary hollows), deaths, primary or secondary closure, and recurrence of infections were recorded with photographs and questionnaire. The questionnaire was used to assess

subjective chest wall pain, cosmesis, and shoulder or abdominal weakness, through the ability to do daily activities (to stand from a sitting or supine position, to open a door, and to lift and carry a bag of groceries), and to grade overall satisfaction (Table III).

From 1996 to 2004, we treated 31 patients with sternal wound infections by radical debridement and reconstruction with pedicled flaps. Most of our cases were type 2B (13/31) and 2C (10/31). There were also six of type 3, and two of type 4. Types 1 and 2A, were usually successfully treated by the cardiac surgeons with open packing and secondary closure or rewiring. All our patients were seen when their wounds were in chronic phase according to the classification of El Oakley and Wright [4], usually three or more weeks after open heart surgery.

Surgical treatment, under general anaesthesia, consisted of radical debridement of all necrotic soft tissue, bone, and costal cartilage with simultaneous reconstruction, except for the type 4, which were treated by delayed closure after aggressive treatment with antibiotics given parenterally, and chosen according to the results of quantitative tissue culture. When the entire sternum was devascularised or necrotic, we did not hesitate to remove the sternum. All flaps for reconstruction were pedicled. The reconstructive options for sternal osteitis with non-viable bone may be divided depending on the site of the sternal dehiscence or instability (2B and 2C). Patients with upper and middle third defects were treated with bilateral or unilateral pectoralis major transposition flaps or turnover flaps. The patients with lower third defects were treated with VRAM (vertical rectus abdominis musculocutaneous) flaps, omental flaps, bipedicled composite pectoralis major and rectus abdominis flaps and a latissimus dorsi flap was used in only one case. For type 3 and 4 we used omentum alone or omentum with VRAM or pectoralis major advancement musculocutaneous flaps for additional cover. However, we prefer to close the overlying skin and subcutaneous tissue directly after undermining, if possible.

Results

Thirty-one patients had sternal reconstructive procedures and were followed up for 3 weeks to 8 years (mean 3 years). The small sample size precluded statistical analysis but trends were noted related to complications and patients' satisfaction. Four patients died, all of whom had co-existing conditions (diabetes mellitus, hypertension, and atherosclerosis) in addition to the underlying cardiac disease. One patient died three weeks after reconstruction and three of them after discharge. No deaths were connected to the reconstructive procedure. Their hospital stay ranged from 8 to 40 days (median 18). All had healed wounds at the time of death or discharge, 29 closed primarily two secondarily.

One case of skin necrosis was connected to the composite pectoralis major and rectus abdominis flap and the second one to a VRAM flap. Clinically confirmed instability of the thoracic wall was noted in only one patient who had been treated by total sternectomy and reconstruction with an omental flap but with no respiratory dysfunction. All cases of total sternectomy (8/31) were type 3 or 4 and had the great omentum transposed as the first choice, either immediately (n=6) or after a delay of 24 to 48 hours (n=2). No case of chronic pain in the chest wall was associated with total sternectomy. Mediastinitis was definitively cured in all cases by total sternectomy and omental flaps.

Unsatisfactory cosmesis was clearly associated with the VRAM flap (Figure 1). Most of our patients were not as concerned with the length of the scar as with the bulge in the sternal region, which they regarded as the reason for the "unsatisfactory cosmesis". Two patients who had partial sternectomy developed minor recurrence of the infection (cutaneous fistulas) after three and six years postoperatively, respectively. Both were cured by removing the remaining wire from the upper part of the sternum. Clinically obvious hernias were noticed in two cases; in one the abdominal wall weakness was associated with the composite pectoralis major-rectus abdominis reconstruction, and the other was a true suprapubic hernia

related to the VRAM flap, but both patients refused reoperation. Minor abdominal wall weaknesses were often noticed in association with the VRAM reconstruction in the distal part of the abdomen, and axillary hollows (Figure 2) were related to the transposition and advancement flap of pectoralis major with resection of the humeral attachment in 5/8 cases. The overall satisfaction in 24 patients was high (Table III).

Discussion

There is no single ideal treatment for all cases of sternal wound infection. For this reason, proper classification should logically suggest the treatment modalities. As far as we know, there are three classifications about this entity.

The classifications

The classification of El Oakley and Wright [4] is related to the time that the mediastinitis presents, and the presence or absence of risk factors, with no distinction between a stable and unstable sternum.

That of Pairolero et al. [8] is chronological. Type I occurs within days after operation, type II within the first few weeks and type III occurs months to years later.

The classification made by Jones et al. [12] considers the exact wound, but the flaw in their classification is the failure to classify separately sterile instability of the sternum or sterile wound dehiscence with viable bone, which is said to be present in 60% of patients [13]. This distinction is important for treatment. There is however, an unnecessary distinction between two superficial types of wounds (1A and 1B). A further objection is the lack of definition of mediastinitis, as Pairolero et al. and El Oakley and Wright have done.

Mediastinitis is defined by El Oakley and Wright as a “wound infection associated with sternal osteomyelitis with or without infected retrosternal space”, which means that they make no clear distinction between sternal osteitis and mediastinitis. We think that

mediastinitis should be defined as the inflammation of cellular tissue in the mediastinum, because its treatment is urgent, and differs from the treatment of osteomyelitis of the sternum.

A good classification should suggest the treatment for each group of patients.

Important variables that should be included in any classification and treatment of poststernotomy wound infections are: the presence of sternal instability with a distinction made between sternal dehiscence with viable uninfected bone and sternal dehiscence with osteomyelitis, and the presence or absence of suppurative mediastinitis, or a more precise distinction between sternal osteitis and mediastinitis.

Delayed closure for 48h with aggressive antibiotics given parenterally for type 4 is essential. More than 48h delay could be associated with desiccation and rupture of coronary grafts and ventricular wall.

Radical debridement

Two cases of local recurrence in our follow-up, after three and six years, might have resulted from the partial sternectomy. We found no case of local recurrence after total sternectomy. The importance of radical debridement has been tested and confirmed over many years.

According to Kohman et al. [14], even total sternectomy without stabilisation of the thoracic wall will not affect late pulmonary function, and the comparison between debridement and flap coverage and sternal rewiring gives no difference in stability or strength of the chest wall [15]. This is an additional argument for radical debridement as the most important factor of infection control. In our follow-up chest wall pain was not related to total sternectomy but to some partial sternectomies, which might be explained by the prevention of painful contact of the bony edges in total sternectomy as noted by Wettstein et al. [6].

Choice of flap

We do not accept the tenet about the choice of reconstructive procedure for mediastinitis (type 3) “being unnecessary to actually fill the mediastinum with our flaps [16]”, and would like to

accentuate the obliteration of the dead space with vascularised tissue as an important aspect of infection control instead of covering only the wound.

The disadvantages for transposition of pectoralis major (based on the thoracoacromial arteries) is that it gives insufficient volume to fill some of the larger defects often created by wide debridement, and particularly makes it difficult to reach the inferior third of the sternum. Nevertheless, transposition of pectoralis major remains the flap of choice for type 2B due to its simplicity and efficiency.

Reconstruction of the lower third of the sternum (type 2C) is more difficult, particularly after unilateral or bilateral usage the internal mammary artery for myocardial revascularisation or lesion of the artery during rewiring or sternectomy. A pectoralis major turnover flap (based on perforators of the internal mammary) therefore cannot be used safely. The same applies to the VRAM flap, but we also have additional concerns about the inconsistent viability of the distal portion of the skin island and weakness of the abdominal wall. Any lesion of the superior epigastric artery involving a previous subcostal incision could also preclude the use of this flap. The latissimus dorsi pedicled flap is also insufficient to cover this region and its demands for extensive subcutaneous dissection, which increases the incidence of seromas, and haematomas and could promote infection. The same applies to the composite pectoralis major - rectus abdominis flap. Two of our cases of skin necrosis were associated with the use of this and the VRAM flap.

Omental flap

We found that the omental flap, with direct skin closure or advancement of pectoralis major for additional cover, was the flap of choice for selected cases (type 3) from both the functional and the aesthetic results (Figure 3). Omentum is an excellent source of tissue volume which can reach the deepest recesses of the sternal wound and obliterate it. It has good vascularity, lymphatic vessels that can absorb exudates rapidly, and immunological and biological

attributes, including cellular proliferation and fibrous tissue formation. It is therefore associated with fewer infective complications than the pectoralis major flap alone [10]. Omental lipid extract also has an angiogenic effect [17]. The disadvantage of using the omentum is the possibility of intra-abdominal infection, and complications such as epigastric herniation, and bowel obstruction. The use of the omentum is not indicated in patients who have had previous major upper abdominal surgery.

We know of only one published case of infection that was propagated into the abdominal cavity as a subphrenical abscess [18], but one of the authors of that paper stated that they had not found intra-abdominal sepsis [12]. Pairolero et al. [8] noticed five of 19 patients with omental transpositions who developed asymptomatic hernias through the tunnel by which the omentum was passed, but these did not require intervention. Laparoscopic dissection and mobilisation of the omentum eliminates the major drawback of using the omentum – laparotomy but it is still optional.

Our results support our modification of the classification with suggestions for treatment of each group of patients. They also stress the importance of radical debridement as the dominant factor influencing the outcome of patients with poststernotomy wound infections. In patients with type 3 or 4 of sternal wound infection (suppurative mediastinitis) the omental flap is our first choice with direct skin closure. In patients with larger defects or insufficient skin for direct closure the omentum should be covered with muscle flaps (pectoralis major advancement flap) before closure or grafting of the skin.

Acknowledgements

We thank Dr. J. Skrlin, MD, PhD, Department of Clinical Microbiology and Hospital Infections, University Hospital “Dubrava” Zagreb, Croatia, and Prof. Z. Sutlic, MD, PhD, Department of Cardiac Surgery, University Hospital “Dubrava” Zagreb, Croatia, for their contributions to this work.

References

- [1] Oh AK, Lechtman AN, Whetzel TP, Stewenson TR. The infected median sternotomy wound: management with the rectus abdominis musculocutaneous flap. *Ann Plast Surg* 2004;52:367-70.
- [2] Loop FD, Lytle BW, Cosgrove DM, et al. J. Maxwell Chamberlain memorial paper. Sternal wound complications after isolated coronary artery bypass grafting: early and late mortality, morbidity, and cost of care. *Ann Thorac Surg* 1990;49:179-87.
- [3] Serry C, Bleck PC, Javid H, et al. Sternal wound complications. Management and results. *J Thorac Cardiovasc Surg* 1980;80:861-7.
- [4] El Oakley RM, Wright JE. Postoperative mediastinitis: classification and management. *Ann Thorac Surg* 1996;61:1030-6.
- [5] Ringelman PR, Vander Kolk CA, Cameron D, Baumgartner WA, Manson PN. Long-term results of flap reconstruction in median sternotomy wound infections. *Plast Reconstr Surg* 1994;93:1208-16.
- [6] Wettstein R, Erni D, Berdat P, Rothenfluh D, Banic A. Radical sternectomy and primary musculocutaneous flap reconstruction to control sternal osteitis. *J Thorac Cardiovasc Surg* 2002;123:1185-90.
- [7] Hauben DJ, Shulman O, Levi Y, Sulkes J, Amir A, Silfen R. Use of the SpaceMaker balloon in sternal wound closure: comparison with other techniques. *Plast Reconstr Surg* 2001;108:1582-90.
- [8] Pairolero PC, Arnold PG, Harris JB. Long-term results of pectoralis major muscle transposition for infected sternotomy wounds. *Ann Surg* 1991;213:583-90.
- [9] Song DH, Wu LC, Lohman RF, Gottlieb LJ, Franczyk M. Vacuum assisted closure for the treatment of sternal wounds: the bridge between debridement and definitive closure. *Plast Reconstr Surg* 2003;111:92-7.

- [10] Lopez–Monjardin H, de-la-Pena–Salcedo A, Mendoza–Munoz M, Lopez-Yanez-de-la-Pena A, Palacio-Lopez E, Lopez-Garcia A. Omentum flap versus pectoralis major flap in the treatment of mediastinitis. *Plast Reconstr Surg* 1998;101: 1481–5.
- [11] Robicsek F, Daugherty HK, Cook JW. The prevention and treatment of sternum separation following open-heart surgery. *Coll Works Cardiopulm Dis* 1977;21:61-3.
- [12] Jones G, Jurkiewicz MJ, Bostwick J, et al. Management of the infected median sternotomy wound with muscle flaps. The Emory 20-year experience. *Ann Surg* 1997;225:766-78.
- [13] Bryan AJ, Lamarra M, Angelini GD, West RR, Breckenridge IM. Median sternotomy wound dehiscence: a retrospective case control study of risk factors and outcome. *J R Coll Surg Edinb* 1992;37:305-8.
- [14] Kohman LJ, Auchincloss JH, Gilbert R, Beshara M. Functional results of muscle flap closure for sternal infection. *Ann Thorac Surg* 1991;52:102-6.
- [15] Francel TJ, Kouchoukos NT. A rational approach to wound difficulties after sternotomy: reconstruction and long-term results. *Ann Thorac Surg* 2001;72:1419-29.
- [16] Ascherman JA, Patel SM, Malhotra SM, Smith CR. Management of sternal wounds with bilateral pectoralis major myocutaneous advancement flaps in 114 consecutively treated patients: refinements in technique and outcomes analysis. *Plast Reconstr Surg* 2004;114:676-83.
- [17] Cartier R, Brunette I, Hashimoto K, Bourne WM, Schaff HV. Angiogenic factor: a possible mechanism for revascularization produced by omental pedicles. *J Thorac Cardiovasc Surg* 1990;99:264-8.
- [18] Pairolero PC, Arnold PG. Management of recalcitrant median sternotomy wounds. *J Thorac Cardiovasc Surg* 1984;88:357-64.

Legends to figures

Figure 1. Thoracic bulge six years after vertical rectus abdominis musculocutaneous flap reconstruction with the: (a) Frontal and (b) side view. The patient declined proposed liposuction.

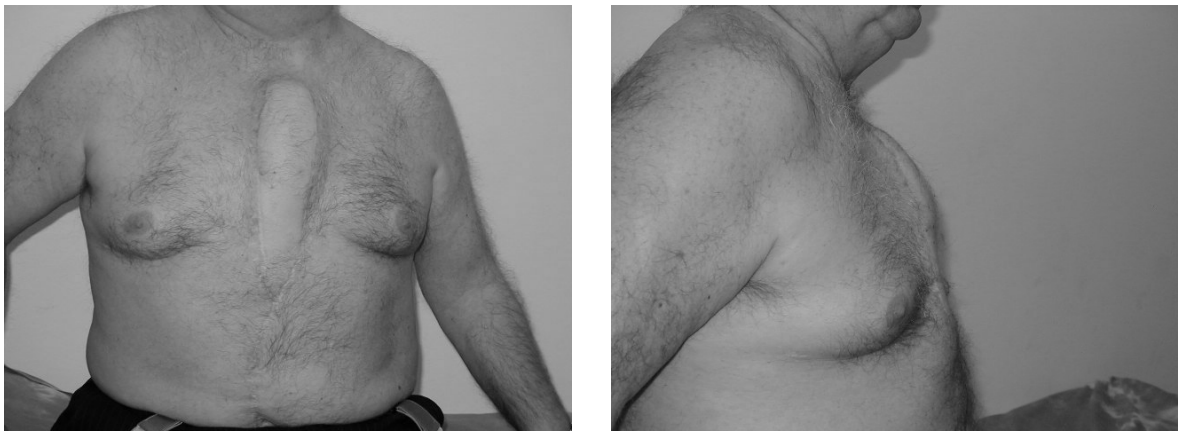


Figure 2. (a) Frontal and (b) side view showing the axillary hollow four years after the sternal reconstruction with a pectoralis major bilateral transposition flap.

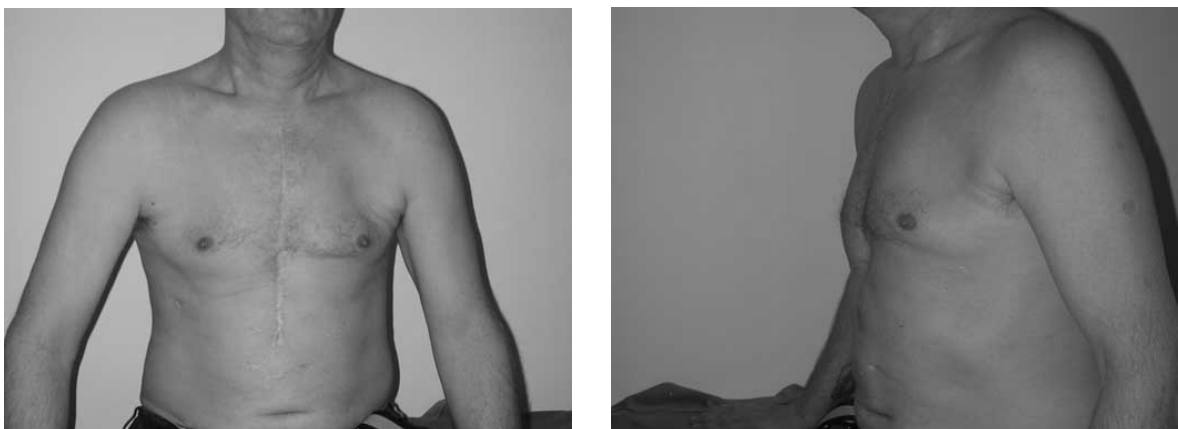

Figure 3. (a) Frontal and (b) side view showing a good result with an omental flap two years after the reconstruction.

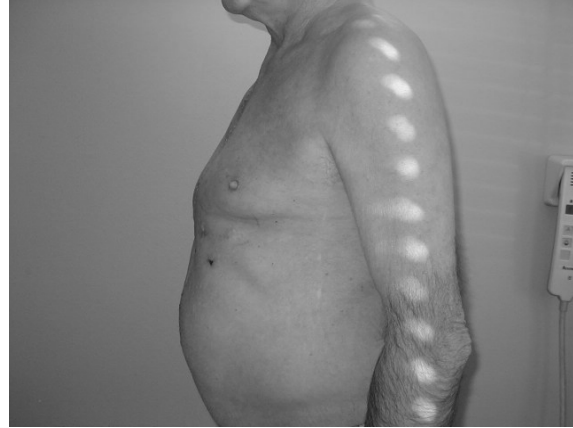
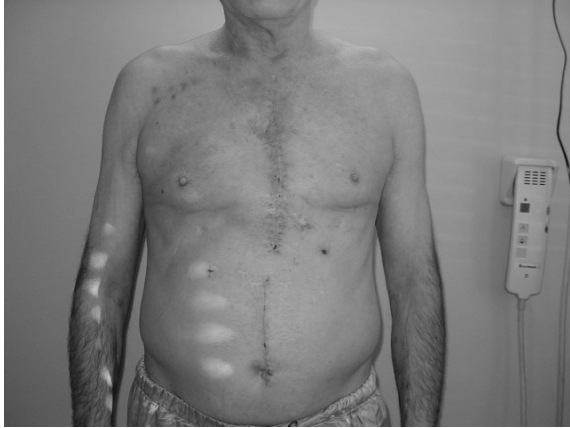
Table I. Modification of the Jones's classification of sternal wound infection

Type	Classification of wound	First choice of treatment
1	Superficial wound dehiscence Stable sternum Sterile (Gram stain of fluid from sternal puncture)	Debridement, dressing, secondary closure – direct, local flaps or split-skin graft
2	Unstable sternum (sternal dehiscence)	
	A-Sterile viable bone	Debridement, rewiring (Robicsek)
	B-Sternal osteitis, non-viable bone, upper two-thirds	Partial sternectomy (radical debridement) Pedicled pectoralis major transposition, advancement or turnover
	C- Sternal osteitis, non-viable bone, lower third	Partial sternectomy (radical debridement) Pedicled omental flap (second choice - latissimus dorsi, bipedicled pectoralis major plus rectus abdominis, or VRAM)
3	Mediastinitis (suppurative)	Total sternectomy Omentum pedicled flap plus pectoralis major advancement flap
4	2 or 3 with septicaemia	Radical debridement, delayed closure (<48h), aggressive parenteral antibiotics

VRAM = vertical rectus abdominis musculocutaneous flap

Table II Outcome of reconstruction

Flaps	Total No	Total sternectomy	Unstable thoracic wall	Haematoma	Partial skin necrosis	Recurrent infection	Hernia	Bulges	Axillary hollows
Pectoralis major:									
Bilateral transposition	8	0	0	0	0	1	0	2	5
Unilateral transposition	2	0	0	0	0	1	0	0	0
Turnover	2	0	0	0	0	0	0	0	0
Plus rectus abdominis (composite)	3	0	0	1	1	0	1	0	2
VRAM	7	0	0	1	1	0	1	5	0
Omentum:									
Alone	4	4	1	0	0	0	0	0	0
Plus VRAM	1	1	0	0	0	0	0	1	0
Plus pectoralis major advancement	3	3	0	0	0	0	0	0	0
Latissimus	1	0	0	1	0	0	0	1	0
Total	31	8	1	3	2	2	2	9	7

VRAM = Vertical rectus abdominis musculocutaneous flap

Table III. The patients observations from the questionnaire

Flap	Total No	Pain in chest wall	Muscular weakness	Poor cosmesis	Overall satisfataction
Pectoralis major:					
Bilateral transposition	8	5	4	0	7
Unilateral transposition	2	1	0	0	2
Turnover	2	0	1	0	2
Plus rectus abdominis (composite)	3	2	1	1	2
VRAM	7	2	2	6	3
Omentum:					
Alone	4	0	0	0	5
Plus VRAM	1	0	0	1	0
Plus pectoralis major advancement	3	0	0	0	2
Latissimus	1	1	0	0	1
Total	31	11	8	8	24

VRAM = Vertical rectus abdominis musculocutaneous flap