

# Primary malignant fibrous histiocytoma of the heart with skeletal muscles metastases

---

Miličić, Davor; Juretić, Antonio; Bulum, Joško; Šarić, Nera; Bišof, Vesna; Jelić, Ivan; Jelašić, Dražen

Source / Izvornik: **Journal of Cardiac Surgery, 2007, 22, 513 - 516**

**Journal article, Accepted version**

**Rad u časopisu, Završna verzija rukopisa prihvaćena za objavljivanje (postprint)**

<https://doi.org/10.1111/j.1540-8191.2007.00451.x>

Permanent link / Trajna poveznica: <https://urn.nsk.hr/urn:nbn:hr:105:812578>

Rights / Prava: [In copyright](#) / [Zaštićeno autorskim pravom.](#)

Download date / Datum preuzimanja: **2024-10-11**



Repository / Repozitorij:

[Dr Med - University of Zagreb School of Medicine  
Digital Repository](#)





## Središnja medicinska knjižnica

**Miličić D., Juretić A., Bulum J., Šarić N., Bišof V., Jelić I., Jelašić D.  
(2007) *Primary malignant fibrous histiocytoma of the heart with  
skeletal muscles metastases. Journal of Cardiac Surgery, 22 (6). pp.  
513-6. ISSN 0886-0440***

<http://www.wiley.com/bw/journal.asp?ref=0886-0440>

<http://www.interscience.wiley.com/jpages/0886-0440>

<http://dx.doi.org/10.1111/j.1540-8191.2007.00451.x>

<http://medlib.mef.hr/730>

University of Zagreb Medical School Repository

<http://medlib.mef.hr/>

# **Primary malignant fibrous histiocytoma of the heart with skeletal muscles metastases**

Davor Milicic\* MD, PhD, Antonio Juretic<sup>1</sup> MD, PhD, Josko Bulum\* MD, Nera Saric<sup>1</sup> MD,  
Vesna Bisof<sup>1</sup> MD, Ivan Jelic<sup>2</sup> MD, PhD, Drazen Jelasic<sup>3</sup> MD

*\*University Clinic of Cardiovascular Diseases, Clinical Hospital Centre Zagreb*

*<sup>1</sup>Clinic of Oncology, Clinical Hospital Centre Zagreb*

*<sup>2</sup>Clinic of Cardiac Surgery, Clinical Hospital Centre Zagreb*

*<sup>3</sup>Department of Pathology, Clinical Hospital Centre Zagreb*

## ***Address for correspondence:***

Josko Bulum, MD

*University Clinic of Cardiovascular Diseases*

*Clinical Hospital Centre Zagreb*

Kispaticeva Street 12

10 000 Zagreb, Croatia

Phone no: +385 1 2388 888 (474)

Fax no: +385 1 2312 247

E-mail: josko.bulum@zg.t-com.hr

Malignant fibrous histiocytoma of heart

## **Abstract**

Malignant fibrous histiocytoma is extremely rare primary malignant tumor of the heart. It is usually diagnosed when it is locally aggressive or has already metastasized. The prognosis is poor with the average survival time of one year. We report a case of recurrent left atrial malignant fibrous histiocytoma initially misdiagnosed as myxoma. The patient underwent repeated surgical resections followed by chemotherapy. Despite adjuvant chemotherapy, 18 months after initial diagnosis definitive tumor relapse in left atrium was diagnosed. This is the 48<sup>th</sup> case of primary cardiac fibrous malignant histiocytoma reported in literature.

## **Key words**

Echocardiography, heart, malignant fibrous histiocytoma, metastases

## Introduction

Primary cardiac tumors are rare, with an autopsy incidence ranging from 0.001% to 0.03% (1). About three-quarters of these tumors are benign and nearly half of them are myxomas. Malignant fibrous histiocytoma (MFH) is the most common soft tissue sarcoma in adults, but is extremely rare as a primary tumor of the heart (2). MFH is a malignant tumor of fibroblasts and pleomorphic histiocytoid cells with large number of bizarre, multi-nucleated giant cells. Their stroma might be sometimes myxoid and moreover they might be occasionally misdiagnosed as a myxoma (3). Cardiac tumors present with one or more symptoms of the classic triad: intracardiac obstruction, systemic embolisation and systemic symptoms like fever, arthralgia, weight loss and fatigue. The prognosis of patients having even nonmetastatic primary cardiac sarcomas is relatively poor with very few patients surviving for more than one year after diagnosis (4). Reasons for this dismal outcome are the diagnosis of this type of tumors in advanced stage of disease, impossibility to perform adequate radical tumor excision and the cardiotoxic side effects of radiotherapy and of some cytotoxic drugs (5). Early cardiac transplantation, if possible, might be a promising therapy for patients with nonmetastatic malignant cardiac sarcomas (6). We present the female patient with the malignant fibrous histiocytoma of the left atrium.

## Case report

A 58 year-old white woman was admitted to our hospital in September 2003 with history of congestive heart failure and bilateral pleural effusion three months ago. She underwent total thyroidectomy with parathyroidectomy and subsequent radioactive iodine administration in 2000 because of papillary carcinoma of a thyroid gland. On admission she was euvoic in rest and afebrile, blood pressure was 140/90 mmHg, heart rate was regular, 96 beats/min. Electrocardiogram revealed sinus rhythm with occasional extrasystoles. Pulmonary, cardiac and abdominal examination was unremarkable. There were no palpable lymph nodes. Transthoracic (TTE) and transesophageal echocardiography (TEE) revealed large, partially mobile tumorous mass 4x2 cm in the left atrium, which was partially obstructing blood flow through the mitral valve. According to its localization and appearance on echocardiography the tumor was suggestive for myxoma. No other tumor was found in the chest and abdomen. Open heart surgery under cardiopulmonary bypass was done and tumor was successfully resected; histopathology diagnosis was myxoma. Control TTE in December 2003 showed tumor recurrence that occupied 2/3 of the left atrium. Re-operation was performed in February 2004 and maximal tumor reduction was done. Also the pathological specimen in paraffin block from first operation went for revision. Histopathology diagnosis was malignant fibrous histiocytoma (figures 1 and 2) for both specimens. No further therapy was applied and the patient was discharged. Control TEE done one month after re-operation showed local tumor recurrence in the left atrium (figure 3) with complete tumor infiltration of left atrial free walls. CT scan showed no tumor propagation into the pulmonary veins or pericardium, and no systemic metastases were found. Because of extremely locally aggressive nature of the tumor the patient was scheduled for orthotopic cardiac transplantation. Subsequently, eight cycles of chemotherapy with doxorubicin and ifosfamide with mesna uroprotection were applied. Control TEE in September 2004 showed tumor remission after chemotherapy. Control echocardiography in April 2005 showed local tumor recurrence in left atrium measuring 1.2 x 1.2 cm. The next check-up in June 2005 indicated definitely tumor relapse because tumor size increased from 1.2 x 1.2 to 2.5 x 3.9 cm.

Moreover, the patient noticed the growing subcutaneous nodule on the plantar surface of her right foot which was resected in June 2005. The histopathology examination revealed malignant fibrous histiocytoma measuring 5 x 6 cm. Because of local tumor relapse and distal metastasis the patient has been removed from transplantation list. Four cycles of second line chemotherapy (cyclophosphamide, vincristine and dacarbazine) were applied from July to September September 2005. During the hospitalization for fourth chemotherapy cycle CT scan revealed a metastasis measuring 10 cm in diameter located predominantly in the vastus lateralis muscle. Gemcitabine and docetaxel were chosen for further chemotherapy and patient has received a first cycle in October 2005. Two and a half weeks after she was hospitalized because of acute massive pulmonary embolism, TTE showed tumor recidive which occupied more than one half of the left atrium (figure 4). Her condition improved after conservative therapy but this improvement was not sufficient for the continuation of chemotherapy. Unfortunately, only further therapeutic option left is very risky live saving surgical resection in the case of mitral flow obstruction.

## Discussion

Soft-tissue sarcomas are rare tumors accounting for approximately 1% of all cancers worldwide each year. There exists a variety of histological subtypes of sarcomas; the most common is malignant fibrous histiocytoma (MFH). The choice of treatment generally depends on the location, size and histological grade of the primary soft tissue sarcoma and patient's performance status. Surgical resection with pathologically proven clear margins is the treatment of choice for localized sarcomas. Postoperative radiation therapy plays a major role as an adjunct to surgery in improving local tumor control compared to surgery alone. Chemotherapy is also a treatment modality for the soft tissue sarcomas. Primary cardiac tumors including sarcomas are exceedingly rare. The majority of these are benign which are often successfully treated by surgical excision. In contrast, malignant cardiac tumors are associated with poor long-term survival despite surgery, radiotherapy and chemotherapy. However, surgical resection is often required for diagnosis or to relieve symptoms. Malignant fibrous histiocytoma is exceptionally rare primary cardiac tumor. Only 43 cases of surgical therapy for cardiac MFH have been documented since the initial report of Shah et al. in 1978 (7). Among reported cases of MFH thirty patients (63%) were female and eighteen patients (37%) were male. Primary location of MFH is in the most of the cases left atrium, although it has been reported in the pericardium, right ventricle and/or pulmonary valve, right atrium, left ventricle and at the site of an atrial septal defect. Very few data are available for the most appropriate management of cardiac sarcomas. At present, no uniform consensus exists regarding the best treatment strategies but therapy requires a multidisciplinary team approach. A radical surgical approach if possible represents the only effective therapeutic measure. But, in most of the cases complete resection is not possible either due to the local invasion or proximity to the vital structures. Radiotherapy due to its cardiotoxicity at radical doses can not be considered as an optimal therapy for malignant cardiac tumors. The doses which are effective are known to cause cardiomyopathy and chronic radiation pericarditis (8). Chemotherapy has also its limitations such as a relatively low response rates. Moreover, doxorubicin which is effective chemotherapeutic drug and therefore commonly used for the



soft tissue sarcomas is cardiotoxic what limits its usage and effectiveness in patients having cardiac sarcomas (9). For patients with unresectable or partially resectable heart sarcomas radiation and chemotherapy may be used, but without great expectation of long term tumor control. Limited evidence shows that selected patients with nonmetastasing MFH can benefit from orthotopic cardiac transplantation (6). Cardiac neoplasms have not been routinely considered for OHT because of concern for tumor recurrence and the possibility that immunosuppression may stimulate further tumor growth. On the other hand, an increasing number of patients with treated malignancies such as Hodgkin's disease and breast cancer have undergone successful OHT without an increase in primary tumor recurrence (10). In our patient maximal surgical reduction was performed. Knowing the malignant nature of the patient's tumor, decision for cardiac transplantation and adjuvant chemotherapy while waiting for the organ was made. Doxorubicin and ifosfamide were selected for the first line chemotherapy regimen. Disease stabilization and even partial remission was obtained lasting for approximately 12 months. During second line chemotherapy the metastasis in the left thigh was noticed indicating tumor insensitivity to these cytotoxic drugs. Combination of gemcitabine and of docetaxel was attempted (11, 12) but development of lung embolism and the deterioration of patient's performance status prevented further application of chemotherapy. The radiotherapy was not applied because of already mentioned cardiotoxicity. In the case of soft tissue sarcoma distant spread is by the hematogenous route and lung metastases are the commonest metastatic site followed by bone and liver. Metastases in soft tissue are much rarer except in alveolar soft part sarcoma. The presented patient during our follow-up has never developed metastases at the lung, bone or liver. Moreover, two distant metastases she developed were both in the skeletal muscles what is for the soft tissue sarcomas and probably for the heart sarcomas a rather peculiar metastatic sites. Strict follow-up of patients with MFH is mandatory because it has a high rate of recurrence and metastasing. Development of an optimal therapy for MFH will need improved understanding of the natural history and prognostic factors of this very rare disease. Adjunctive chemotherapy in conjunction with resection remains the first line therapy. The

potential gain of radiotherapy must be weighed against the risk of damage to myocardium and pericardium. The role of cardiac transplantation for primary cardiac MFH should be weighed on a case-by –case basis for patients who present with unresectable tumor and no extracardiac evidence of disease.

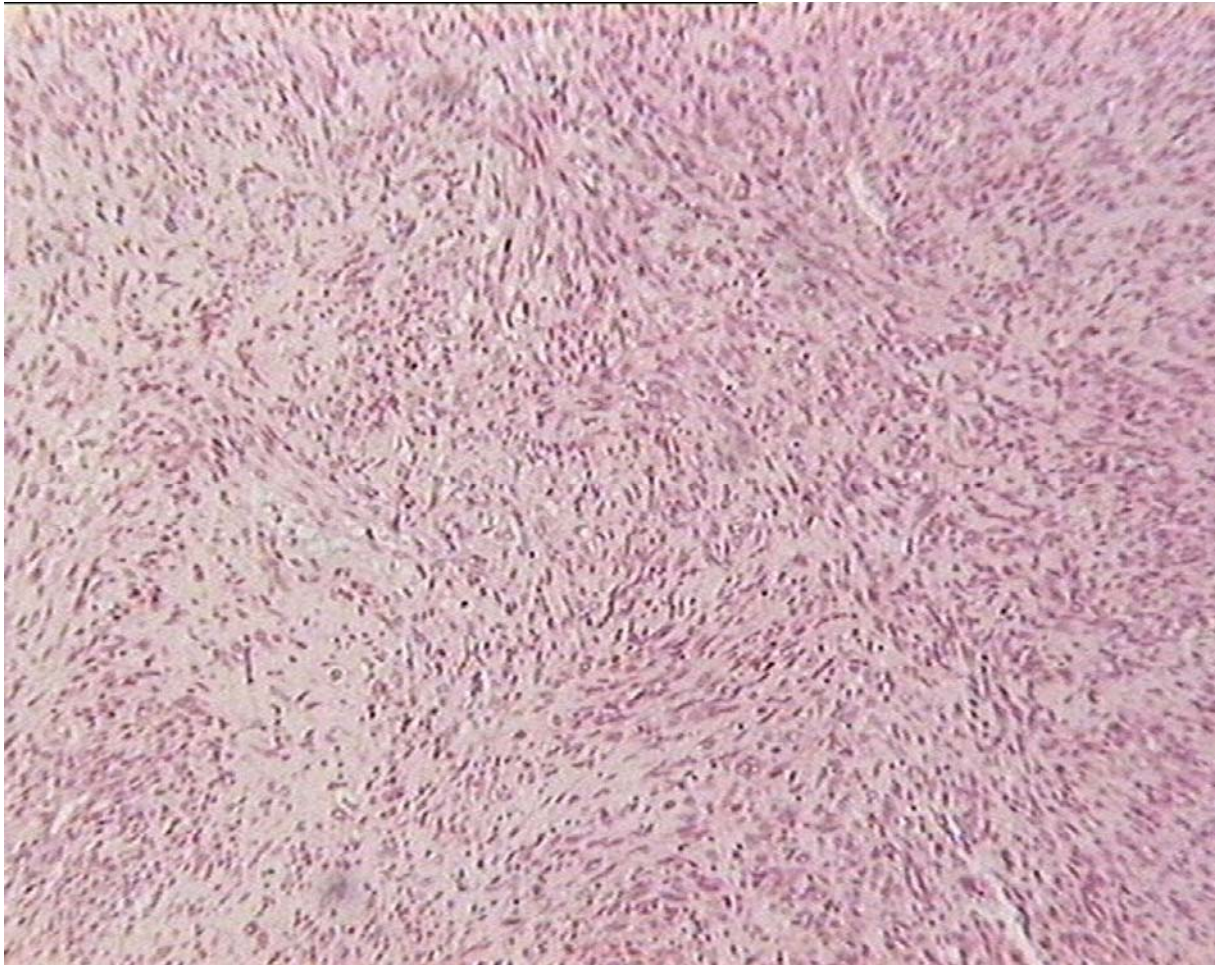
**Acknowledgement:** This work was partially supported by the Ministry of Science and Technology of the Republic of Croatia (grant no. 0074004 to AJ)

## References

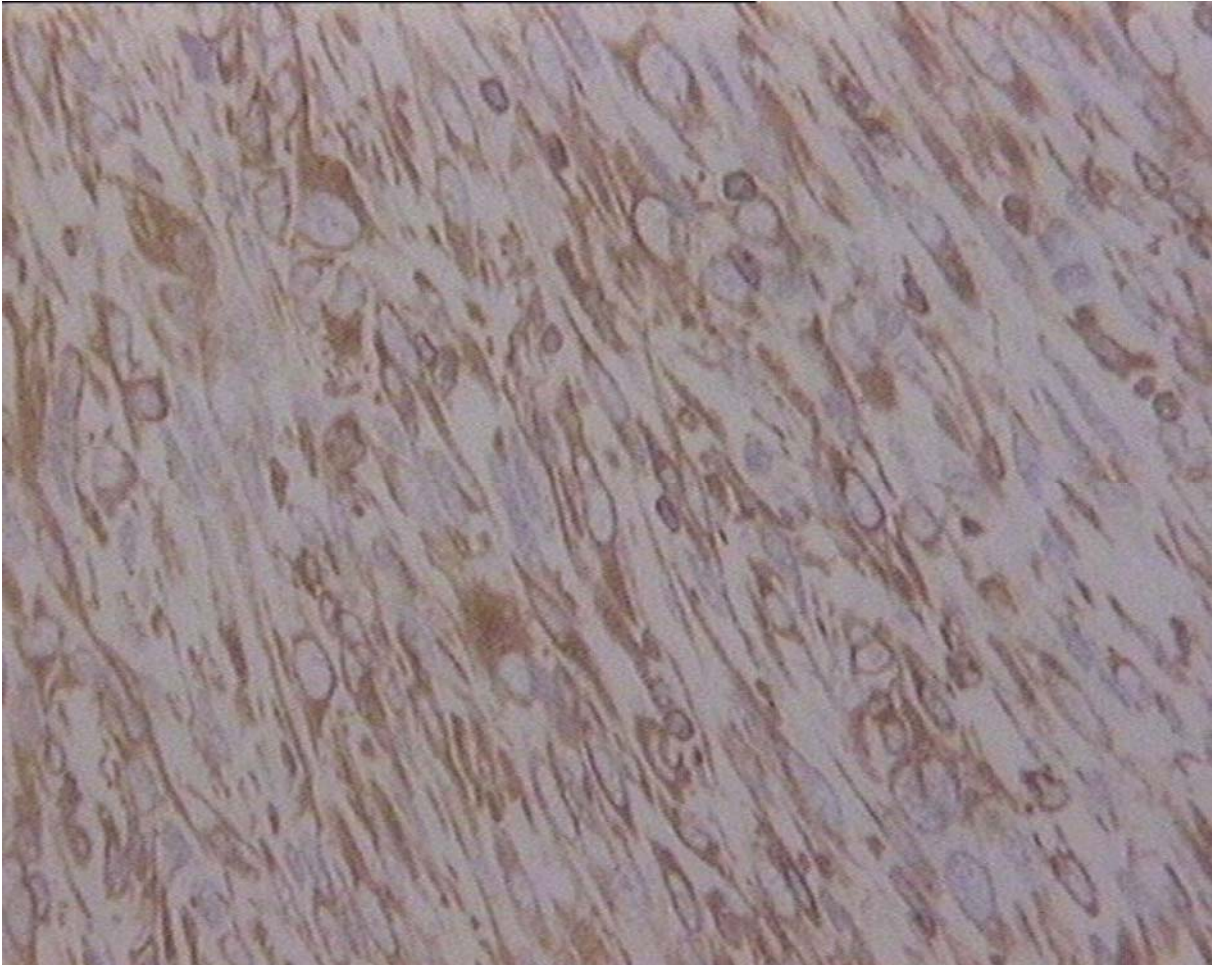
1. Butany J, Nair V, Naseemuddin A, et al. Cardiac tumors: diagnosis and management. *Lancet Oncol* 2005; 6:219-28.
2. Sarjeant JM, Butany J, Cusimano RJ. Cancer of the heart : epidemiology and management of primary neoplasms and metastases. *Am J Cardiovasc Drugs* 2003; 3:407-21.
3. Weiss SW, Enzinger FM. Malignant fibrous histiocytoma: an analysis of 200 cases. *Cancer* 1978; 41:2250-2266.
4. Okamoto K, Kato S, Katsuki S et al. Malignant fibrous histiocytoma of the heart: case report and review of 46 cases in the literature. *Internal Med* 2001; 40(12):1222-6.
5. Floyd JD, Nguyen DT, Lobins RL, et al. Cardiotoxicity of cancer therapy. *J Clin Oncol* 2005; 23:7685-96.
6. Gowdamarajan A, Michel RE. Therapy for primary cardiac neoplasms: is there a role for heart transplantation? *Curr Opin Cardiol* 2000; 15:121-25.
7. Shah AA, Chung A, Sbarbaro JA, et al. Malignant fibrous histiocytoma presenting as an atrial myxoma. *Cancer* 1978; 42:2466-71.
8. Gaya AM, Ashford RF. Cardiac complications of radiation therapy. *Clin Oncol* 2005; 17:153-9.
9. Spira AI, Ettinger DS. The use of chemotherapy in soft-tissue sarcomas. *Oncologist* 2002; 7:348-59.
10. Goldstein DJ, Oz MC, Rose EA, et al. Experience with heart transplantation for cardiac tumors. *J Heart Lung Transplant* 1995; 14:382-6.
11. Kostler WJ, Brodowicz T, Attems Y, et al. Docetaxel as rescue medication in anthracycline- and ifosfamide-resistant locally advanced or metastatic soft tissue sarcoma: results of a phase II trial. *Ann Oncol* 2001; 12:1281-88.
12. Hensley ML, Maki R, Venkatraman E, et al. Gemcitabine and docetaxel in patients with unresectable leiomyosarcoma: results of a phase II trial. *J Clin Oncol* 2002; 20:2824-31.

## Figure legends

**Figure 1.** Microscopic examination, MFH (HE stain, x200). Malignant fibrous histiocytoma revealing fascicles of plump spindle cells of varying size arranged in a swirling storiform pattern. Characteristic is the tendency for the spindle cells to be disposed in a cartwheel storiform pattern.

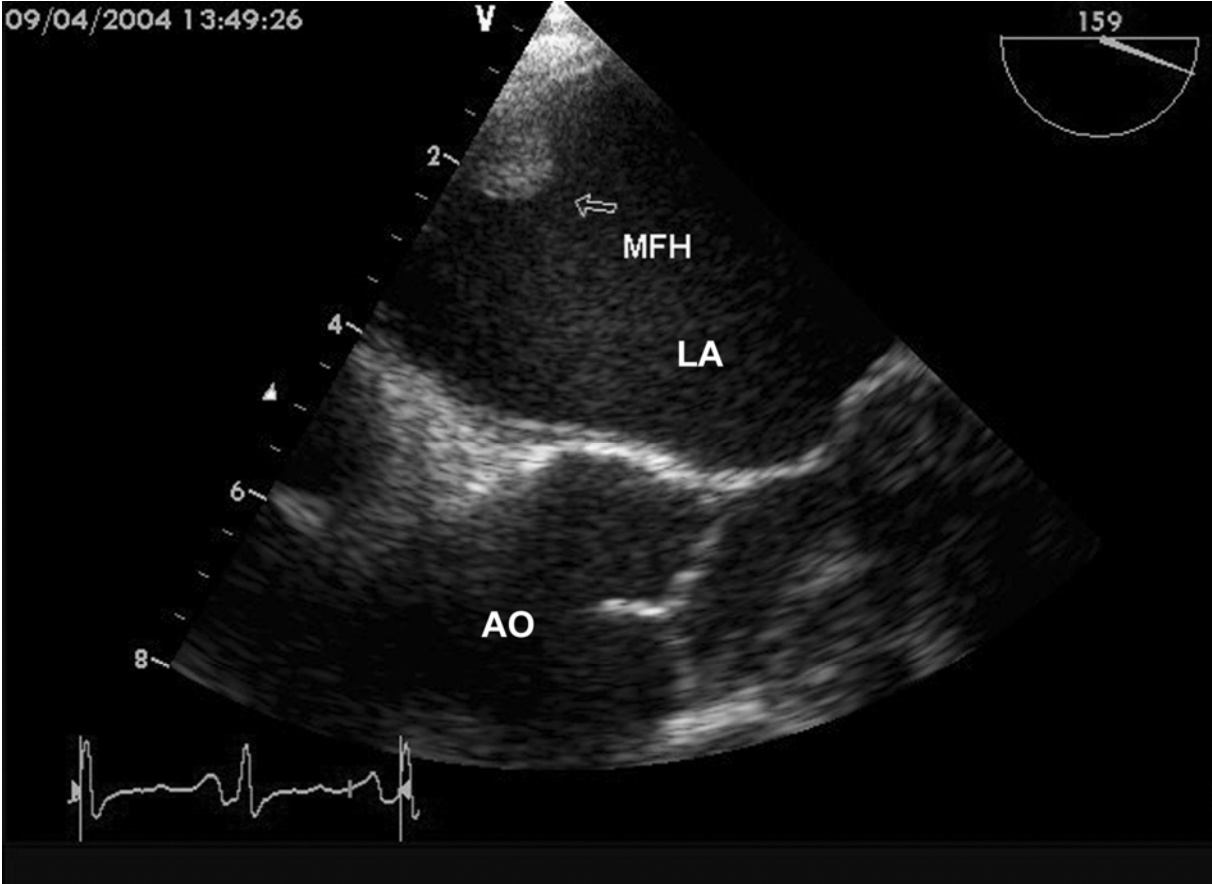


**Figure 2.** Immunohistochemical examination, MFH (vimentin stain, x200).



**Figure 3.** TEE demonstrates early postoperative MFH recidive in the top of the left atrium.

LA indicates left atrium; Ao, aorta; MFH, malignant fibrous histiocytoma



**Figure 4.** TTE (parasternal short axis) demonstrates MFH recidive that occupied more than a half the left atrium. LA indicates left atrium; RA, right atrium; RV, right ventricle; AO, aorta; MFH, malignant fibrous histiocytoma

