

# Images in emergency medicine. Elderly woman with abdominal pain. Secondary pneumatosis intestinalis

---

**Augustin, Goran**

*Source / Izvornik:* **Annals of Emergency Medicine, 2010, 55, 390 - 400**

**Journal article, Accepted version**

**Rad u časopisu, Završna verzija rukopisa prihvaćena za objavljivanje (postprint)**

<https://doi.org/10.1016/j.annemergmed.2009.06.502>

*Permanent link / Trajna poveznica:* <https://um.nsk.hr/um:nbn:hr:105:555667>

*Rights / Prava:* [In copyright](#) / [Zaštićeno autorskim pravom.](#)

*Download date / Datum preuzimanja:* **2024-11-23**



*Repository / Repozitorij:*

[Dr Med - University of Zagreb School of Medicine  
Digital Repository](#)





## Središnja medicinska knjižnica

**Augustin G. (2010) *Images in emergency medicine. Elderly woman with abdominal pain. Secondary pneumatosis intestinalis. Annals of Emergency Medicine, 55 (4). pp. 390, 400. ISSN 0196-0644***

<http://www.elsevier.com/locate/issn/01960644>

<http://www.sciencedirect.com/science/journal/01960644>

<http://dx.doi.org/10.1016/j.annemergmed.2009.06.502>

<http://medlib.mef.hr/752>

University of Zagreb Medical School Repository

<http://medlib.mef.hr/>

**Title page**

**Title:** Secondary pneumatosis intestinalis

Augustin G

**Goran Augustin, MD, MSc** (*corresponding author*)

University Hospital Center Zagreb

Department of Surgery, Division of gastrointestinal surgery

E-mail: [augustin.goran@gmail.com](mailto:augustin.goran@gmail.com)

**Keywords:** pneumatosis intestinalis, bowel obstruction, bowel ischemia

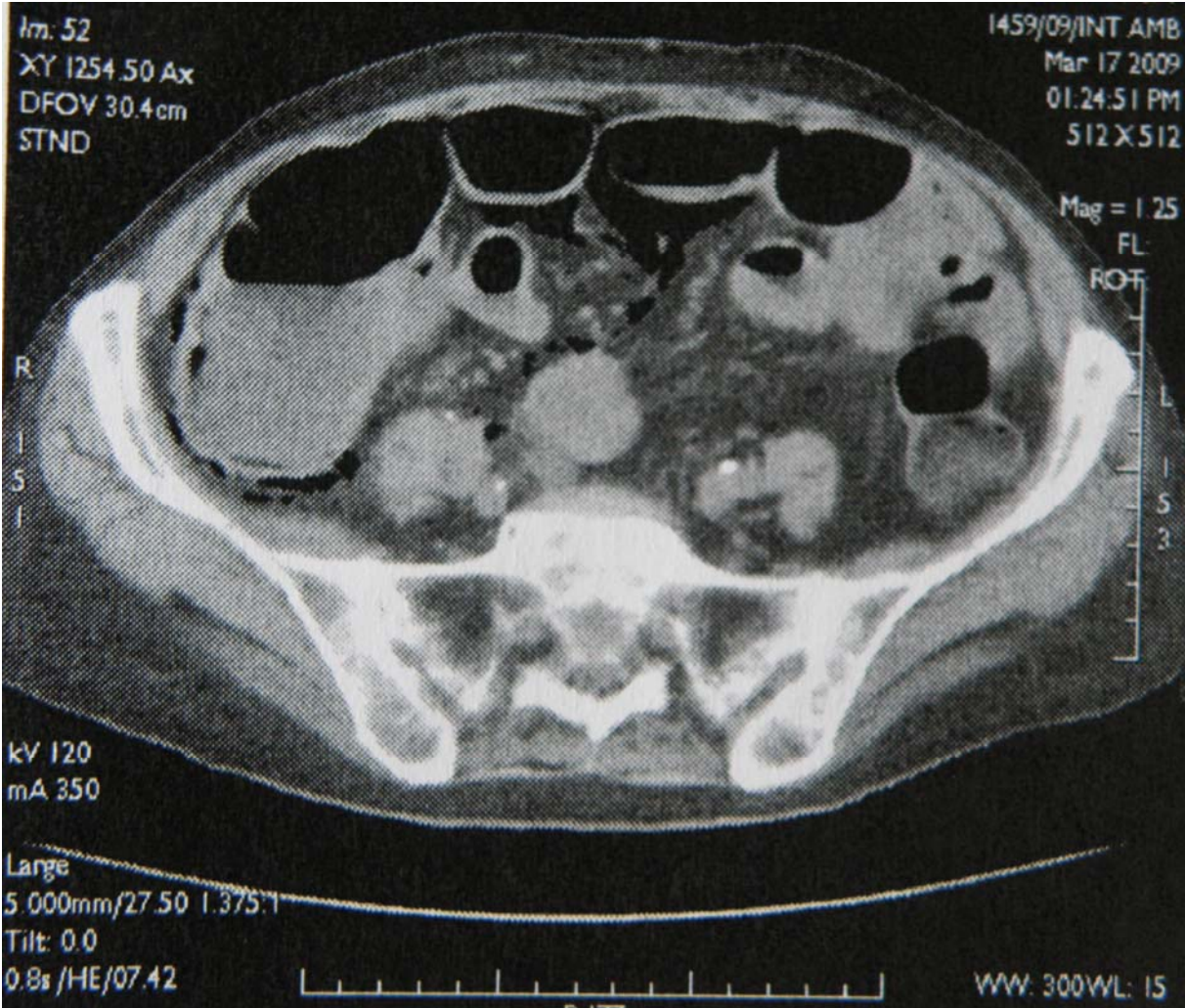
## Secondary pneumatosis intestinalis

A 87-year old woman presented with abdominal pain, chills and fever with 2-day history of vomiting and diarrhea without blood. She lost 5 kg during last 3 months. Plain abdominal X-ray showed dilated loops of small and large bowel and multislice CT delineated infiltrative and partially obstructive process of hepatic flexure of the colon with air in the bowel wall suggesting bowel ischemia (Panel A). Exploration confirmed preoperative findings of intestinal pneumatosis (Panel B) and infiltrative process of the colon with peritoneal carcinomatosis. Loop ileostomy was made but the patient died after 3 days.

Pneumatosis intestinalis (gas in the bowel wall) occurs in 2 forms. Primary pneumatosis intestinalis (15-20% of cases) is a benign idiopathic condition in which multiple thin-walled cysts develop in the submucosa or subserosa of the colon. Usually, this form has no associated symptoms, and the cysts may be found incidentally. This primary form is often termed pneumatosis cystoides intestinalis. The secondary form (80-85% of cases) is associated with gastrointestinal pathology including mesenteric ischemia, bowel obstruction, Crohn disease, and ulcerative colitis, variety of infectious etiologies, as well as obstructive pulmonary disease with high mortality especially if gas in the portaomesenteric venous system is present.

**Figure legends**

**Figure 1** Multislice CT scan showing presence of gas in the bowel wall of small and large intestine



**Figure 2** Intraoperative photograph showing gas in the junction of mesentery and small bowel wall

